



Aquatic animal diseases significant to Australia: identification field guide 5th edition

March 2019



© Commonwealth of Australia

Ownership of intellectual property rights

Unless otherwise noted, copyright (and any other intellectual property rights, if any) in this publication is owned by the Commonwealth of Australia (referred to as the Commonwealth).

Creative Commons licence

All material in this publication is licensed under a Creative [Commons Attribution 4.0 International Licence](https://creativecommons.org/licenses/by/4.0/) except content supplied by third parties, logos and the Commonwealth Coat of Arms.

Inquiries about the licence and any use of this document should be emailed to copyright@agriculture.gov.au.



Cataloguing data

This publication (and any material sourced from it) should be attributed as: Department of Agriculture 2019, *Aquatic Animal Diseases Significant to Australia: Identification Field Guide, 5th Edition*, Australian Government Department of Agriculture, Canberra. CC BY 4.0.

ISBN 978-1-76003-235-7

Internet

Aquatic Animal Diseases Significant to Australia: Identification Field Guide, 5th Edition is available at agriculture.gov.au/aadfieldguide

Inquiries regarding the licence and any use of this document should be sent to copyright@agriculture.gov.au.

The design concepts were developed and produced by Government Division, Australian Government Department of Agriculture, with scientific editing by DigsFish Services Pty Ltd.

Copies of the USB are available by contacting the Department of Agriculture Aquatic Animal Health Program.

Disclaimer

The Australian Government acting through the Department of Agriculture has exercised due care in the preparation and compilation of the information in this publication. Notwithstanding, the Department of Agriculture, its employees and advisers disclaim all liability, including liability for negligence, for any loss, damage, injury, expense or cost incurred by any person as a result of accessing, using or relying upon any of the information in this publication to the maximum extent permitted by law.

Foreword

The Australian Government Department of Agriculture is pleased to introduce the fifth edition of this field guide.

The field guide and its accompanying phone application aims to help people recognise diseases of significance to aquaculture and fisheries in Australia. This edition incorporates new and updated information gathered from an extensive review of the fourth edition. It now covers 53 aquatic animal diseases of significance to Australia that affect species of finfish, crustaceans, molluscs and amphibians.

Early recognition and reporting of suspected disease outbreaks is critical to protecting our unique aquatic biodiversity, and fisheries and aquaculture sectors. It can permit a rapid disease response to contain outbreaks, increasing the opportunity for disease eradication and thereby limiting potential impacts on aquatic animal industries and the environment. People who work closely with aquatic animals are usually the first to notice signs of a significant disease event. This field guide provides guidance for these people—aquaculture workers, commercial fishers, recreational fishers, quarantine staff, scientists, conservationists and students—to recognize significant aquatic animal diseases, should they occur.

Many people and institutions have contributed to the field guide, including fish health experts from industry, research organisations, state and territory governments, and government agencies of the Asia–Pacific region (including New Zealand), Canada, Denmark, Norway, the Netherlands, the United Kingdom and the United States of America.

Drawing extensively on experience and research activities in aquatic animal health management, both in Australia and abroad, the guide and its phone application complements the growing body of practical knowledge published for aquaculture and fisheries in Australia. On behalf of the Australian Government, I thank all contributors to this production for their efforts and commend this field guide to you.

Dr Mark Schipp

Australian Chief Veterinary Officer

Acknowledgements

The department would like to thank all contributors of new material to this fifth edition of the field guide, including Dr Craig Boys (NSW Department of Primary Industries), Dr James Brock (Aquatic Farms, Hawaii), Dr Ryan Carnegie (Virginia Institute of Marine Science), Dr Ben Diggles (DigsFish Services), Dr Ha Thanh Dong (King Mongkut's University of Technology, Thailand), Professor Tim Flegel (Mahidol University, Thailand), Dr Melinda Gabor and Dr Cheryl Jenkins (NSW Department of Primary Industries), Justin Graham (HuxburyQuinn), Dr Ian Jerrett (Agriculture Victoria Research), Professor Lester Khoo (Mississippi State University), Dr An Martel and Dr Frank Pasmans (Ghent University), Dr Juhasz Tamas (Budapest, Hungary), and Dr Trude Vrålstad (Norwegian Veterinary Institute).

The current publication has built upon the contributions made to previous editions of this guide and we recognise and thank all who have contributed information in the past, including Dr Rob Adlard (Queensland Museum), Dr Ellen Ariel and Dr Lee Berger (James Cook University), Dr Franck Berthe (IFREMER), Dr Rachel Bowater (Queensland Department of Primary Industries and Fisheries), Dr Susan Bower (Fisheries and Oceans Canada), Dr Tracey Bradley (Victorian Department of Primary Industries), Dr David Bruno (Marlab, Aberdeen, Scotland), Dr Nicky Buller (Department of Agriculture and Food, Western Australia), Dr Jeremy Carson (University of Tasmania), Dr Supranee Chinabut (Thailand Department of Fisheries), Dr Mark Crane (CSIRO Australian Animal Health Laboratory), Dr Melanie Crockford (Department of Agriculture and Food, Western Australia), Dr Marty Deveney (South Australian Research and Development Institute, South Australian Government), Dr Ben Diggles (DigsFish Services, Australia), Dr Ralph Elston (Aqua Technics Inc., United States of America), Dr Kevin Ellard and Dr Judith Handlinger (Tasmanian Department of Primary Industries, Parks, Water and Environment), Dr Susan Gibson-Keuh (Murdoch University), Dr Jeffrey Go (University of Sydney), Professor Larry Hanson (College of Veterinary Medicine, Mississippi State University), Dr Ron Hedrick (University of California, Davis), Dr Paul Hick (New South Wales Department of Primary Industries), Professor Brian Jones (Western Australia Department of Fisheries), Dr Michael Kent (Oregon State University), Dr Cedric Komar (Intervet Norbio Singapore), Dr Malcolm Lancaster (Primary Industries Research Victoria), Professor Bob Lester (University of Queensland), Professor Don Lightner (Arizona State University), Dr Tor Atle Mo (National Veterinary Institute, Oslo), Dr Nick Moody (CSIRO Australian Animal Health Laboratory), Dr James Moore (California Department of Fish and Game), Dr James Munro (University of Adelaide), Dr Kazuhiro Nakajima (Fisheries Research Agency, Japan), Dr Niels Jørgen Olesen (Danish Veterinary Institute), Dr Shane Raidal (Murdoch University), Dr Melba Reantaso (Food and Agriculture Organization of the United Nations), Dr AS Sahul Hameed (Abdul Hakeem College, India), Dr Glenn Schipp (Department of Resources—Fisheries, Northern Territory Government), Dr Lee Skerratt (James Cook University), Dr Fran Stephens (Murdoch University), Dr M Sano (National Research Institute of Aquaculture, Japan), Dr Michael Snow (Department of Fisheries, Western Australia), Dr David Stone (Centre for Environment, Fisheries and Aquaculture Science), Dr Peter Walker (CSIRO Australian Animal Health Laboratory), Professor Richard Whittington (University of Sydney), Dr Jim Winton (United States Geological Survey) and Dr Shi Zhengli (Chinese Academy of Sciences, People's Republic of China).

Members of the Australian Government Department of Agriculture—Aquatic Animal Health Program coordinated the production of this fifth edition including Dr Cian Foster-Thorpe and Dr Ingo Ernst. Alistair Herfort is recognised as co-ordinator of the first three editions of the field guide.

International photographic contributors

Dr David Alderman (Centre for Environment, Fisheries and Aquaculture Science, United Kingdom)

Dr Isabelle Arzul (French Research Institute for Exploration of the Sea—IFREMER)

Dr Jerri Bartholomew (Oregon State University)

Dr Susan Bower (Fisheries and Oceans Canada)

Dr Sandra Bravo (Universidad Austral de Chile)

Dr James Brock (Aquatic Farms, Hawaii)

Professor Eugene Burreson (retired—Virginia Institute of Marine Science)

Dr Ryan Carnegie (Virginia Institute of Marine Science)

Dr Ha Thanh Dong (King Mongkut's University of Technology, Thailand)

Dr Dianne Elliott (United States Geological Survey)

Professor Tim Flegel (Mahidol University, Thailand)

Dr John Fryer (deceased—Oregon State University)

Dr AS Sahul Hameed (Department of Zoology, C Abdul Hakeem College, Tamil Nadu, India)

Professor Larry Hanson (College of Veterinary Medicine, Mississippi State University)

Professor Tore Håstein (National Veterinary Institute, Oslo)

Dr Naoki Itoh (Tohoku University, Japan)

Dr Huang Jie (Yellow Sea Fisheries Institute, China)

Dr Brian Jones (retired—Western Australia Department of Fisheries)

Dr Erik Johnson (Private Practitioner, Johnson Veterinary Services, Georgia)

Dr Somkiat Kanchanakhan (Department of Fisheries, Thailand)

Professor Lester Khoo (College of Veterinary Medicine, Mississippi State University)

Dr Gael Kurath (United States Geological Survey)

Professor Don Lightner (retired—University of Arizona)

Dr An Martel (Ghent University)

Professor Tor Atle Mo (National Veterinary Institute, Oslo)

Dr James Moore (California Department of Fish and Game)

Dr Kazuhiro Nakajima (Fisheries Research Agency, Yokohama)

Dr Ronald Pascho (Western Fisheries Research Center, Seattle)

Dr Frank Pasmans (Ghent University)

Dr Trygve Poppe (Norwegian School of Veterinary Science, Oslo)

Dr Liang Qiu (Yellow Sea Fisheries Institute, China)

Dr Sarah Ridgeway (née Kleeman; formerly Australian Government Department of Agriculture)

Dr Hans Jürgen Schlotfeldt (European Association of Fish Pathologists)

Dr Juhasz Tamas (Budapest, Hungary)

Dr Trude Vrålstad (Norwegian Veterinary Institute)

Dr Jim Winton (United States Geological Survey)

Dr Oded Zmora (University of Maryland, Baltimore)

Australian photographic contributors

Dr Stella Bastianello (Gribbles Veterinary Pathology)

Dr Lee Berger (James Cook University)

Dr Rachel Bowater (Queensland Department of Primary Industries and Fisheries)

Dr Craig Boys (NSW Department of Primary Industries)

Dr Richard Callinan (formerly New South Wales Department of Primary Industries)

Dr Jeremy Carson (University of Tasmania)

Dr Ben Diggles (DigsFish Services)

Dr Kevin Ellard (Tasmanian Department of Primary Industries, Parks, Water and Environment)

Dr Melinda Gabor (NSW Department of Primary Industries)

Dr Jeffrey Go (University of Sydney)

Dr John Humphrey (retired—Northern Territory Department of Industry, Fisheries and Mines)

Dr Cheryl Jenkins (NSW Department of Primary Industries),

Dr Ian Jerrett (Agriculture Victoria Research)

Dr Clive Jones (Queensland Department of Primary Industries and Fisheries)

Dr Matt Landos (Future Fisheries Australia)

Professor Barry Munday (deceased—University of Tasmania)

Professor Leigh Owens (James Cook University)

Dr Mark Porter (University of Tasmania)

Dr Howard Prior (Queensland Department of Primary Industries and Fisheries)

K Scott

Dr Rick Speare (deceased—James Cook University)

Dr Greg Storie (Queensland Department of Primary Industries and Fisheries)

Dr Patrick Tully (New South Wales Department of Primary Industries)

Professor Richard Whittington (University of Sydney)

Staff at the CSIRO Australian Animal Health Laboratory

Staff at New South Wales Department of Primary Industries

Staff at The University of Sydney

Staff at Victorian Department of Primary Industries

Contents

Foreword	iii
Acknowledgements	iv
Introduction	1
Using the field guide	Error! Bookmark not defined.
Signs of disease.....	4
Host range	5
Presence in Australia	5
Epidemiology	6
Differential diagnosis.....	6
1. Anatomy	7
Finfish.....	7
Molluscs	10
Crustaceans	13
Amphibians	17
2. Diseases of finfish	19
Viral diseases of finfish	19
Channel catfish virus disease (CCVD).....	19
Epizootic haematopoietic necrosis (EHN).....	23
European catfish virus (ECV) and European sheatfish virus (ESV).....	27
Grouper iridoviral disease.....	31
Infection with HPR-deleted or HPRO infectious salmon anaemia virus (ISAV)	35
Infection with infectious spleen and kidney necrosis virus (ISKNV)-like viruses	40
Infection with salmonid alphavirus (SAV)	46
Infectious haematopoietic necrosis (IHN)	50
Infectious pancreatic necrosis (IPN)	55
Koi herpesvirus disease (KHVD)	59
Red sea bream iridoviral disease (RSIVD)	63
Spring viraemia of carp (SVC).....	68
Tilapia lake virus (TiLV) disease.....	72
Viral encephalopathy and retinopathy (VER)	77
Viral haemorrhagic septicaemia (VHS)	84
Bacterial diseases of finfish	92
Bacterial kidney disease (BKD).....	92
Enteric red mouth disease (ERMD).....	99

Enteric septicaemia of catfish	105
Furunculosis	112
Infection with <i>Aeromonas salmonicida</i> —atypical strains	118
Piscirickettsiosis	126
Parasitic diseases of finfish	131
Infection with <i>Gyrodactylus salaris</i>	131
Whirling disease.....	135
Other diseases of finfish	142
Infection with <i>Aphanomyces invadans</i>	142
3. Diseases of molluscs.....	148
Viral diseases of molluscs	148
Abalone viral ganglioneuritis (AVG).....	148
Infection with ostreid herpesvirus-1 microvariant (OshV-1 μ var)	154
Iridoviroses.....	159
Bacterial diseases of molluscs	162
Infection with <i>Xenohaliotis californiensis</i>	162
Parasitic diseases of molluscs	168
Infection with <i>Bonamia exitiosa</i>	168
Infection with <i>Bonamia ostreae</i>	174
Infection with <i>Bonamia</i> species.....	178
Infection with <i>Marteilia refringens</i>	182
Infection with <i>Marteilia sydneyi</i>	187
Infection with <i>Marteilioides chungmuensis</i>	199
Infection with <i>Mikrocytos mackini</i>	202
Infection with <i>Perkinsus marinus</i>	209
Infection with <i>Perkinsus olseni</i>	214
4. Diseases of crustaceans	221
Viral diseases of crustaceans	221
Infection with gill-associated virus (GAV)	221
Infection with infectious hypodermal and haematopoietic necrosis virus (IHHNV)	225
Infection with infectious myonecrosis virus (IMNV).....	235
Infection with <i>Macrobrachium rosenbergii</i> nodavirus (MrNV)	240
Infection with shrimp haemocyte iridescent virus (SHIV)	244
Infection with Taura syndrome virus (TSV).....	251
Infection with white spot syndrome virus (WSSV)	261
Infection with yellowhead virus genotype 1 (YHV1).....	272

Bacterial diseases of crustaceans	280
Acute hepatopancreatic necrosis disease (AHPND)	280
Infection with <i>Hepatobacter penaei</i>	286
Parasitic diseases of crustaceans.....	295
Infection with <i>Enterocytozoon hepatopenaei</i> (EHP)	295
Other diseases of crustaceans.....	300
Infection with <i>Aphanomyces astaci</i>	300
<i>Monodon</i> slow growth syndrome (MSGs).....	306
5. Diseases of amphibians	310
Viral diseases of amphibians	310
Infection with ranavirus	310
Other diseases of amphibians	316
Infection with <i>Batrachochytrium dendrobatidis</i> (Bd)	316
Infection with <i>Batrachochytrium salamandrivorans</i> (Bsal)	321
Appendix A: Scientific names	325
Appendix B: Reporting suspected disease	325
Appendix C: Further reading	340

Introduction

This field guide provides ready access to information on the aquatic animal diseases significant to Australia. These diseases have potential to disrupt Australia's aquatic animal biodiversity, fisheries and aquaculture productivity, and international trade.

The diseases covered here are in [Australia's national list of reportable diseases of aquatic animals](#), which includes those reportable through the regional Quarterly Aquatic Animal Disease reporting program (managed by the Network of Aquaculture Centres in Asia-Pacific, the Food and Agriculture Organization of the United Nations and World Organisation for Animal Health), as well as other diseases of national significance.

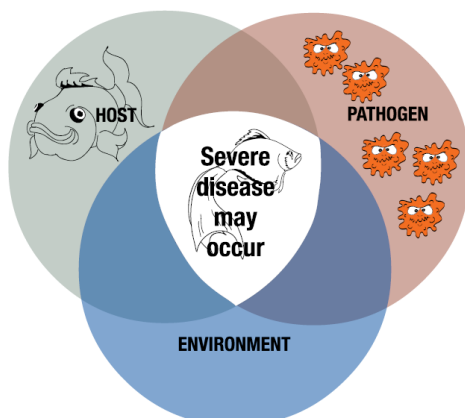
The field guide is aimed at fishery and aquaculture managers, their field staff, veterinary workers and students of aquatic animal health. The publication is also relevant to people in the seafood processing and retail industry, recreational and commercial fishers, and the general public. For people participating in national surveillance and monitoring for aquatic animal disease, the field guide is a valuable disease reference. For the casual reader, the field guide gives an informative and often graphic account of the diseases and organisms that threaten Australia's fisheries and expanding aquaculture industries.

The marine and freshwater environments in Australia are rich with many types of animals. The field guide focuses on fish, molluscs (such as oysters), crustaceans (such as prawns) and amphibians (such as frogs). It is not possible to list every disease for every species in a publication of this type. The emphasis is on infectious diseases found on Australia's National List of Reportable Diseases of Aquatic Animals, significant to our aquaculture industries, fisheries and environment.

Nature of disease

The diseases described in this field guide are caused by infectious agents—viruses, bacteria, fungi or parasites. Diseases with non-infectious causes are outside its scope. Non-infectious causes of disease in the aquatic environment are often attributable to the environment itself: morbidity and mortality can result from natural or human influenced events that lead to oxygen depletion, production of aquatic toxins, or changes in water temperature or salinity. However, disease will not occur simply because an infectious agent is present. The likelihood of disease being expressed is determined by the specific interactions between the host (the aquatic animal), the infectious agent or pathogen, and the environment (Figure 1).

Figure 1 Relationship between host, pathogen and the environment in disease outbreaks



Laboratory tests and sampling

Photographs of gross disease signs, such as those in this field guide, can help an investigator to create a preliminary list of possible disease agents (differential diagnosis list) for the case under investigation. However, although gross signs narrow the search for possible agents, they are not adequate for definitive diagnosis; representative samples from the diseased animal(s) and the environment in which they live need to be taken for analysis. Several publications offering information about sampling are available.

- The World Organisation for Animal Health (OIE) [Manual of diagnostic tests for aquatic animals](#) provides standard diagnostic methods for OIE-listed diseases.
- [Asia diagnostic guide to aquatic animal diseases](#) provides diagnostic guidelines for the pathogens and diseases listed in the Quarterly Aquatic Animal Disease Reporting System.
- The website of the Australian Government [Department of Agriculture](#) provides information on the management of inland water quality.

Reporting disease

Fishery and aquaculture industry managers, as well as farmers and their staff, should be aware of their responsibilities to rapidly report any suspicion of diseases on [Australia's national list of reportable diseases of aquatic animals](#) to local authorities.

To prepare for possible disease incursion, fishery and aquaculture industry managers should develop an emergency management plan, in consultation with farmers and appropriate extension staff.

If you identify signs of disease in a culture system, contact your aquatic animal health officer. If your observation is of wild aquatic animals, contact a wildlife or fisheries officer.

A national emergency animal disease watch hotline number has been established to assist early reporting of suspicious disease events. Call **1800 675 888** (free call and available 24 hours).

Current contact details for state and territory governments are provided in [appendix B](#). Call to report your find or ask further questions on the observations you have made. You will be directed to an expert on diseases of aquatic animals within your state or territory.

Follow the directions and advice provided by the officer you contact. This field guide will help you find the information the officer needs.

Using the field guide

This field guide begins with coverage of the anatomy ([section 1](#)) of finfish, molluscs, crustaceans and amphibians, including images and illustrations. These are to help the reader describe lesions when reporting a suspected disease. It follows with descriptions for each infectious disease present in [Australia's national list of reportable diseases of aquatic animals](#). These are presented alphabetically, and classified into infectious diseases affecting finfish, molluscs (such as oysters), crustaceans (such as prawns) and amphibians (such as frogs).

This field guide is available both as a PDF document and as a downloadable phone app. The field guide phone app (listed as the Aquatic disease field guide) can be downloaded free for iOS and android devices at the relevant iTunes or app store outlets. For more information, see the [Aquatic animal diseases significant to Australia: Identification field guide mobile application](#) introductory video.

In both the PDF document and phone app, each disease page describes the:

- signs of disease (at the farm/tank/pond level and gross and microscopic pathological signs)
- disease agent
- host species that carry the disease agent
- presence of the disease in Australia
- epidemiology of the disease
- other diseases in the field guide that may have similar signs
- sample collection and reporting of disease outbreaks.

The disease pages also include photographs of animals with gross signs of disease and/or histological images detailing the typical tissue changes present.

Diagnosing diseases of aquatic animals is a structured process, which begins with making detailed observations, then asking the right questions. The primary aim of this process is to create a broad list of possible diseases that may account for the observed signs. This list can be further refined by targeted questioning and diagnostic tests.

Questions to ask may include:

- Which species, age class, sizes and sex of animals are involved?
- What specifically have you observed—for example, behavioural changes, changes in feed intake (reduced or increased), changes in faecal output?
- Are there obvious gross lesions (such as colour changes, ulcers or spots)?
- Does disease result in morbidity only, or are there mortalities?
- What level of mortality has been observed?
- Do animals show signs of recovery?
- At what rate did you observe disease (sudden death or chronic progression of disease)?

- Is this the first occurrence of disease with this presentation in your facility?
- Are any neighbouring properties or facilities reporting diseases?
- Have there been recent introductions to the facility or any changes in practice?

After making your initial observations, go to the 'signs of disease' section of the disease entries. Look up the diseases listed that match your observations, and you will find photographs and further information to help you narrow the search for the cause of the disease. For example, you might have observed disease in a marine fish, but then find that the listed disease with similar presenting signs affects only freshwater species—in this way, you can eliminate the unlikely, and your list of differential diagnoses will be shorter. In all cases, however, laboratory tests would be required for a definitive diagnosis. Local authorities with responsibility for aquatic animal health can advise on further courses of action should you suspect any disease listed in the field guide.

Signs of disease

Diagnostic information based on disease signs at the farm, tank or pond level, and gross pathological signs (abnormalities that can be seen with the naked eye) are important. However, in most cases, it is impossible to arrive at a definitive diagnosis on the basis of these signs alone. Although some users will not have experience in histological examination, or the equipment required for such examination in the field, the field guide also lists microscopic pathological disease signs.

Mass mortality

A fish kill involving a range of species is more likely caused by an environmental problem, such as toxicity or oxygen depletion. Deaths limited to one species (where other species are also present) are more likely a result of an infectious agent.

Behavioural changes

All species of aquatic animals have characteristic protection, food-gathering and breeding behaviours. Abnormal behaviour, such as a decrease in feeding, could indicate stress from disease. Some behavioural changes can occur across groups of species, or even across different phyla. In molluscs, few behavioural differences are observed such as gaping or delayed closing (in oysters) and decreased feeding or adhesion to vertical surfaces (in abalone). Finfish often gather at water inlets or gasp for air at the surface if the water is depleted of oxygen. If irritated by skin parasites, they may scrape themselves on hard surfaces. Whirling or 'corkscrew' swimming could indicate disease from an infectious agent or aquatic toxins. In both finfish and crustaceans, gathering at the surface or pond edges can often be a sign of disease.

Gross signs

Gross pathological changes may indicate the presence of infectious disease. Careful observation and further laboratory investigation is required to make a definitive diagnosis because many of the signs are not singularly pathognomonic (characteristic for a specific disease) and may be common pathological changes associated with multiple infectious agents. The table below describes some of the more commonly observed visible signs and the groups of aquatic animals dealt with in this field guide for which these are most often observed.

Table 1 Potential gross signs of disease

Sign	Finfish	Molluscs	Crustaceans	Amphibians
Changes in the colour, texture and opacity of flesh	*	*	*	*
Tissue necrosis and lesions	*	*	*	*
Retraction of gill margins	na	*	na	na
Pustules	*	*	na	na
External spots	*	na	*	na
Changes in surface colour	*	na	*	*
Secondary fungal or bacterial growth	*	*	*	*
Deformities and tumours	*	na	*	*
Swollen or discoloured organs or faecal castes	*	*	*	*
White midgut line	na	na	*	na
Broken or damaged appendages	na	na	*	na
Erosion of shell	na	na	*	na
Lesions or ulcers on skin or gills	*	na	*	*
Haemorrhaging with associated anaemia	*	na	na	*
Granulomas	*	na	*	na
Exophthalmos (popeye)	*	na	na	na
Ascites (accumulation of fluid in peritoneal cavity)	*	na	na	*
Petechial haemorrhages (pinpoint bleeding in skin and mucous membranes)	*	na	na	*
Ecchymotic haemorrhages (bleeding or bruising beneath the skin or mucous membranes)	*	na	na	*
Excessive mucus on gills and skin	*	*	na	na
Dropsy (accumulation of fluid in body tissues)	*	na	na	*
Protrusion of scales	*	na	na	na

* Potential gross sign of disease. **na** Sign is not applicable to the taxonomic grouping.

Host range

A list of species known to be susceptible to the infectious agent is provided. Species are further classified as either naturally susceptible (diseased animals have been identified in the wild) or experimentally susceptible. Lists of susceptible species reflect the information available at the time of publishing. However, with further understanding and sampling, it is expected that such lists will expand and/or require refining. Both common and scientific names for hosts are provided.

Presence in Australia

Information on the national distribution of diseases listed in the field guide is based on formal reporting through the regional Quarterly Aquatic Animal Disease reporting program. This program is managed by the Network of Aquaculture Centres in Asia–Pacific (NACA), Food and Agriculture Organisations of the United Nations (FAO) and the World Organisation for Animal Health (OIE). Australia has been an active participant since 1998.

Where a listed disease has been reported under the program to have been present, a map illustrating where it occurred in Australia is included. States or territories having reported disease are listed, and shown in orange in the distribution map. It is important to note that, although a map may identify a state or territory as having reported a disease, this implies neither that it is present at the time of publication nor that it occurs across the entire state or territory.

Readers should consult the [World Animal Health Information Database \(WAHID\) interface](#) for current information on global distribution of diseases outside Australia.

Exotic diseases

Diseases in this field guide described as exotic are those that do not occur in Australian aquatic animal populations. Diseases present in Australia may still be listed as exotic if they are subject to an ongoing emergency disease response to contain and eradicate the disease.

Endemic diseases

Endemic (enzootic) diseases are those that have established in Australian aquatic animal populations. They might be native to Australia or might have been introduced in the past.

Epidemiology

The field guide describes epidemiological factors that are important to each disease. The key to describing the epidemiology of a disease involves understanding the relationship between the infectious agent, the host/s and the environment. Factors relating to the infectious agent include its life cycle (direct transmission or a requirement for intermediate host stages), survival outside the host (carriage on fomites, passage in wastewater) and sensitivity to certain temperatures or salinities.

Host factors may include the susceptible species, ages, sexes and sizes involved. Environmental factors include seasonal and non-seasonal variations in temperature, food availability, salinity, available oxygen, species movement and exposure to different environments (for example, migrations or gathering for breeding). These factors can affect disease agent survivability and host immune competence.

Differential diagnosis

The list of similar diseases at the bottom of each disease page refers only to the diseases covered by this field guide. Gross signs observed might well be representative of a wider range of diseases not included here. Therefore, these diagnostic aids should not be used as a guide to a definitive diagnosis, but rather as a tool to help identify the diseases included in this field guide that most closely account for the observed gross signs. Further diagnostic testing will be required to confirm either presence or freedom from a suspected disease.

1. Anatomy

Finfish

The external and internal anatomy of finfish varies considerably across species. Specific adaptations to predator–prey interactions, aquatic habitat variability and dietary preferences can explain these differences. One example is the short intestinal length of carnivorous fish compared with the relatively long intestine of herbivorous fish. Another, is the ventrally directed mouth of bottom-feeding species such as European carp (*Cyprinus carpio*) compared with the upward oriented mouth of the surface-feeding saratoga (*Scleropages leichardti*).

Figure 2 Mature male Atlantic salmon (*Salmo salar*)



Note: Typical hooked mouth.

Source: M Porter

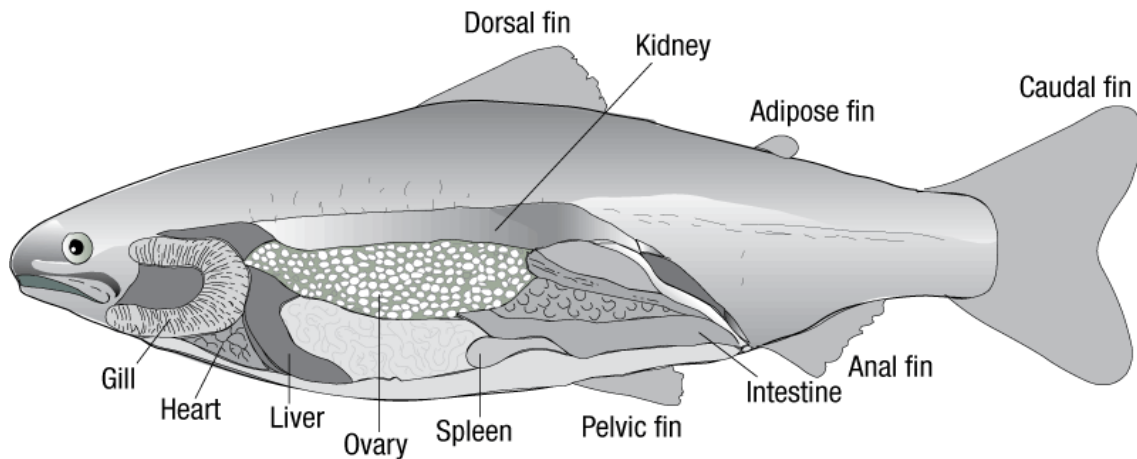
Figure 3 Gravid female Atlantic salmon (*Salmo salar*)



Note: Distended abdomen and protruding spawning vent.

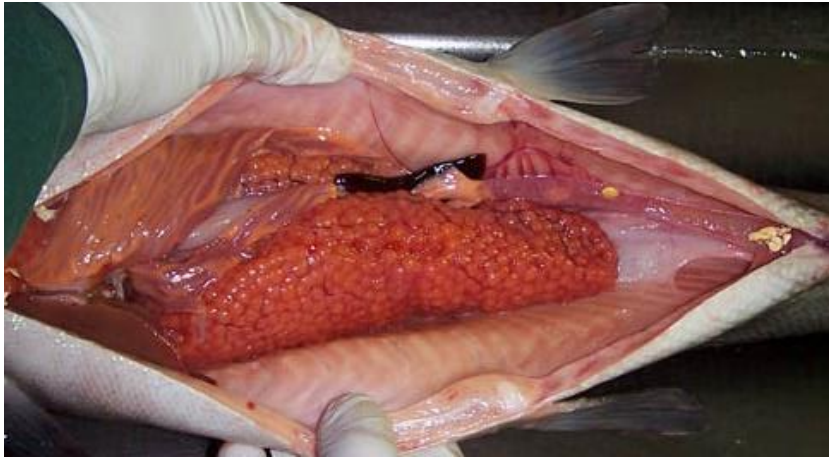Source: M Porter

Figure 4 Anatomy of female juvenile salmon



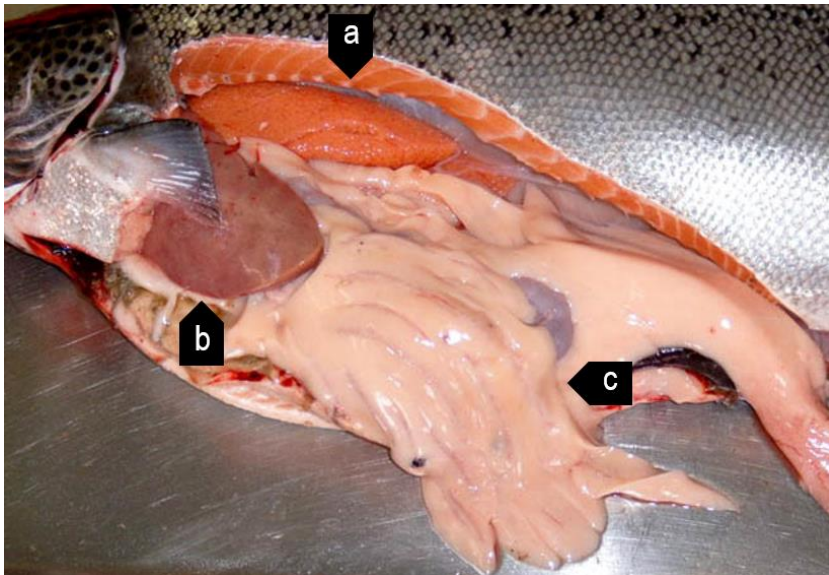
Source: Australian Government Department of Agriculture

Figure 5 Stomach cavity of gravid female Atlantic salmon (*Salmo salar*)



Note: Stomach cavity dominated by ovary. Compare the relative size of ovary with the rest of the internal organs.
Source: K Nelson

Figure 6 Internal organs of gravid female Atlantic salmon (*Salmo salar*)



Note: Ovary (a) is positioned between the liver (b) and intestines (c) and the vertebrae.
Source: M Porter

Figure 7 Degenerative eggs in old female Atlantic salmon (*Salmo salar*)



Source: M Porter

Figure 8 Golden perch (*Macquaria ambigua*)



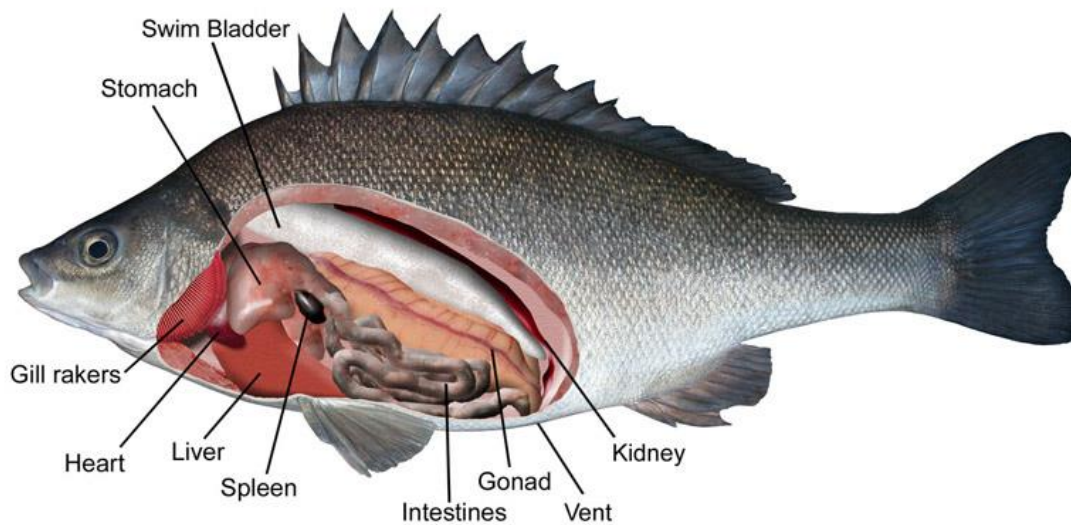
Note: Compare morphology to silver perch (*Bidyanus bidyanus*) in Figure 9
Source: New South Wales Department of Primary Industries

Figure 9 Silver perch (*Bidyanus bidyanus*)



Note: Compare morphology to golden perch (*Macquaria ambigua*) in Figure 8. Figure 9
Source: New South Wales Department of Primary Industries

Figure 10 Internal anatomy of silver perch (*Bidyanus bidyanus*)

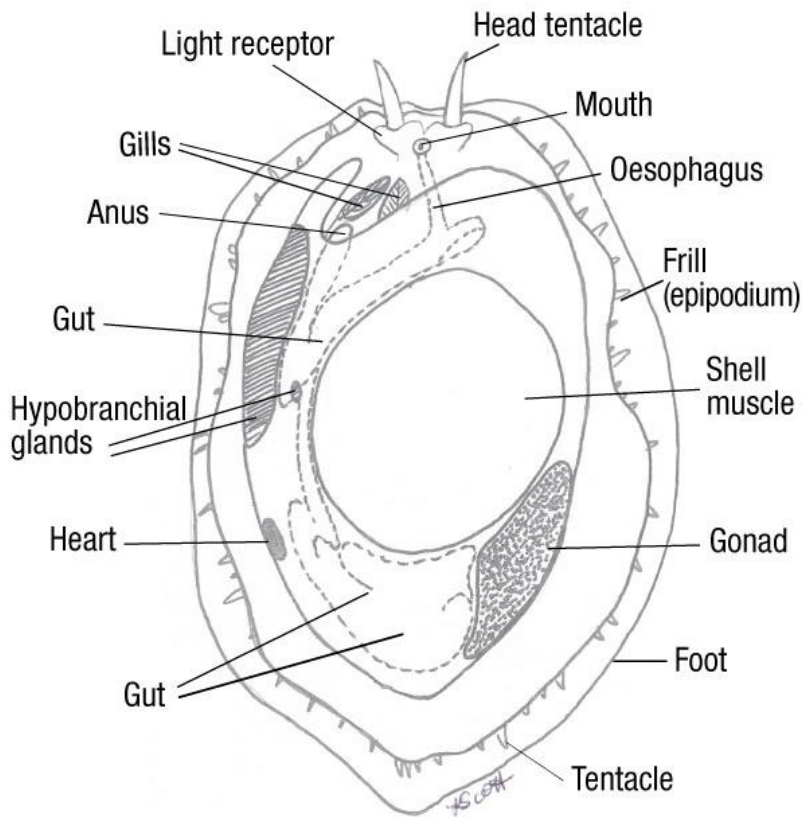


Source: New South Wales Department of Primary Industries

Molluscs

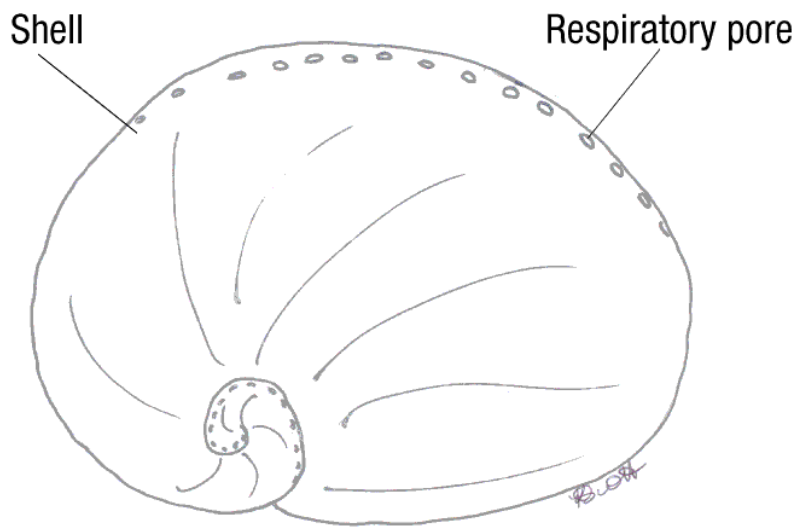
Abalone

Figure 11 Anatomy of abalone (*Haliotis* sp.)—ventral view



Source: K Scott

Figure 12 Anatomy of abalone (*Haliotis* sp.)—dorsal view



Source: K Scott

Figure 13 Abalone variations—ventral view

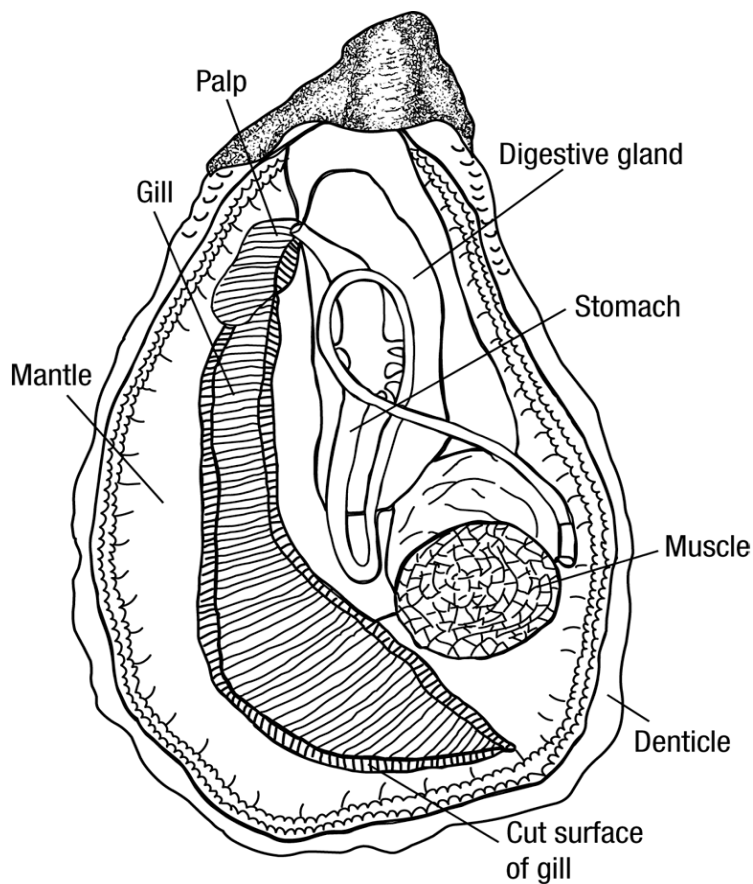


Note: Greenlip abalone, *Haliotis laevis* (left). Blacklip abalone, *Haliotis rubra* (top right). Hybrid tiger abalone, *Haliotis laevis* × *H. rubra* (bottom right).

Source: K Scott

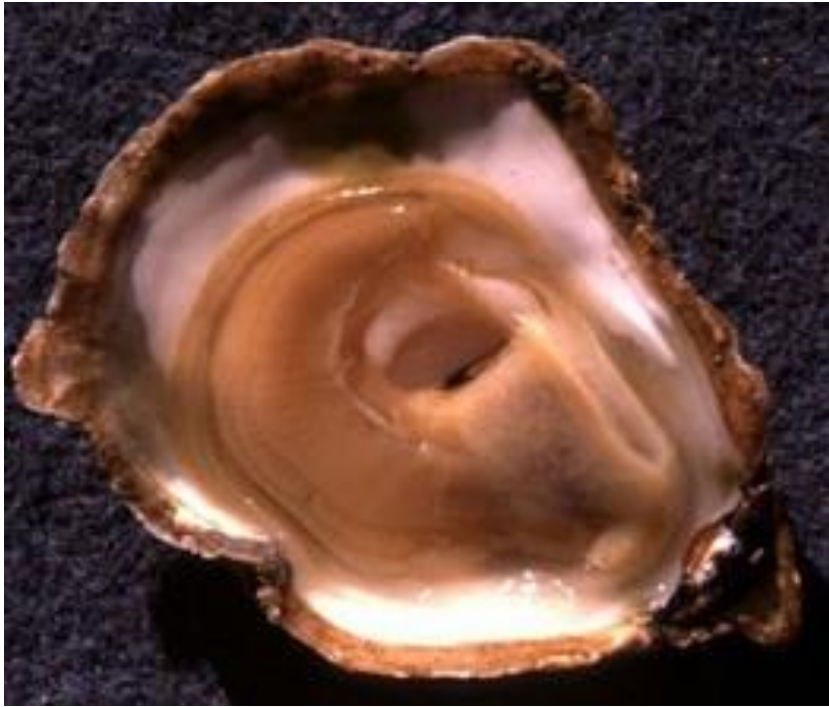Oysters

Figure 14 General anatomy of oyster (*Ostrea* sp.)



Source: Australian Government Department of Agriculture

Figure 15 Healthy European flat oyster (*Ostrea edulis*)



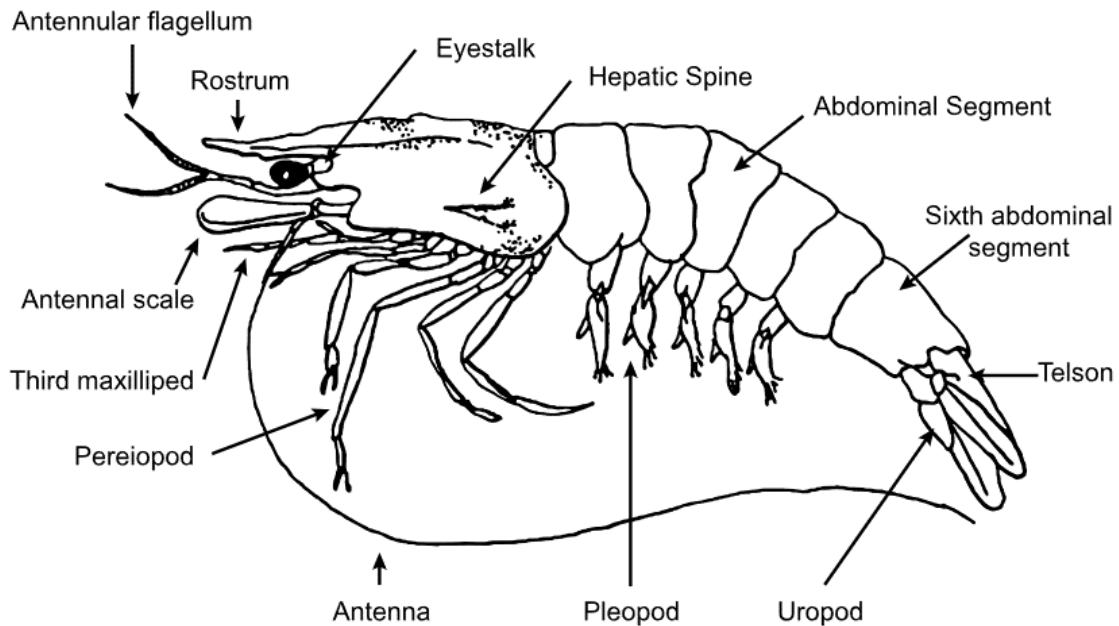
Source: I Arzul, French Research Institute for Exploration of the Sea

Crustaceans

Prawns

The common names 'prawn' and 'shrimp' are often used synonymously for the same crustaceans in different parts of the world. This field guide uses the terms most commonly used in Australia. Where Australian species of crustaceans are primarily involved in the disease, they are referred to as prawns. However, where the species of crustacean involved in the disease are exotic to Australia, they are referred to as shrimp.

Figure 16 External anatomy of prawn



Source: R Bowater, Queensland Department of Primary Industries and Fisheries

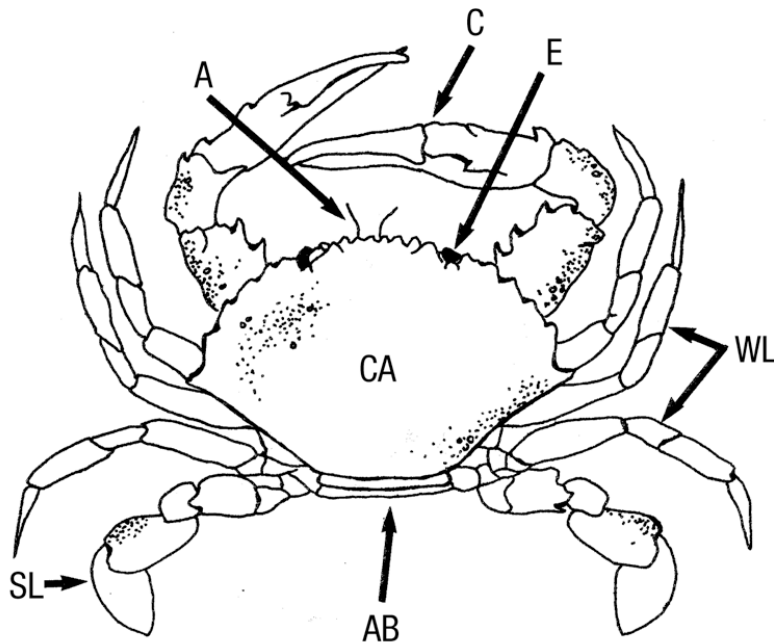
Figure 17 Black tiger prawn (*Penaeus monodon*)



Source: Australian Government Department of Agriculture

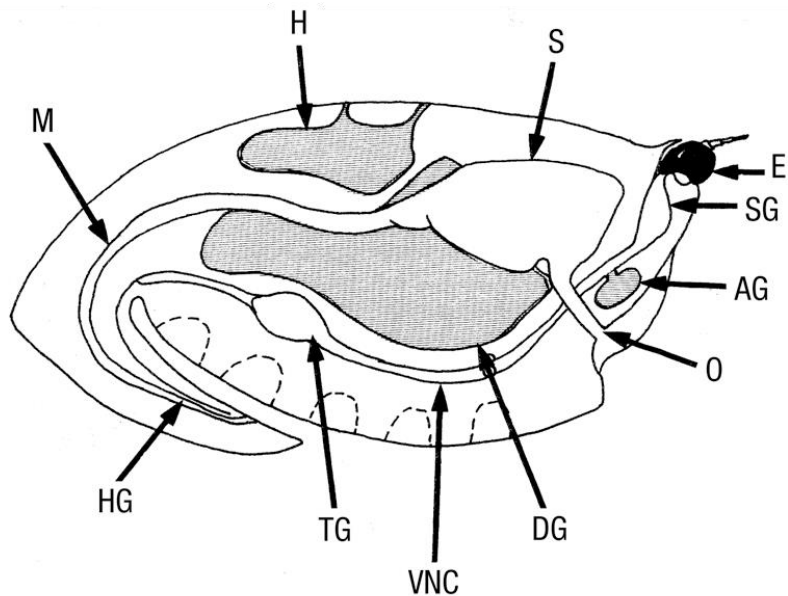
Crabs

Figure 18 External anatomy of crab



A antenna. **AB** abdomen (underneath). **C** claw. **CA** carapace. **E** eye. **SL** swimming leg. **WL** walking leg.
Source: R Bowater, Queensland, Department of Primary Industries and Fisheries

Figure 19 Internal anatomy of crab—sagittal section



AG antennal gland. **DG** digestive gland (hepatopancreas). **E** eye. **H** heart. **HG** hindgut. **M** midgut. **O** oesophagus. **S** stomach.
SG supraoesophageal ganglion. **TG** thoracic ganglion. **VNC** ventral nerve cord.
Source: R Bowater, Queensland Department of Primary Industries and Fisheries

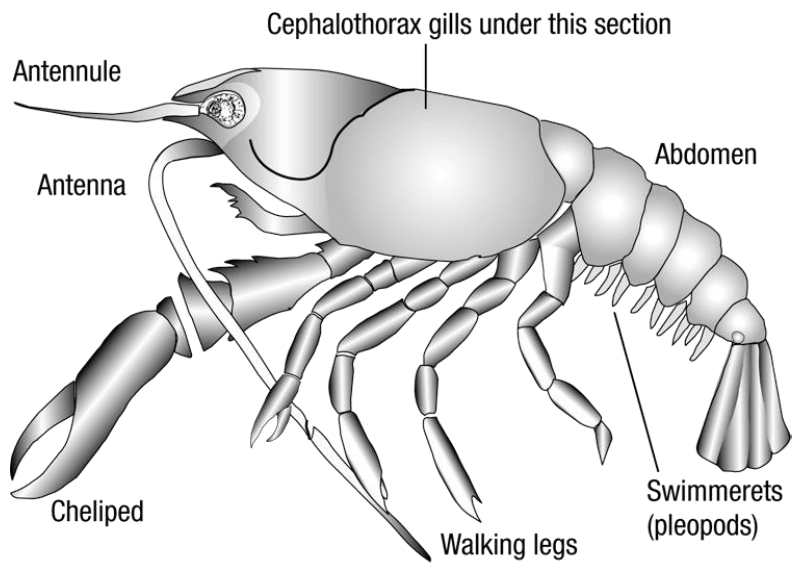
Figure 20 Internal anatomy of blue swimmer crab (*Callinectes sapidus*)



Source: O Zmora

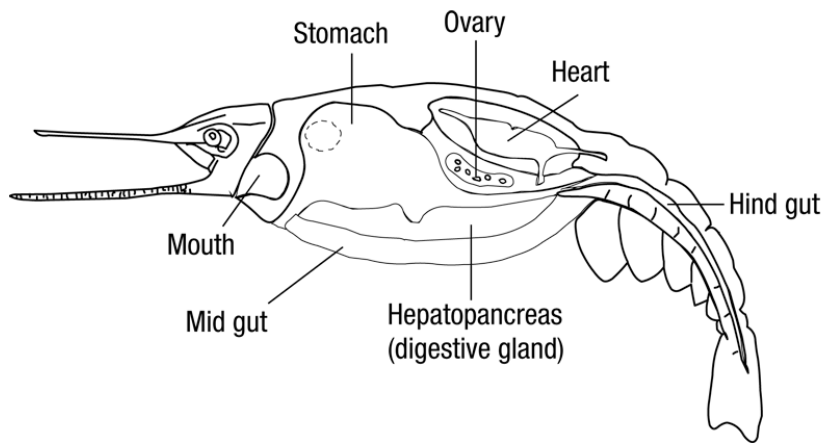
Crayfish

Figure 21 External anatomy of freshwater crayfish




Source: Australian Government Department of Agriculture

Figure 22 Internal anatomy of freshwater crayfish—sagittal section



Source: Australian Government Department of Agriculture

Figure 23 Redclaw crayfish (*Cherax quadricarinatus*)



Source: C Jones

Figure 24 Gills of redclaw crayfish (*Cherax quadricarinatus*)



Source: C Jones

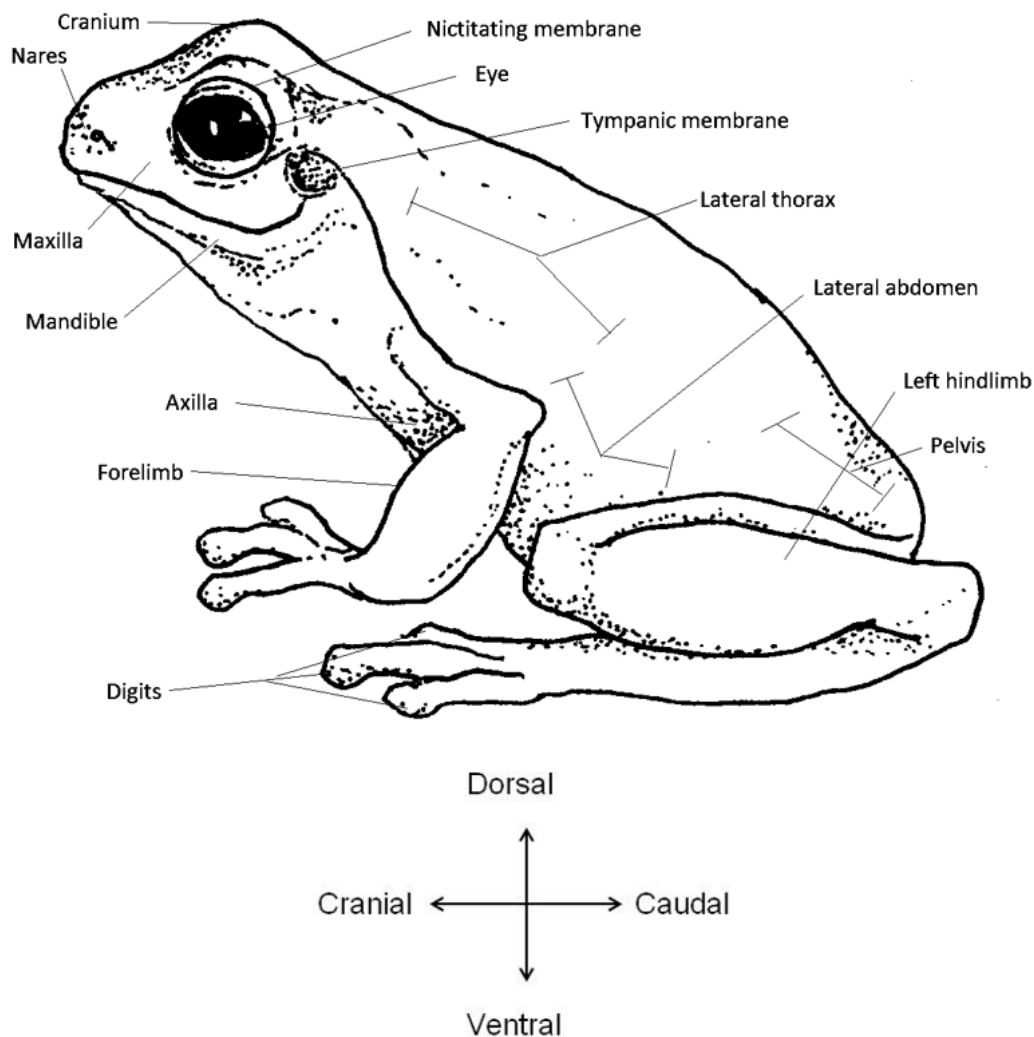
Amphibians

Amphibians are comprised of the orders Anura (frogs and toads), Caudata (including salamanders, newts and sirens) and Gymnophiona (caecilians). In Australia, we are primarily concerned with the health of anurans.

Amphibians undergo a metamorphosis that is unique among vertebrates; from a juvenile, obligatory aquatic form with gills (tadpoles) to a semi-aquatic adult form with lungs. Adult amphibians also have the unique ability to breathe transdermally (through the skin), meaning changes to the skin through disease, trauma or mishandling can have significant health impacts.

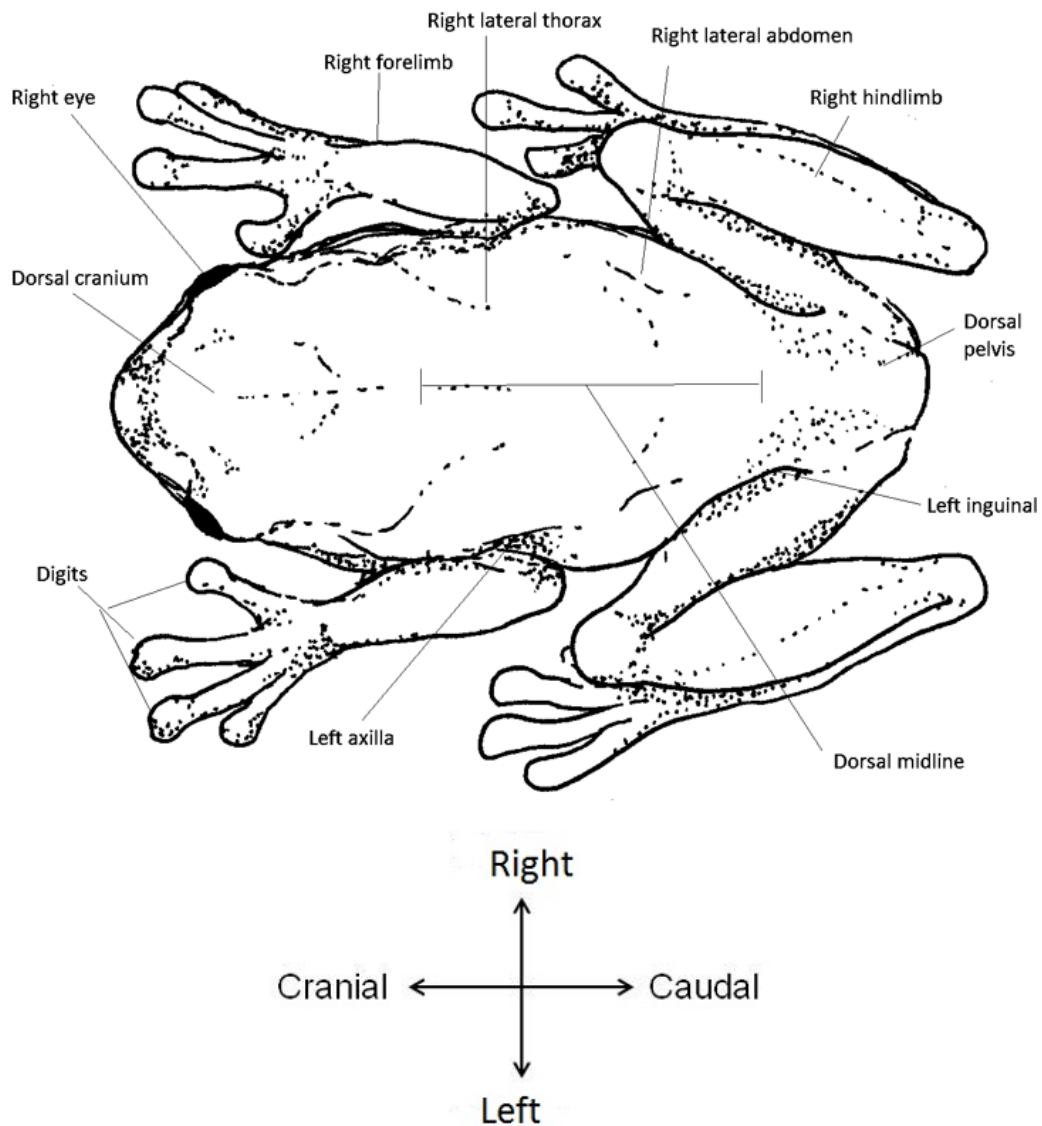
Early recognition and a deep understanding of the significant diseases affecting amphibians will be crucial to halting the current decline in species biodiversity seen in Australia. Although not of great commercial interest in Australia, native amphibians act as sentinels of change in aquatic environments. The anatomical descriptions in Figure 25 and Figure 26 are not exhaustive but are intended to help field guide users communicate the location and extent of gross external anatomical changes.

Figure 25 External anatomy of frog—left lateral view



Source: Australian Government Department of Agriculture

Figure 26 External anatomy of frog—dorsal view



Source: Australian Government Department of Agriculture

2. Diseases of finfish

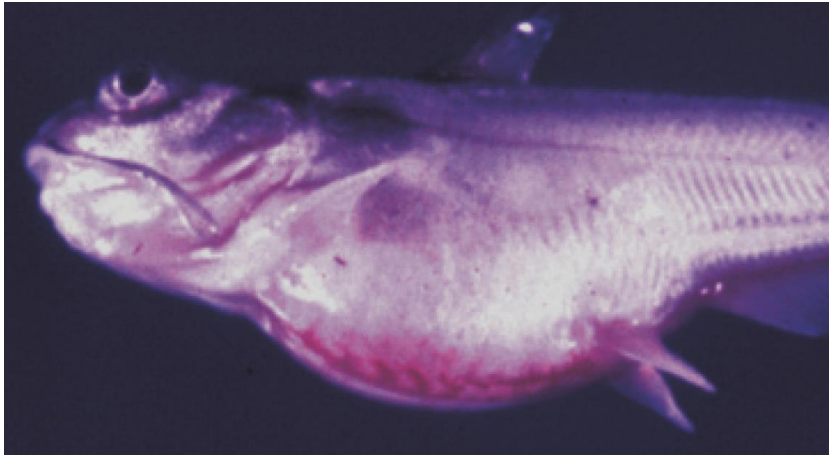
Viral diseases of finfish

Channel catfish virus disease (CCVD)

Also known as infection with Ictalurid herpesvirus 1

Exotic disease

Figure 27 Channel catfish (*Ictalurus punctatus*) fingerling showing signs of CCVD



Note: Swollen abdomen and popeye.

Source: LA Hanson

Figure 28 Channel catfish (*Ictalurus punctatus*) with CCVD



Note: Haemorrhages present on the base of the body, gills and fins.

Source: United States Department of Agriculture

Signs of disease

Important: Animals with this disease may show one or more of these signs, but the pathogen may still be present in the absence of any signs.

Disease signs at the farm, tank or pond level are:

- decreased feeding activity (usually the first sign of disease)
- high mortality in fry and juvenile catfish
- erratic swimming
- brief episodes of hyperactivity when fish are disturbed, followed by extended periods of lethargy
- large congregations of fish at the sides of hatching troughs or ponds, motionless in a head-up tail-down position.

Gross pathological signs are:

- swollen abdomen
- exophthalmos (popeye)
- haemorrhaging of fins and ventral abdomen
- haemorrhaging of the musculature, liver and kidneys
- dark and enlarged spleen
- fluid in the abdominal cavity
- pale, enlarged kidneys, which may be the only internal indication of disease in infected fish.

Microscopic pathological signs are:

- extensive necrosis of renal tubules and interstitial tissues of the kidney.

Disease agent

CCVD is caused by infection with Ictalurid herpesvirus 1, a double stranded DNA herpes virus classified within the genus *Ictalurivirus*, from the family *Alloherpesviridae*.

Host range

CCVD has been reported from blue catfish, channel catfish and channel catfish hybrids cultured in the USA, as well as *Pangasius* (Basa) catfish cultured in Asia. Ictalurid herpesvirus 1 has also been isolated from crucian carp (*Carassius carassius*) and common carp (*Cyprinus carpio*) not exhibiting disease signs. It is currently unknown if they act as reservoirs for the virus.

Table 2 Species known to be susceptible to CCVD

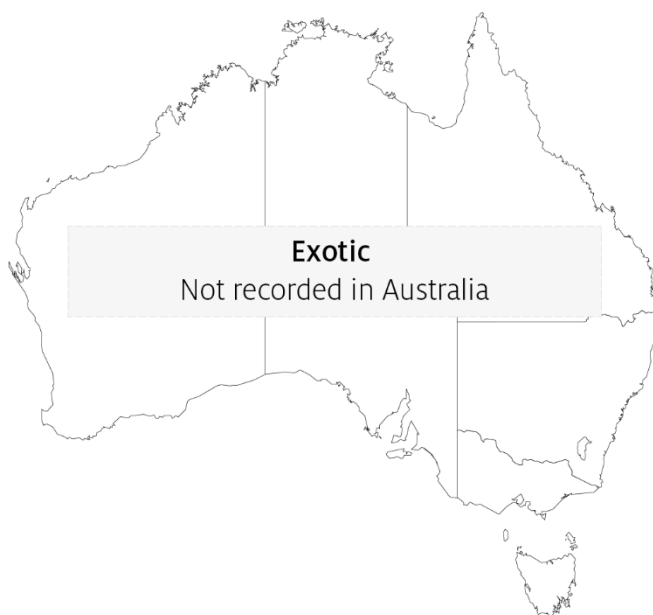Common name	Scientific name
Blue catfish ^a	<i>Ictalurus furcatus</i>
Channel catfish ^a	<i>Ictalurus punctatus</i>
Common carp and koi carp	<i>Cyprinus carpio</i>
Crucian carp	<i>Carassius carassius</i>
Striped catfish or Tra ^a	<i>Pangasianodon hypophthalmus</i>

^a Naturally susceptible. Note: Other species have been shown to be experimentally susceptible.

Presence in Australia

Exotic disease—not recorded in Australia.

Map 1 Presence of CCVD, by jurisdiction



Epidemiology

- Horizontal transmission occurs directly from virus shed in water, and from virus carried by animal vectors and on fomites.
- Vertical transmission (from parent to offspring via eggs) is believed to be common.
- Mortality rates in exposed fish can exceed 95%. Survivors of CCVD may experience short-term reductions in feed conversion (reduced weight gain). Generally, these fish appear normal but become carriers of the virus.
- Susceptibility appears to vary according to the strain of the virus.
- The disease occurs almost exclusively in fish that are less than 1 year old (fry and fingerlings) or smaller than 15cm in length. The majority of occurrences are in fish less than 4 months old.
- Mortality rates are highest where water temperature exceeds 27°C and declines with a reduction in temperature. Mortality rates are negligible at water temperatures lower than 18°C.

Differential diagnosis

The list of [similar diseases](#) in the next section refers only to the diseases covered by this field guide. Gross pathological signs may also be representative of diseases not included in this guide. Do not rely on gross signs to provide a definitive diagnosis. Use them as a tool to help identify the listed diseases that most closely account for the observed signs.

Similar diseases

Enteric septicaemia of catfish, European catfish virus (ECV) and European sheatfish virus (ESV), and infection with *Aeromonas salmonicida*—atypical strains.

Sample collection

Only trained personnel should collect samples. Using only gross pathological signs to differentiate between diseases is not reliable, and some aquatic animal disease agents pose a risk to humans. If you are not appropriately trained, phone your state or territory hotline number and report your observations. If you have to collect samples, the agency taking your call will advise you on the appropriate course of action. Local or district fisheries or veterinary authorities may also advise on sampling.

Emergency disease hotline

See something you think is this disease? Report it. Even if you're not sure.

Call the Emergency Animal Disease Watch Hotline on **1800 675 888**. They will refer you to the right state or territory agency.

Further reading

CABI Invasive Species Compendium [Channel catfish virus disease](#)


Camus, AC 2004, *Channel catfish virus disease*, Southern Regional Aquaculture Centre

CEFAS International Database on Aquatic Animal Diseases [Channel catfish virus disease](#)

Epizootic haematopoietic necrosis (EHN)

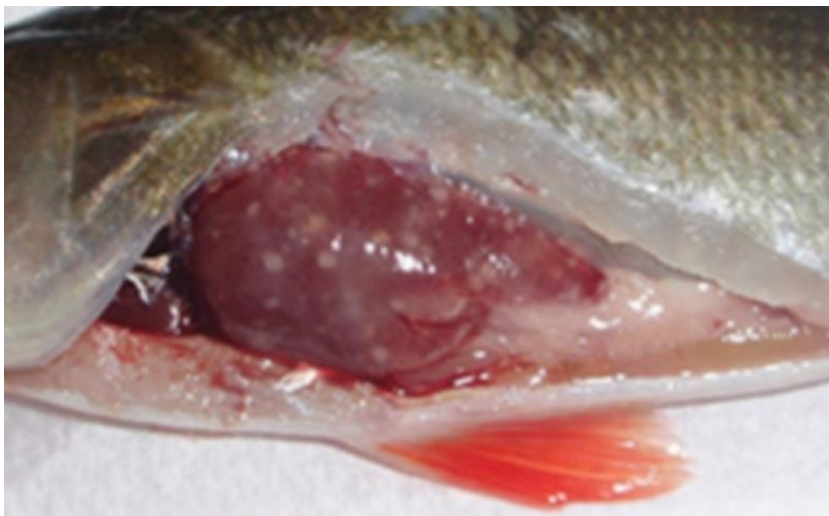Also known as infection with epizootic haematopoietic necrosis virus (EHNv)

Figure 29 Mass mortality of redfin perch (*Perca fluviatilis*) due to EHN



Note: Affected individuals showing signs of EHN including swollen abdomen (a) and small size.
Source: J Humphrey

Figure 30 Redfin perch (*Perca fluviatilis*) experimentally infected with EHNv



Note: Grossly visible multifocal necrotic foci in the liver.
Source: R Whittington

Signs of disease

Important: Animals with this disease may show one or more of these signs, but the pathogen may still be present in the absence of any signs.

Disease signs at the farm, tank or pond level are:

- hundreds or thousands of small (less than 10cm long), dead fish found on the downwind bank of the water body
- large numbers of fish-eating birds (such as seagulls) at the water surface

- loss of appetite
- juveniles (less than 25mm long) swimming in a disorientated fashion at the surface
- occasional adults affected when the disease first arrives in an area.

Gross pathological signs are:

- swollen abdomen
- darkened skin colour
- petechial (pinpoint) haemorrhages at the base of the fins
- haemorrhaging of the gills
- dead fish
- enlargement of the kidney, liver and spleen
- focal white to yellow liver lesions.

Microscopic pathological signs are:

- coagulative or liquefactive necrosis of the liver, kidney and spleen
- necrotic lesions in the heart, pancreas, gastrointestinal tract and gills
- small numbers of basophilic intracytoplasmic inclusion bodies surrounding necrotic areas of the liver and kidney.

Disease agent

EHN is caused by infection with epizootic haematopoietic necrosis virus (EHN_V), belonging to the genus *Ranavirus* within the family *Iridoviridae*. Closely related ranaviruses cause similar systemic necrotising iridovirus syndromes in sheatfish and catfish in Europe (European sheatfish virus and European catfish virus; also in this guide).

Host range

Table 3 Species known to be susceptible to EHN_V

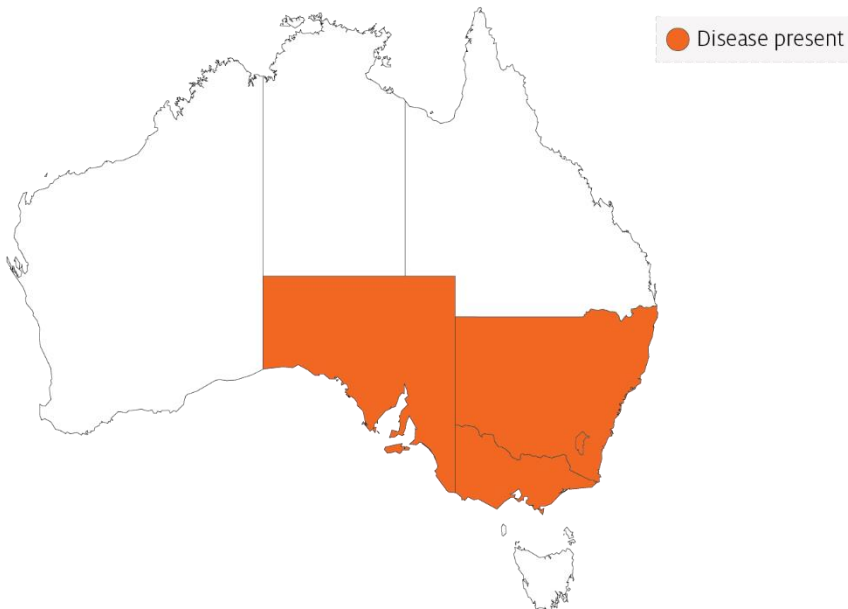Common name	Scientific name
Macquarie perch	<i>Macquaria australasica</i>
Mosquito fish	<i>Gambusia affinis</i>
Mountain galaxias	<i>Galaxias olidus</i>
Murray cod ^a	<i>Maccullochella peelii</i>
Rainbow trout ^b	<i>Oncorhynchus mykiss</i>
Redfin or European perch ^b	<i>Perca fluviatilis</i>
Silver perch	<i>Bidyanus bidyanus</i>
Piscivorous birds	Various genera and species

a Demonstrated to carry EHN_V subclinically. **b** Naturally susceptible. Note: Other species have been shown to be experimentally susceptible.

Presence in Australia

EHN has been officially reported from the Australian Capital Territory, New South Wales, South Australia and Victoria.

Map 2 Presence of EHN, by jurisdiction



Epidemiology

- EHN is usually seen in Australia as large kills of small redfin perch. High mortality can also occur among older perch in newly affected areas.
- Clinical outbreaks are typically seen in fingerlings and juvenile fish, associated with poor water quality and/or certain water temperatures (between 11°C and 17°C in rainbow trout and above 12°C in redfin perch).
- Mortalities occur over a short period (several weeks) in summer, and then the disease may disappear from an area for years.
- Low mortality rates over a period of months have been reported in young, farmed rainbow trout.
- Infectivity is less severe in rainbow trout than in redfin perch, with the disease mainly affecting fingerlings less than 125mm long.
- Low-grade mortalities with covert EHN infection can also occur in juvenile fish. Care must be taken when moving redfin perch and rainbow trout from the known geographical range of EHN to areas where it is exotic, unless freedom from disease can be adequately demonstrated.
- EHN is a resistant virus, surviving for months in water, persisting in frozen fish tissues for more than two years and in frozen fish carcasses for at least one year.
- EHN may be carried on equipment including nets and boats, in fish (live or dead) used for bait and via the gut, feathers, feet and bill of piscivorous birds.

Differential diagnosis

The list of [similar diseases](#) in the next section refers only to the diseases covered by this field guide. Gross pathological signs may also be representative of diseases not included in this guide. Do not rely on gross signs to provide a definitive diagnosis. Use them as a tool to help identify the listed diseases that most closely account for the observed signs.

Similar diseases

Enteric red mouth disease, furunculosis, infection with HPR-deleted or HPR0 infectious salmon anaemia virus, infectious haematopoietic necrosis (IHN), infectious pancreatic necrosis (IPN), viral haemorrhagic septicaemia (VHS) and whirling disease.

Sample collection

Only trained personnel should collect samples. Using only gross pathological signs to differentiate between diseases is not reliable, and some aquatic animal disease agents pose a risk to humans. If you are not appropriately trained, phone your state or territory hotline number and report your observations. If you have to collect samples, the agency taking your call will advise you on the appropriate course of action. Local or district fisheries or veterinary authorities may also advise on sampling.

Emergency disease hotline

See something you think is this disease? Report it. Even if you're not sure.

Call the Emergency Animal Disease Watch Hotline on **1800 675 888**. They will refer you to the right state or territory agency.

Further reading

CEFAS International Database on Aquatic Animal Diseases [Epizootic Haematopoietic Necrosis](#)

World Organisation for Animal Health [Manual of diagnostic tests for aquatic animals](#)

European catfish virus (ECV) and European sheatfish virus (ESV)

Exotic disease

Figure 31 Skin lesions on brown bullhead (*Ameiurus nebulosus*) with ECV infection



Note: Haemorrhagic skin lesions on the abdomen.

Source: J Tamás

Figure 32 Fin lesion on brown bullhead (*Ameiurus nebulosus*) with ECV infection



Note: Haemorrhagic skin lesions on the pelvic fin.

Source: J Tamás

Signs of disease

Important: Animals with this disease may show one or more of these signs, but the pathogen may still be present in the absence of any signs.

Disease signs at the farm, tank or pond level are:

- sudden high mortality rates (up to 100%) in juvenile fish in aquaculture or in the wild
- losses of up to 30% of adult sheatfish
- loss of appetite 1 to 2 days before mortalities occur

- erratic spiral swimming at the water surface
- lethargy.

Gross pathological signs are:

- swollen abdomen (ascites)
- darkened skin colour
- petechial (pinpoint) haemorrhages around the base of paired fins and in the viscera
- haemorrhagic areas on the skin
- pale gills
- many dead fish.

Microscopic pathological signs are:

- coagulative or liquefactive necrosis of the liver, spleen and especially the kidney
- destruction of haematopoietic tissues
- necrotic lesions in the heart, pancreas, gastrointestinal tract and gills.

Disease agent

ECV and ESV are classified as members of the genus *Ranavirus* within the family *Iridoviridae*. Other closely related ranaviruses such as epizootic haematopoietic necrosis virus (EHNV), grouper iridovirus (GIV) or *Ranavirus maxima* from European turbot cause similar systemic necrotising iridovirus syndromes in a range of fish species (EHNV and GIV are also in this guide).

Host range

ECV and ESV have been detected only in Europe. The pathogen has triggered epizootics in cultivated sheatfish in Germany and wild black bullheads in France, Italy and Hungary. Experimental ESV infection causes high mortality in pike, but black bullhead and rainbow trout appear to be unaffected, although viral replication has been detected. Juvenile pike perch may be susceptible to infection under certain conditions. These viruses may also be carried via the gut, feathers, feet and bill of piscivorous birds.

Table 4 Species known to be susceptible to ECV and ESV

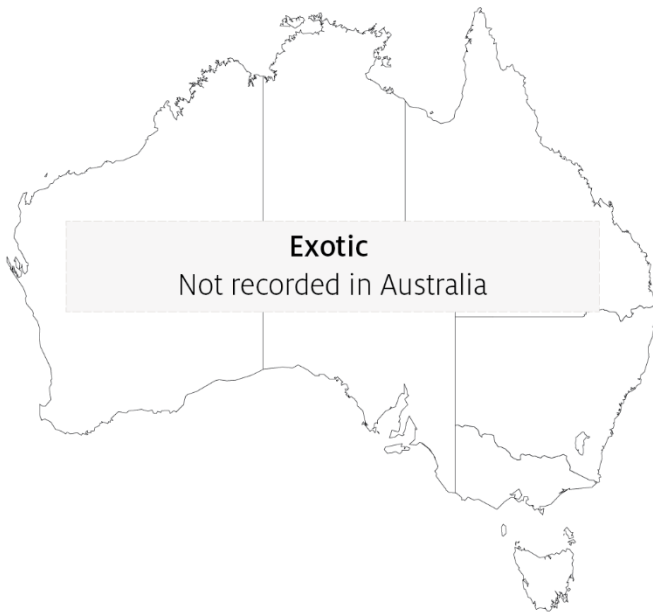Common name	Scientific name
Black bullhead or European catfish ^a	<i>Ameiurus melas</i>
Brown bullhead ^a	<i>Ameiurus nebulosus</i>
Pike	<i>Esox lucius</i>
Pike perch	<i>Sander lucioperca</i>
Rainbow trout	<i>Oncorhynchus mykiss</i>
Wels catfish or sheatfish ^a	<i>Silurus glanis</i>
Piscivorous birds	Various genera and species

^a Naturally susceptible. Note: Other species have been shown to be experimentally susceptible.

Presence in Australia

Exotic disease—not recorded in Australia.

Map 3 Presence of ECV and ESV, by jurisdiction



Epidemiology

- ESV was the first fish ranavirus to be isolated in Europe, when it was obtained from moribund sheatfish (*Silurus glanis*) fry experiencing 100% mortalities in Germany in 1989.
- Clinical outbreaks of sudden mass mortalities are typically seen in fingerlings and juvenile fish, though adult fish may also be affected.
- Transmission is horizontal and can occur by cohabitation resulting in up to 100% mortality within 11 days.
- Disease outbreaks may be associated with high summer water temperatures and/or poor water quality.
- Ranaviruses are resistant viruses, surviving for months in water, persisting in frozen fish tissues for more than two years and in fish carcasses for at least one year.
- Ranaviruses may be carried on equipment including nets and boats, in fish (live or dead) used for bait and via the gut, feathers, feet and bill of piscivorous birds.

Differential diagnosis

The list of [similar diseases](#) in the next section refers only to the diseases covered by this field guide. Gross pathological signs may also be representative of diseases not included in this guide. Do not rely on gross signs to provide a definitive diagnosis. Use them as a tool to help identify the listed diseases that most closely account for the observed signs.

Similar diseases

Channel catfish virus disease (CCVD), enteric septicaemia of catfish and epizootic haematopoietic necrosis (EHN).

Sample collection

Only trained personnel should collect samples. Using only gross pathological signs to differentiate between diseases is not reliable, and some aquatic animal disease agents pose a risk to humans. If you are not appropriately trained, phone your state or territory hotline number and report your observations. If you have to collect samples, the agency taking your call will advise you on the appropriate course of action. Local or district fisheries or veterinary authorities may also advise on sampling.

Emergency disease hotline

See something you think is this disease? Report it. Even if you're not sure.

Call the Emergency Animal Disease Watch Hotline on **1800 675 888**. They will refer you to the right state or territory agency.

Further reading

CABI Invasive Species Compendium [Isolation of ranavirus causing mass mortality in brown bullheads \(*Ameiurus nebulosus*\) in Hungary](#)

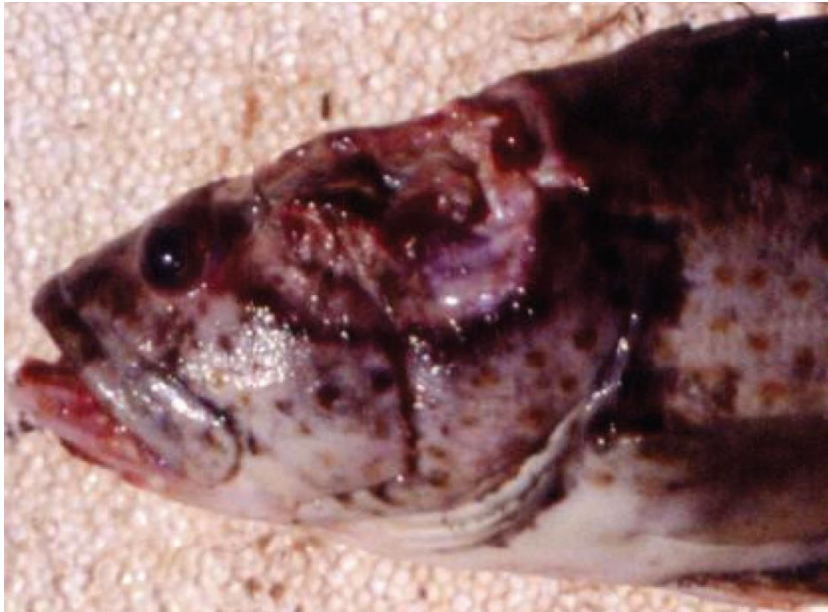World Organisation for Animal Health [Manual of diagnostic tests for aquatic animals](#)

Grouper iridoviral disease

Also known as sleepy grouper disease, grouper iridovirus of Taiwan (TGIV) and Singapore grouper iridovirus (SGIV)

Exotic disease

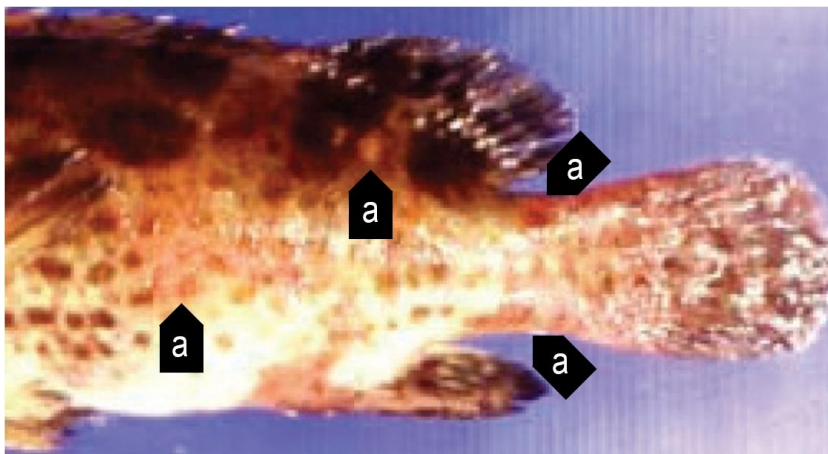
Figure 33 Gross signs of secondary infection in estuary cod (*Epinephelus tauvina*) infected by grouper iridovirus



Note: Deep ulceration in muscular tissue of the head.

Source: S Kanchanakhan

Figure 34 Gross signs of secondary infection in estuary cod (*Epinephelus tauvina*) infected by grouper iridovirus



Note: Haemorrhagic red boils (a) on the body surface.

Source: S Kanchanakhan

Signs of disease

Important: Animals with this disease may show one or more of these signs, but the pathogen may still be present in the absence of any signs.

Disease signs at the farm, tank or pond level are:

- typically high mortalities, with many dead and moribund fish
- high mortality of young grouper
- loss of appetite
- lethargic swimming
- rapid opercular movements and dashing to the surface for air (in the terminal phase).

Gross pathological signs are:

- darkened body colour, pale gills and enlarged spleen
- signs of secondary infection such as deep ulceration or papular lesions.

Microscopic pathological signs are:

- necrosis of the splenic pulp, and myocardium
- necrosis and reduction of haematopoietic tissue of the kidney in the absence of marked cell hypertrophy.

Disease agent

Grouper iridovirus disease is caused by infection with grouper iridovirus (GIV), belonging to the genus *Ranavirus* within the family *Iridoviridae*. Synonyms include grouper iridovirus of Taiwan (TGIV) and Singapore grouper iridovirus (SGIV).

Host range

Table 5 Species known to be naturally susceptible to GIV

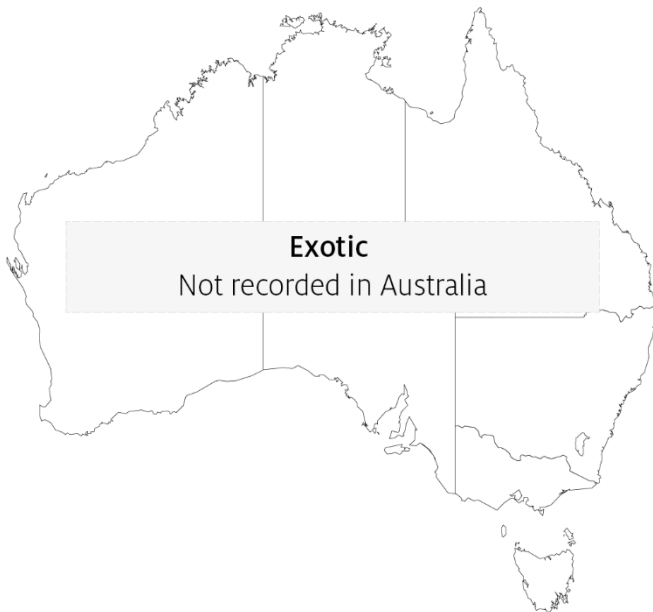Common name	Scientific name
Brown marbled grouper	<i>Epinephelus fuscoguttatus</i>
Coral trout	<i>Plectropomus leopardus</i>
Estuary cod	<i>Epinephelus tauvina</i>
Giant grouper	<i>Epinephelus lanceolatus</i>
Grouper and estuary cod	<i>Epinephelus</i> spp.
Malabar grouper	<i>Epinephelus malabaricus</i>
Spotted coral grouper	<i>Plectropomus maculatus</i>
Tiger grouper hybrid	<i>Epinephelus fuscoguttatus</i> × <i>E. lanceolatus</i>
Yellow grouper	<i>Epinephelus awoara</i>

Note: Other species have been shown to be experimentally susceptible.

Presence in Australia

Exotic disease—not recorded in Australia.

Map 4 Presence of grouper iridoviral disease, by jurisdiction



Epidemiology

- Grouper iridoviral disease causes losses in fry and juvenile grouper, and in 1 to 2-year-old market-sized grouper (a highly priced product in tropical mariculture).
- Clinical disease and highest mortalities are usually seen in 3 to 4-month-old fish after stocking into sea cages.
- Older diseased fish typically appear lethargic due to anaemia.
- Horizontal contact and waterborne transmission appear to be the principal mechanisms for virus spread.

Differential diagnosis

The list of [similar diseases](#) in the next section refers only to the diseases covered by this field guide. Gross pathological signs may also be representative of diseases not included in this guide. Do not rely on gross signs to provide a definitive diagnosis. Use them as a tool to help identify the listed diseases that most closely account for the observed signs.

Similar diseases

Infection with *Aphanomyces invadans* (EUS), infection with infectious spleen and kidney necrosis virus (ISKNV)-like viruses, red sea bream iridoviral disease (RSIVD) and viral encephalopathy and retinopathy (VER).

Sample collection

Only trained personnel should collect samples. Using only gross pathological signs to differentiate between diseases is not reliable, and some aquatic animal disease agents pose a risk to humans. If you are not appropriately trained, phone your state or territory hotline number and report your observations. If you have to collect samples, the agency taking your call will advise you on the appropriate course of action. Local or district fisheries or veterinary authorities may also advise on sampling.

Emergency disease hotline

See something you think is this disease? Report it. Even if you're not sure.

Call the Emergency Animal Disease Watch Hotline on **1800 675 888**. They will refer you to the right state or territory agency.

Further reading

Hazeri M, Hassan MD, Abba Y, Omar AR, Allaudin ZN, Soltani M, Hamdan RH, Mohamad NF 2017, [Molecular characterisation of grouper iridovirus isolates from Peninsular Malaysia](#), *Journal Veterinar Malaysia*

Ma H, Peng C, Su Y, Feng J, Guo Z 2016, 'Isolation of a Ranavirus-type grouper iridovirus in mainland China and comparison of its pathogenicity with that of a Megalocytivirus-type grouper iridovirus', *Aquaculture*

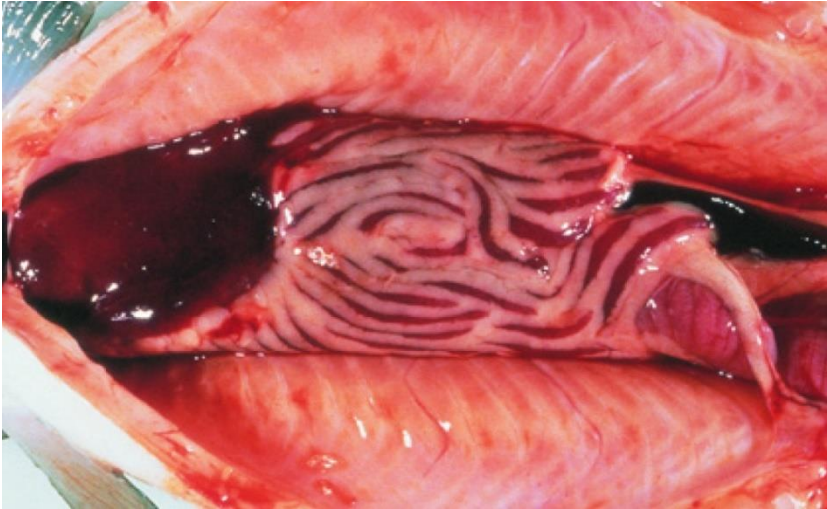
Network of Aquaculture Centres in Asia–Pacific [Grouper iridoviral disease: Disease card](#)

Infection with HPR-deleted or HPR0 infectious salmon anaemia virus (ISAV)

Also known as infectious salmon anaemia (ISA)

Exotic disease

Figure 35 Atlantic salmon (*Salmo salar*) with ISA



Note: Gross internal signs of ISA include dark liver, ascites and enlarged spleen.

Source: T Poppe

Signs of disease

Important: Animals with this disease may show one or more of these signs, but the pathogen may still be present in the absence of any signs.

Disease signs at the farm, tank or pond level are:

- mortality rate up to 100%
- fish congregating near the surface
- fish gasping at the surface
- lethargy
- loss of appetite.

Gross pathological signs are:

- pale gills and heart
- swollen abdomen
- exophthalmos (popeye), bleeding eyes
- fin rot
- ecchymotic (bruise-like) skin haemorrhages
- scale-pocket oedema
- swollen and dark liver, kidney and spleen (early sign); liver may be almost black

- petechial (pinpoint) haemorrhages in internal fat, peritoneum and skeletal muscle
- dark red intestinal wall mucosa
- ascites (fluid in the abdominal cavity)
- surface haemorrhages on liver.

Microscopic pathological signs are:

- renal interstitial haemorrhage and tubular necrosis
- branchial lamellar and filamental congestion
- congestion of the intestine and pyloric caecae
- perivascular inflammation and focal necrosis in liver.

Disease agent

ISA is caused by infection with the pathogenic highly polymorphic region (HPR)-deleted infectious salmon anaemia virus (ISAV), or the non-pathogenic HPRO (non-deleted HPR) ISAV, a single stranded RNA virus classified within the genus *Isavirus* within the family *Orthomyxoviridae*. Infection with HPR-deleted ISAV may cause severe disease in Atlantic salmon (*Salmo salar*). However, Detection of HPRO ISAV has never been associated with clinical signs of disease in Atlantic salmon.

Host range

The only species known to display clinical signs of ISA is the Atlantic salmon (*Salmo salar*). Several other fish species have been confirmed to be asymptomatic carriers of the virus.

Table 6 Species known to display clinical signs of ISA

Common name	Scientific name
Atlantic salmon	<i>Salmo salar</i>

Table 7 Species known to be asymptomatic carriers or vectors of ISAV

Common name	Scientific name
Arctic char	<i>Salvelinus alpinus</i>
Atlantic cod	<i>Gadus morhua</i>
Atlantic herring	<i>Clupea harengus</i>
Brown trout ^a	<i>Salmo trutta</i>
Coalfish or pollock	<i>Pollachius virens</i>
Coho salmon ^a	<i>Oncorhynchus kisutch</i>
Masu salmon ^a	<i>Oncorhynchus masou</i>
Rainbow trout ^a	<i>Oncorhynchus mykiss</i>
Salmon louse	<i>Lepeophtheirus salmonis</i> and <i>Caligus coryphaenae</i>

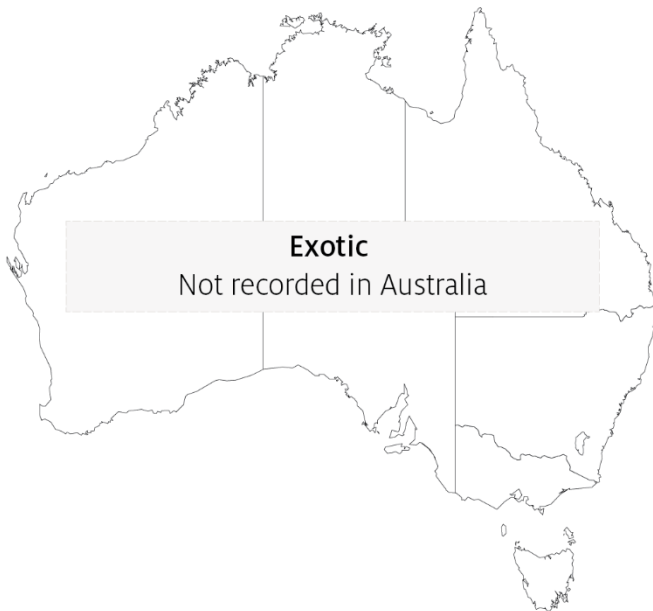^a Naturally susceptible. Note: Other species have been shown to be experimentally susceptible.

Presence in Australia

Exotic disease—not recorded in Australia.

The distantly related pilchard orthomyxo-like virus (POMV) has been reported from wild caught pilchards and cultured Atlantic salmon in Tasmania, but infectious salmon anaemia caused by infection with HPR-deleted or HPRO ISAV has not been recorded in Australia and is considered exotic.

Map 5 Presence of ISAV, by jurisdiction



Epidemiology

- ISA occurs mainly in the northern hemisphere in spring and early winter (water temperatures from 3°C to above 15°C).
- The disease has caused major epizootics and severely impacted Atlantic salmon aquaculture production in Norway, Scotland, Canada and Chile.
- Mortality rates vary from 15% to 100%; mortality may occur over a prolonged period, not necessarily as acute outbreaks.
- ISA is mainly transmitted horizontally through the water column, but also by vectors (sea lice and populations of asymptomatic wild fish carriers).
- Experimental infection demonstrated mortalities within 15 days of exposure to ISAV.
- Spread of the disease has occurred with the movement of live juvenile salmonids between fish farms, with the discharge of organic waste from fish processing plants into the marine environment and via water movement.
- The majority of natural outbreaks seem to occur in salmonid post-smolts.
- ISA has been the subject of extensive eradication campaigns in several countries. These can be successful, but require vigilance to maintain 'free' status.

- It appears that stressors such as husbandry practices (including treatment against salmon lice or infectious diseases), rising or falling temperatures, and poor water quality can predispose salmon to outbreaks of ISA.

Differential diagnosis

The list of [similar diseases](#) in the next section refers only to the diseases covered by this field guide. Gross pathological signs may also be representative of diseases not included in this guide. Do not rely on gross signs to provide a definitive diagnosis. Use them as a tool to help identify the listed diseases that most closely account for the observed signs.

Similar diseases

Bacterial kidney disease (BKD), enteric red mouth disease (ERMD), infection with *Aeromonas salmonicida* atypical strains, infection with salmonid alphavirus (SAV), infectious haematopoietic necrosis (IHN), infectious pancreatic necrosis (IPN) and piscirickettsiosis.

Sample collection

Only trained personnel should collect samples. Using only gross pathological signs to differentiate between diseases is not reliable, and some aquatic animal disease agents pose a risk to humans. If you are not appropriately trained, phone your state or territory hotline number and report your observations. If you have to collect samples, the agency taking your call will advise you on the appropriate course of action. Local or district fisheries or veterinary authorities may also advise on sampling.

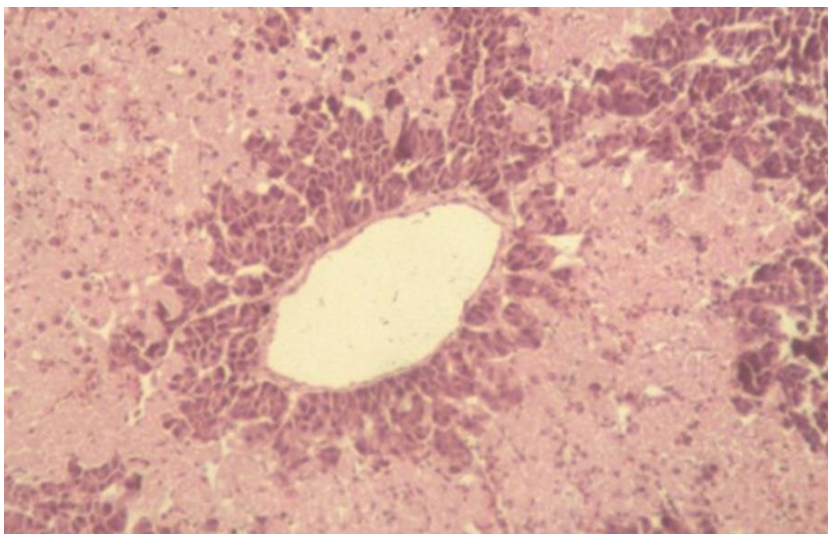
Emergency disease hotline

See something you think is this disease? Report it. Even if you're not sure.

Call the Emergency Animal Disease Watch Hotline on **1800 675 888**. They will refer you to the right state or territory agency.

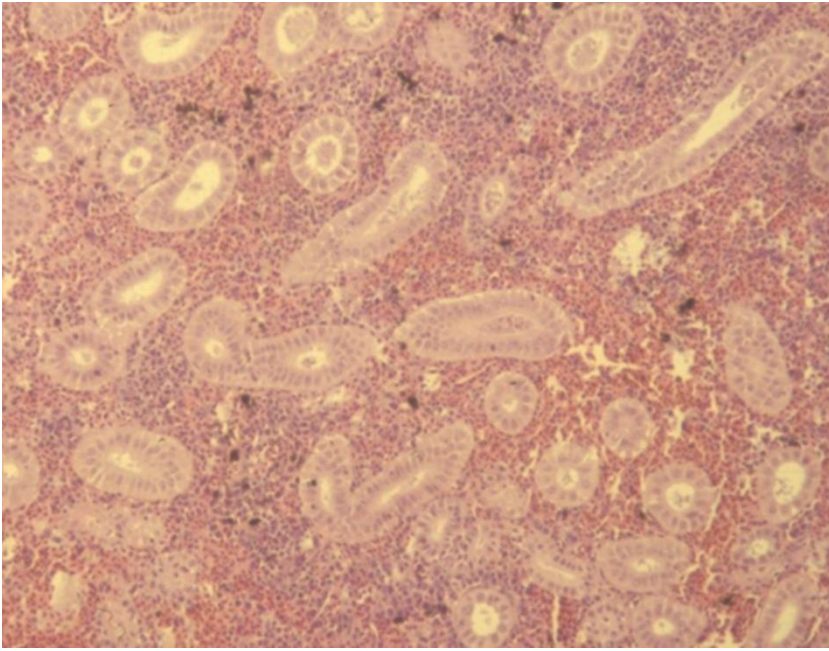
Microscope images

Figure 36 Histopathology of liver of Atlantic salmon (*Salmo salar*) with ISA



Note: Multifocal bridging necrosis, leaving viable tissue around smaller veins.
Source: T Poppe.

Figure 37 Histopathology of kidney of Atlantic salmon (*Salmo salar*) with ISA



Note: Renal interstitial haemorrhage.

Source: T Poppe

Further reading

Department of Agriculture [AQUAVETPLAN disease strategy manual: Infectious salmon anaemia](#)

World Organisation for Animal Health [Manual of diagnostic tests for aquatic animals](#)

Infection with infectious spleen and kidney necrosis virus (ISKNV)-like viruses

Exotic disease

Figure 38 Dwarf gourami (*Colisa lalia*) infected with an ISKNV-like iridovirus



Note: Pale colouration of diseased fish (top) compared with normal colours of unaffected fish (bottom).

Source: J Go

Figure 39 Murray cod (*Maccullochella peelii*) fingerling experimentally infected with an ISKNV-like iridovirus



Note: Discolouration around the front of the body (normal colouration evident near the tail) and signs of respiratory distress at time of death (flared opercula).

Signs of disease

Important: Animals with this disease may show one or more of these signs, but the pathogen may still be present in the absence of any signs.

Disease signs at the farm, tank or pond level are:

- mortalities between 50% and 100%
- fish remaining on bottom of tank and not feeding well
- lethargy
- respiratory distress (rapid movement of opercula).

Gross pathological signs are:

- changes in body colour (darkening or lightening)
- exophthalmos (popeye)
- abdominal distension (due to fluid or enlargement of organs).

Microscopic pathological signs are:

- basophilic hypertrophied cells throughout numerous body tissues, but especially the haematopoietic tissues of the kidney and spleen
- some virus affected cells may resemble amoebae in appearance.

Disease agent

ISKNV-like viruses are classified in the genus *Megalocytivirus*, family *Iridoviridae*. Viruses of this group are related to ranaviruses and predominantly cause disease in freshwater fish (particularly cichlids, gouramis and poeciliids). ISKNV-like megalocytiviruses that are genetically distinct from red seabream iridovirus (listed separately in this guide) (RSIV) are also being increasingly isolated from various species of euryhaline and/or estuarine fish, particularly within the orders Perciformes and Pleuronectiformes.

ISKNV-like megalocytiviruses

ISKNV-like viruses from cichlids (all fish belonging to the family Cichlidae):

- Angelfish iridovirus
- Cichlid iridovirus (includes ram cichlid and chromide cichlid. Although currently uncharacterised, based on histopathology, cichlid iridoviruses are considered to be megalocytiviruses)
- Iridovirus in *Apistogramma* spp.
- Iridovirus in oscars
- Iridovirus in rainbow krib
- Iridovirus in curviceps.

ISKNV-like viruses from gouramis (fish of the subfamilies Luciocephalinae and Macropodinae, family Osphronemidae):

- Dwarf gourami iridovirus (DGIV)
- Pearl gourami iridovirus
- Iridovirus in thick-lipped gourami, three-spot gourami and silver gourami
- Iridovirus in paradise fish.

ISKNV-like viruses from poeciliids (all fish belonging to the family Poeciliidae):

- African lampeye iridovirus (all fish belonging to the subfamily Aplocheilichthyinae, family Poeciliidae)
- Swordtail iridovirus (based on histopathology, swordtail iridovirus and other iridoviruses identified in the family Poeciliidae are considered to be megalocytiviruses)
- Iridovirus in mollies and platys
- Iridovirus in guppies.

ISKNV-like viruses from euryhaline or estuarine fish:

- Iridovirus in Chinese mandarin fish
- Iridovirus in tiger grouper hybrids
- Flatfish infected with turbot reddish body iridovirus (TRBIV)
- Iridovirus in barramundi with scale drop disease syndrome.

Host range

Table 8 Species known to be susceptible to ISKNV-like viruses

Common name	Scientific name
African lampeye killifish ^a	<i>Aplocheilichthys normani</i>
Amberjack	<i>Seriola dumerili</i>
Angelfish ^a	<i>Pterophyllum scalare</i>
Banggai cardinalfish ^a	<i>Pterapogon kauderni</i>
Barramundi ^a	<i>Lates calcarifer</i>
Blue tilapia	<i>Oreochromis aureus</i>
Chinese perch or mandarin fish ^a	<i>Siniperca chuatsi</i>
Curviceps ^a	<i>Laetacara curviceps</i>
Dwarf cichlids ^a	<i>Apistogramma</i> spp.
Dwarf gourami ^a	<i>Trichogaster lalius</i>
Flounders ^a	<i>Paralichthyidae</i> , all species
Giant grouper	<i>Epinephelus lanceolatus</i>
Golden perch	<i>Macquaria ambigua</i>
Grass carp	<i>Ctenopharyngodon idella</i>
Grouper and estuary cod ^a	<i>Epinephelus</i> spp.

Common name	Scientific name
Guppy ^a	<i>Poecilia reticulata</i>
Japanese parrotfish	<i>Oplegnathus fasciatus</i>
Japanese yellowtail ^a	<i>Seriola quinqueradiata</i>
Largemouth bass	<i>Micropterus salmoides</i>
Large yellow croaker	<i>Larimichthys crocea</i>
Macquarie perch	<i>Macquaria australasica</i>
Malabar grouper ^a	<i>Epinephelus malabaricus</i>
Mango tilapia	<i>Sarotherodon galilaeus</i>
Marble goby ^a	<i>Oxyeleotris marmorata</i>
Molly ^a	<i>Poecilia sphenops</i>
Murray cod ^a	<i>Maccullochella peelii</i>
Nile tilapia ^a	<i>Oreochromis niloticus</i>
Orange chromide ^a	<i>Etroplus maculatus</i>
Orange spotted grouper ^a	<i>Epinephelus coioides</i>
Orbiculate batfish ^a	<i>Platax orbicularis</i>
Oscar ^a	<i>Astronotus ocellatus</i>
Paradise fish ^a	<i>Macropodus opercularis</i>
Pearl gourami ^a	<i>Trichogaster leerii</i>
Rainbow krib ^a	<i>Pelvicachromis pulcher</i>
Ram cichlid ^a	<i>Mikrogeophagus ramirezi</i>
Red drum ^a	<i>Sciaenops ocellatus</i>
Redbelly tilapia	<i>Coptodon zilli</i>
Red sea bream ^a	<i>Pagrus major</i>
Sailfin mollies ^a	<i>Poecilia latipinna</i>
Sea bass ^a	<i>Plectranthias yamakawai</i>
Sea mullet ^a	<i>Mugil cephalus</i>
Silver gourami ^a	<i>Trichogaster microlepis</i>
Snapper	<i>Pagrus auratus</i>
Southern platyfish or red wagtail platy ^a	<i>Xiphophorus maculatus</i>
Southern pygmy perch	<i>Nannoperca australis</i>
Spangled emperor	<i>Lethrinus nebulosus</i>
Striped beakfish ^a	<i>Oplegnathus fasciatus</i>
Swordtail or green swordtail ^a	<i>Xiphophorus helleri</i>
Thick-lipped gourami ^a	<i>Colisa labiosa</i>
Three-spot gourami ^a	<i>Trichogaster trichopterus</i>
Tiger grouper hybrid ^a	<i>Epinephelus fuscoguttatus</i> × <i>E. lanceolatus</i>
Tilapias	<i>Cichlidae</i> , various genera and species
Tilapia hybrids	<i>Oreochromis niloticus</i> × <i>O. aureus</i>

Common name	Scientific name
Turbot ^a	<i>Scophthalmus maximus</i>
Zebrafish	<i>Danio rerio</i>

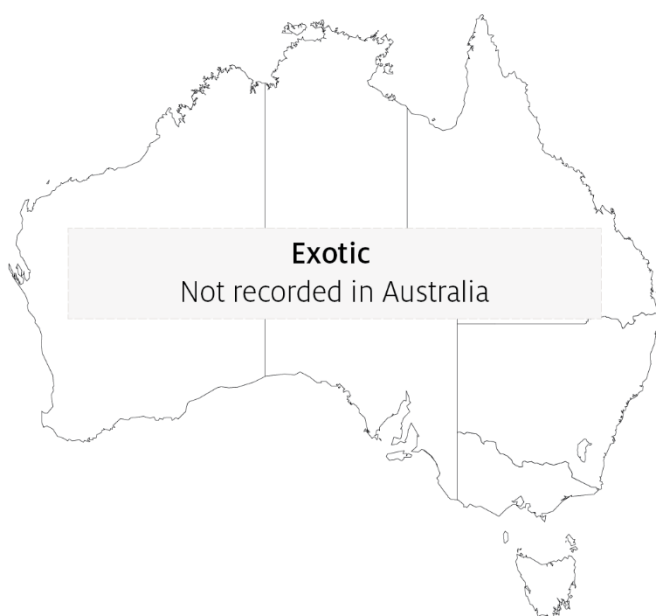a Naturally susceptible. Note: Other species have been shown to be experimentally susceptible. Some native Australian fish species included (such as Murray cod, *Maccullochella peelii*) are known to be highly susceptible to ISKNV-like viruses.

Presence in Australia

Exotic disease—not recorded in Australia.

ISKNV-like viruses have not been recorded from wild fish in Australia. However, these viruses are regularly detected in ornamental fish in quarantine at the international border, and in retail pet shops.

Map 6 Presence of ISKNV-like viruses, by jurisdiction



Epidemiology

- ISKNV-like viruses are prone to inactivation by desiccation or heat at temperatures above 50°C, but are stable in water at 4°C for extended periods.
- ISKNV-like viruses have been found to cause disease in a wide variety of species (may lack strict host specificity).
- Horizontal transmission via cohabitation, water, ingestion of excreta or cannibalism is likely (based on experimental transmission studies).
- There is evidence that some species may be long-term asymptomatic carriers of ISKNV-like viruses and that prevalence in infected populations may be high.

Differential diagnosis

The list of [similar diseases](#) in the next section refers only to the diseases covered by this field guide. Gross pathological signs may also be representative of diseases not included in this guide. Do not rely on gross signs to provide a definitive diagnosis. Use them as a tool to help identify the listed diseases that most closely account for the observed signs.

Similar diseases

Epizootic haematopoietic necrosis (EHN), grouper iridoviral disease and red sea bream iridoviral disease (RSIVD).

Sample collection

Only trained personnel should collect samples. Using only gross pathological signs to differentiate between diseases is not reliable, and some aquatic animal disease agents pose a risk to humans. If you are not appropriately trained, phone your state or territory hotline number and report your observations. If you have to collect samples, the agency taking your call will advise you on the appropriate course of action. Local or district fisheries or veterinary authorities may also advise on sampling.

Emergency disease hotline

See something you think is this disease? Report it. Even if you're not sure.

Call the Emergency Animal Disease Watch Hotline on **1800 675 888**. They will refer you to the right state or territory agency.

Further reading

Biosecurity Australia 2014, *Importation of freshwater ornamental fish: review of biosecurity risks associated with gourami iridovirus and related viruses—provisional final import risk analysis report*

Fu X, Li N, Liu L, Lin Q, Wang F, Lai Y, Jiang H, Pan H, Shi C, Wu S 2011, 'Genotype and host range analysis of infectious spleen and kidney necrosis virus (ISKNV)', *Virus Gene*

Infection with salmonid alphavirus (SAV)

Also known as infection with salmon pancreas disease virus (SPDV), salmon pancreas disease (SPD), pancreas disease (PD) and sleeping disease (SD)

Exotic disease

Figure 40 Atlantic salmon (*Salmo salar*) chronically infected with SAV



Note: Very thin carrier fish in poor condition a few months after infection.

Source: T Poppe

Signs of disease

Important: Animals with this disease may show one or more of these signs, but the pathogen may still be present in the absence of any signs.

Disease signs at the farm, tank or pond level are:

- Lack of appetite a week or two before a disease outbreak
- clinically diseased fish may swim against the current close to the surface or corners of the cage, or be found resting at the bottom of the tank or cage (sleeping)
- one to several months after the onset of mortality, a portion of the survivors usually fail to grow and become thin and slender (runts).

Gross pathological signs are:

- yellow mucoid gut contents
- petechiae in pyloric fat, pale hearts and/or haemopericardium due to heart rupture
- scale pocket oedema

- exophthalmos
- ascites
- atrophy of red skeletal muscle in chronic cases.

Microscopic pathological signs are:

- the development of necrosis of exocrine pancreas shortly before cardiomyocytic necrosis
- severe or total loss of exocrine pancreas, myocarditis and skeletal muscle necrosis, degeneration and myositis
- damage, primarily of the pancreas, and severe cardiac and skeletal myopathies.

Disease agent

SPD is caused by infection with salmonid alphavirus (SAV), a member of the family *Togaviridae* in the genus *Alphavirus*. Various genetic subtypes of the virus have been detected. SPD first emerged in Scotland and subsequently recognised in France, Ireland, England, Norway, Germany, Italy and Spain.

Host range

Clinical signs of salmon pancreas disease have been reported in Atlantic salmon, sea-reared rainbow trout, brown trout and Arctic char. Wild fish (such as flatfish and wrasses) can be subclinically infected and may act as potential vectors or reservoirs of infection.

Table 9 Species known to be susceptible to SAV

Common name	Scientific name
American plaice ^a	<i>Hippoglossoides platessoides</i>
Arctic char ^a	<i>Salvelinus alpinus</i>
Atlantic salmon ^a	<i>Salmo salar</i>
Brown trout	<i>Salmo trutta</i>
Dab ^a	<i>Limanda limanda</i>
Plaice ^a	<i>Pleuronectes platessa</i>
Rainbow trout ^a	<i>Oncorhynchus mykiss</i>
Wrasse ^a	<i>Labrus bergylta</i>

^a Naturally susceptible. Note: Other species have been shown to be experimentally susceptible.

Presence in Australia

Exotic disease—not recorded in Australia.

Map 7 Presence of SAV, by jurisdiction



Epidemiology

- SAV is horizontally transmitted, via water and water currents, transport of infected fish, contaminated equipment, well boats and other vehicles. The virus can survive for extended periods in seawater.
- Vertical transmission is considered unlikely but has not been ruled out.
- Water temperature may affect the duration and level of mortality.
- Subtypes 1, 2, 3, 4, 5 and 6 may have different virulence in different hosts.
- All marine life stages of Atlantic salmon are susceptible to disease, from smolts to adult fish. Different strains of Atlantic salmon may have different susceptibility to SAV.
- Farmed rainbow trout in fresh water and salt water are susceptible to disease at all stages of production.
- Mortality varies significantly, from negligible to over 50% in severe cases. Up to 15% of surviving fish will develop into long, slender fish (runts).
- Management and environmental factors that induce stress in fish probably increase mortality significantly.
- Natural reservoirs of SAV may include wild fish. SAV has been detected in some wild flatfish species in Scotland and in wrasses used for sealice management in Ireland.

Differential diagnosis

The list of [similar diseases](#) in the next section refers only to the diseases covered by this field guide. Gross pathological signs may also be representative of diseases not included in this guide. Do not rely on gross signs to provide a definitive diagnosis. Use them as a tool to help identify the listed diseases that most closely account for the observed signs.

Similar diseases

Infection with HPR-deleted or HPRO infectious salmon anaemia virus and infectious pancreatic necrosis (IPN).

Sample collection

Only trained personnel should collect samples. Using only gross pathological signs to differentiate between diseases is not reliable, and some aquatic animal disease agents pose a risk to humans. If you are not appropriately trained, phone your state or territory hotline number and report your observations. If you have to collect samples, the agency taking your call will advise you on the appropriate course of action. Local or district fisheries or veterinary authorities may also advise on sampling.

Emergency disease hotline

See something you think is this disease? Report it. Even if you're not sure.

Call the Emergency Animal Disease Watch Hotline on **1800 675 888**. They will refer you to the right state or territory agency.

Further reading

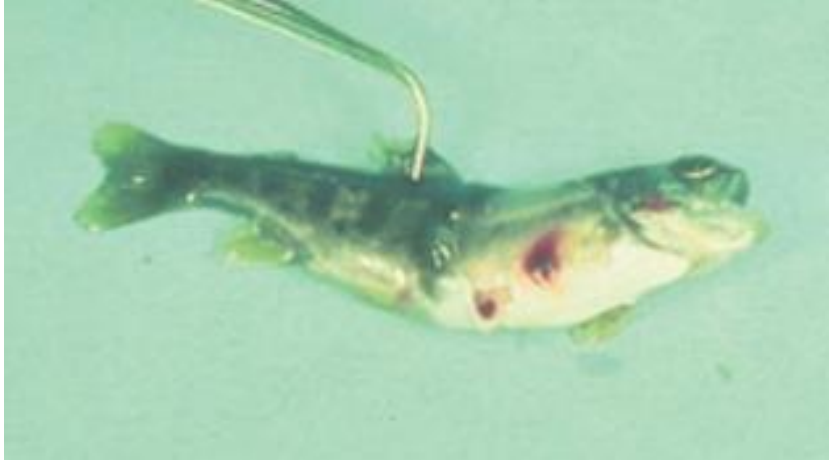World Organisation for Animal Health [Manual of diagnostic tests for aquatic animals](#)

Infectious haematopoietic necrosis (IHN)

Also known as infection with infectious haematopoietic necrosis virus (IHNV)

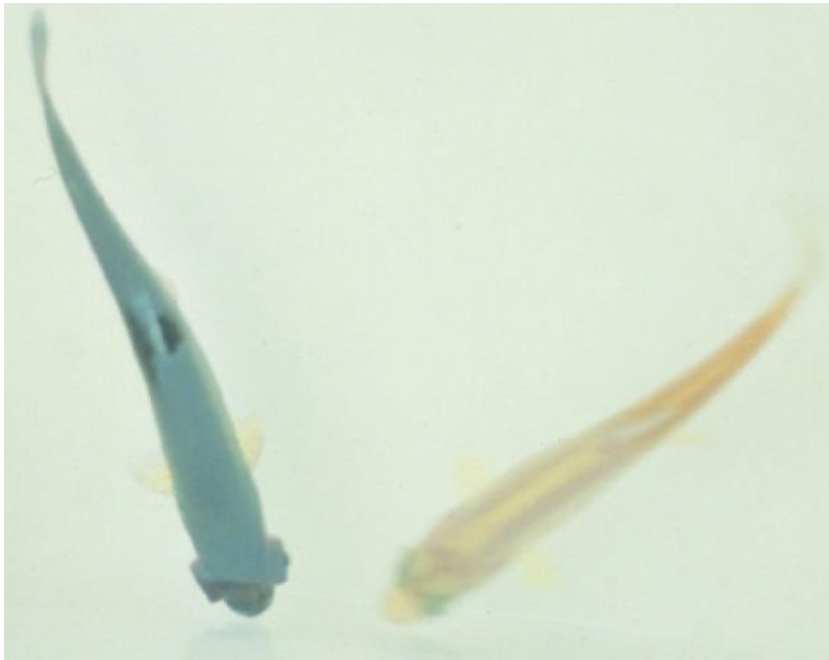
Exotic disease

Figure 41 Chinook salmon fry (*Oncorhynchus tshawytscha*) with IHN



Note: Characteristic darkening from the tail region, swollen abdomen and haemorrhaging at base of the fins.
Source: J Fryer

Figure 42 Rainbow trout fry (*Oncorhynchus mykiss*) with and without IHN



Note: Infected fish (left) shows darker colouring and exophthalmia compared to the uninfected fish (right)
Source: G Kurath

Signs of disease

Important: Animals with this disease may show one or more of these signs, but the pathogen may still be present in the absence of any signs.

Disease signs at the farm, tank or pond level are:

- mass mortality
- lethargic swimming with intermittent bouts of frenzied, abnormal activity (spiral swimming and flashing).

Gross pathological signs are:

- numerous yolk sac haemorrhages in the fry of rainbow trout and salmon
- darkening of the skin and pale gills
- haemorrhages on the abdomen and around the pupil of the eye
- exophthalmos (popeye) and a swollen abdomen
- trailing white faecal cast
- bleeding at the base of the fins
- stomach empty of food but distended with a gelatinous substance
- pale internal organs
- petechial (pinpoint) haemorrhages in the fatty tissue and muscle surrounding the organs and stomach wall
- spinal deformities in surviving fish.

Microscopic pathological signs are:

- necrosis of eosinophilic granular cells in the intestinal wall
- degenerative necrosis in haematopoietic tissues.

Disease agent

IHN is caused by infection with salmonid *Novirhabdovirus*, also known as infectious haematopoietic necrosis virus (IHNV). This virus is an enveloped single-stranded, negative-sense RNA virus classified within the family *Novirhabdoviridae*, and is closely related to other important fish rhabdoviruses such as viral haemorrhagic septicaemia virus (VHSV) and spring viraemia of carp virus (SVCV). Molecular analysis suggests that IHNV was originally endemic to the Pacific coast of North America, and was spread to Europe and Asia through translocations of salmonid eggs or fry.

Host range

Table 10 Species known to be susceptible to IHN

Common name	Scientific name
Amago salmon ^a	<i>Oncorhynchus rhodurus</i>
Arctic char	<i>Salvelinus alpinus</i>
Atlantic cod ^a	<i>Gadus morhua</i>
Atlantic salmon ^a	<i>Salmo salar</i>
Ayu	<i>Plecoglossus altivelis</i>
Brook trout ^a	<i>Salvelinus fontinalis</i>
Brown trout ^a	<i>Salmo trutta</i>
Burbot	<i>Lota lota</i>
Chinook salmon ^a	<i>Oncorhynchus tshawytscha</i>
Chum salmon ^a	<i>Oncorhynchus keta</i>
Coho salmon ^a	<i>Oncorhynchus kisutch</i>
Cutthroat trout ^a	<i>Oncorhynchus clarkii</i>
Gilt-head sea bream	<i>Sparus aurata</i>
Grayling	<i>Thymallus thymallus</i>
Lake trout	<i>Salvelinus namaycush</i>
Masu salmon ^a	<i>Oncorhynchus masou</i>
Pacific herring	<i>Clupea pallasii</i>
Pacific salmon ^a	<i>Oncorhynchus</i> spp.
Pike	<i>Esox lucius</i>
Pile perch	<i>Rhacochilus vacca</i>
Pink salmon ^a	<i>Oncorhynchus gorbuscha</i>
Rainbow trouta	<i>Oncorhynchus mykiss</i>
Shiner perch	<i>Cymatogaster aggregata</i>
Sockeye salmon ^a	<i>Oncorhynchus nerka</i>
Tubesnout	<i>Aulorhynchus flavidus</i>
Turbot	<i>Scophthalmus maximus</i>
Whitespotted char	<i>Salvelinus leucomaenis</i>
White sturgeon	<i>Acipenser transmontanus</i>

^a Naturally susceptible. Note: Other species have been shown to be experimentally susceptible.

Table 11 Non-fish carriers

Common name	Scientific name
Gill lice	<i>Salmincola</i> spp.
Leeches	<i>Piscicola</i> spp.
Mayfly	<i>Callibaetis</i> spp.
Piscivorous birds	Various genera and species

Presence in Australia

Exotic disease—not recorded in Australia.

Map 8 Presence of IHN, by jurisdiction



Epidemiology

- IHN is a cold-water disease. Clinical signs typically occur at temperatures between 8°C and 15°C. Outbreaks rarely occur once water temperatures reach more than 15°C.
- IHN is typically found in young, farmed trout and salmon fry or fingerlings, and in adults during or just following spawning.
- Mass mortalities of up to 90% can occur in hatcheries, typically with 100% of the population infected.
- Mortality also occurs in wild populations of Pacific salmon infected with IHNV. Survivors can be the source of infection of farmed stock.
- Susceptibility to infection varies between individuals of the same species and appears to be largely age dependent, with younger individuals being more susceptible.
- Fish that survive IHN are potential carriers of the virus for a period that depends on environmental conditions (such as temperature).
- The virus is shed into the water from infected fish through faeces, urine, spawning fluids and external mucous.
- Transmission is generally horizontal, with the virus entering fish through the gills and skin. Some blood-sucking parasites such as gill lice (*Salmincola* spp.) and leeches may serve as vectors.
- Virus can be transferred to new areas via the movement of infected fish or eggs, and by other sources such as contaminated equipment, water, birds or insects such as mayflies.
- Outbreaks are most likely to occur around the time of spawning, with increased levels of virus released into the environment with spawning fluids.

- It is believed that the spread of IHNV from the west coast of North America to Asia and Europe has been principally via the shipment of infected fish and eggs, suggesting some degree of vertical transmission. The risk of such egg-associated transmission is significantly reduced by the common practice of egg surface disinfection, but is not eliminated.

Differential diagnosis

The list of [similar diseases](#) in the next section refers only to the diseases covered by this field guide. Gross pathological signs may also be representative of diseases not included in this guide. Do not rely on gross signs to provide a definitive diagnosis. Use them as a tool to help identify the listed diseases that most closely account for the observed signs.

Similar diseases

Enteric red mouth disease, epizootic haematopoietic necrosis (EHN), furunculosis, infectious pancreatic necrosis (IPN), infection with HPR-deleted or HPRO infectious salmon anaemia virus, viral haemorrhagic septicaemia (VHS) and whirling disease.

Sample collection

Only trained personnel should collect samples. Using only gross pathological signs to differentiate between diseases is not reliable, and some aquatic animal disease agents pose a risk to humans. If you are not appropriately trained, phone your state or territory hotline number and report your observations. If you have to collect samples, the agency taking your call will advise you on the appropriate course of action. Local or district fisheries or veterinary authorities may also advise on sampling.

Emergency disease hotline

See something you think is this disease? Report it. Even if you're not sure.

Call the Emergency Animal Disease Watch Hotline on **1800 675 888**. They will refer you to the right state or territory agency.

Further reading

CEFAS International Database on Aquatic Animal Diseases [Infectious Haematopoietic Necrosis](#)

World Organisation for Animal Health [Manual of diagnostic tests for aquatic animals](#)

Infectious pancreatic necrosis (IPN)

Also known as infection with infectious pancreatic necrosis virus (IPNV)

Exotic disease

Figure 43 IPN in rainbow trout (*Oncorhynchus mykiss*)



Note: Abdominal distension and darkened body colour.

Source: T Håstein

Signs of disease

Important: Animals with this disease may show one or more of these signs, but the pathogen may still be present in the absence of any signs.

Signs of disease described are representative of IPN in salmonids.

Disease signs at the farm, tank or pond level are:

- sudden and progressive increase in mortality at first feeding of fry, particularly in faster growing individuals
- cumulative mortality rates from 10% to 90%
- low persistent mortality
- fish lying still on the bottom of tanks or ponds
- fish swimming with a spiralling, corkscrew motion.

Gross pathological signs are:

- long, thin, whitish trailing faecal casts
- swollen abdomen
- darkening body colour
- typically pale gills
- exophthalmos (popeye)

- lesions and ulcers in pancreas, oesophagus and stomach
- haemorrhages sometimes present in ventral areas, including the ventral fins
- abnormally pale spleen, kidney, liver and heart of fry
- intestines empty or filled with clear mucus.

Microscopic pathological signs are:

- extensive and/or severe necrosis of acinar pancreatic cells
- focal or generalised necrosis of liver
- sloughing of intestinal mucosa with characteristic McKnight cells in the lumen (eosinophilic and hyaline epithelial cells).

Disease agent

IPN is caused by infection with infectious pancreatic necrosis virus (IPNV), a double stranded RNA virus classified within the genus *Aquabirnavirus* (family *Birnaviridae*). Several genogroups have been identified and are described by their different hosts and geographical origins. The most frequently found and highly virulent strain of IPNV is the Sp serotype in genogroup 5.

Host range

A wide range of marine and freshwater fish species are susceptible to IPNV. The disease agent can be spread naturally by mechanical vectors such as piscivorous birds (including passage through the bird digestive system), blood feeding parasites and filter feeding molluscs (such as common European scallop *Pecten maximus*).

Table 12 Fish species likely to be severely affected by IPNV

Common name	Scientific name
American eel ^a	<i>Anguilla rostrata</i>
Atlantic cod	<i>Gadus morhua</i>
Atlantic halibut	<i>Hippoglossus hippoglossus</i>
Atlantic salmon ^a	<i>Salmo salar</i>
Brook trout ^a	<i>Salvelinus fontinalis</i>
Brown trout ^a	<i>Salmo trutta</i>
Coho salmon	<i>Oncorhynchus kisutch</i>
Eels ^a	<i>Anguillidae</i> , all species
European eel	<i>Anguilla anguilla</i>
Japanese eel	<i>Anguilla japonica</i>
Pacific salmon	<i>Oncorhynchus</i> spp.
Rainbow trout ^a	<i>Oncorhynchus mykiss</i>
Shortfin eel	<i>Anguilla australis</i>
Turbot	<i>Scophthalmus maximus</i>
Wrasses	<i>Labridae</i> , all species

^a Naturally susceptible. Note: Other species likely to be susceptible or have been shown to be experimentally susceptible.

Table 13 Non-fish carriers

Common name	Scientific name
Common European scallop	<i>Pecten maximus</i>
European flat oyster	<i>Ostrea edulis</i>
Fish louse	<i>Argulus foliaceus</i>
Molluscs	Various genera and species
Piscivorous birds	Various genera and species
Salmon louse	<i>Lepeophtheirus salmonis</i> and <i>Caligus coryphaenae</i>

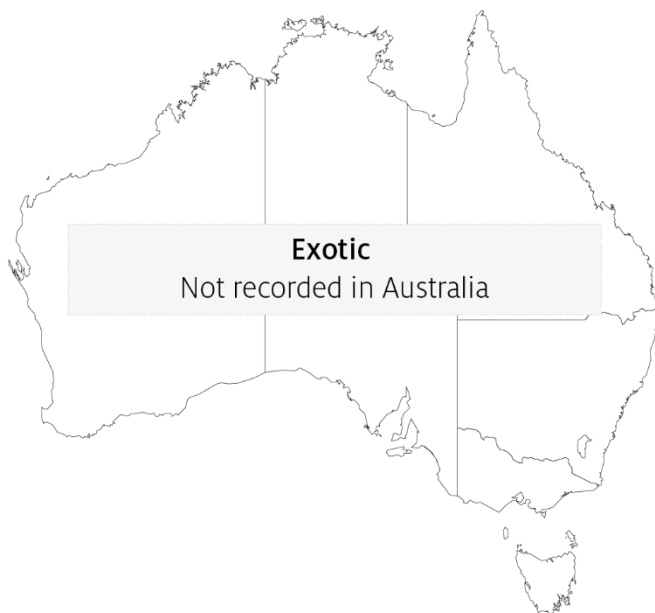Presence in Australia

Exotic disease—not recorded in Australia.

Other aquabirnaviruses, distinct from IPNV, are present in Australia and New Zealand.

- Tasmanian aquabirnavirus in farmed Atlantic salmon and rainbow trout.
- Victorian trout aquabirnavirus in farmed rainbow trout.
- New Zealand birnavirus in diseased turbot and asymptomatic sea-run chinook salmon.

Map 9 Presence of IHN, by jurisdiction



Epidemiology

- IPNV is highly contagious and fish that survive infection are presumed to become carriers. Asymptomatic carrier fish represent a risk for introduction of disease to healthy stocks.
- Viral transmission can occur horizontally (the virus enters fish through the gills or gastrointestinal tract) and vertically (transmitted via eggs of infected carrier broodfish).
- IPNV is shed in faeces, urine, spawning fluids and external mucus. Spawning favours the transmission of IPN virus with increased levels of virus excreted in spawning fluids.
- Outbreaks of disease are most likely to occur when fish are stressed. Factors raising physiological stress levels include first feeding, high stocking densities, fluctuations in water

temperature and salinity and management practices requiring handling of fish. Outbreaks are known to occur at water temperatures as low as 4°C and as high as 18°C.

- The disease can cause high mortalities (70%) in young trout, with cumulative mortalities of 10% to 90%.
- The highest mortality rates usually occur in freshwater hatcheries in fry less than 6 months of age. However, IPN is known to affect rainbow trout and post-smolt Atlantic salmon after transfer from freshwater to seawater.
- IPNV can survive in both freshwater and saltwater environments. It is quite stable and resists destruction by disinfection, enabling it to persist in a range of environmental conditions on equipment such as nets and containers.
- Virus may be spread and healthy stocks exposed via contaminated transport water, infected eggs and blood feeding parasites. Piscivorous birds and molluscs are also known vectors of IPNV.

Differential diagnosis

The list of [similar diseases](#) in the next section refers only to the diseases covered by this field guide. Gross pathological signs may also be representative of diseases not included in this guide. Do not rely on gross signs to provide a definitive diagnosis. Use them as a tool to help identify the listed diseases that most closely account for the observed signs.

Similar diseases

Infection with HPR-deleted or HPRO infectious salmon anaemia virus, infection with salmonid alphavirus (SAV), infectious haematopoietic necrosis (IHN) and viral haemorrhagic septicaemia (VHS).

Sample collection

Only trained personnel should collect samples. Using only gross pathological signs to differentiate between diseases is not reliable, and some aquatic animal disease agents pose a risk to humans. If you are not appropriately trained, phone your state or territory hotline number and report your observations. If you have to collect samples, the agency taking your call will advise you on the appropriate course of action. Local or district fisheries or veterinary authorities may also advise on sampling.

Emergency disease hotline

See something you think is this disease? Report it. Even if you're not sure.

Call the Emergency Animal Disease Watch Hotline on **1800 675 888**. They will refer you to the right state or territory agency.

Further reading

CABI Invasive Species Compendium [Infectious Pancreatic Necrosis](#)

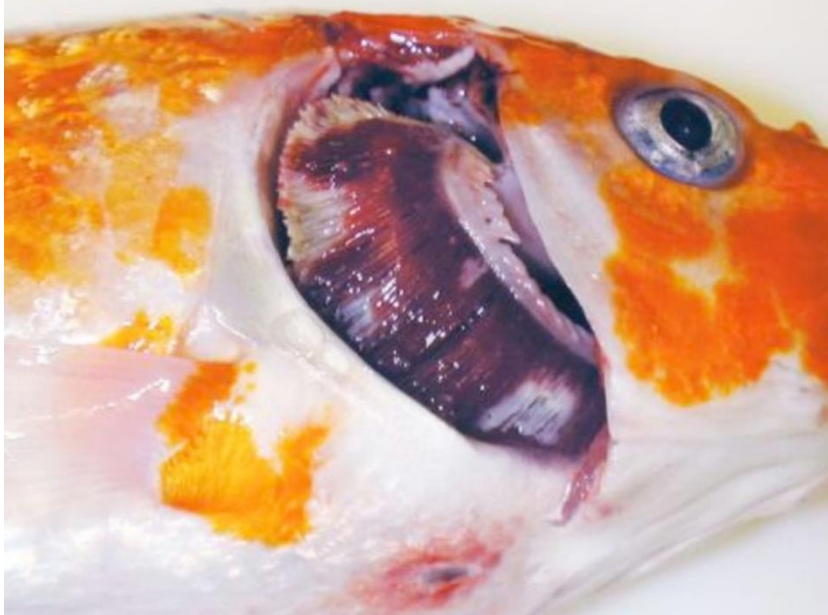CEFAS International Database on Aquatic Animal Diseases [Infectious Pancreatic Necrosis](#)

Koi herpesvirus disease (KHVD)

Also known as carp interstitial nephritis, gill necrosis virus, infection with koi herpesvirus (KHV) and infection with cyprinid herpesvirus 3 (CyHV3)

Exotic disease

Figure 44 Koi carp (*Cyprinus carpio*) with gross lesions associated with KHVD



Note: Operculum is removed showing mottled red (haemorrhage) and white (necrosis) gill, sunken eyes and a single ulcer on the ventral skin.

Source: E Johnson

Signs of disease

Important: Animals with this disease may show one or more of these signs, but the pathogen may still be present in the absence of any signs.

Disease signs at the farm, tank or pond level are:

- mass mortalities, with many dead and moribund fish floating at the surface
- disorientation and erratic swimming behaviour (sometimes hyperactivity)
- fish coming to the surface and gasping
- fish separated from the shoal.

Gross pathological signs are:

- pale patches on the skin
- overproduction or underproduction of mucous on the skin and gills
- superficial branchial (gill) and skin haemorrhages
- endophthalmia (sunken eyes), erosion of the fins (occasionally), and blistering of the skin
- severe gill necrosis and/or erosion, seen as red and white patches
- focal or generalised loss of skin

- adhesions in the abdominal cavity and abnormal colouration of internal organs (lighter or darker or mottled)
- enlargement and surface haemorrhages of the kidney and liver.

Microscopic pathological signs are:

- inflammation and necrosis of gill tissues, and adhesion of gill filaments
- nuclear swelling, margination of chromatin and pale eosinophilic intranuclear inclusions of the epithelium
- non-specific inflammation and necrosis in other organs.

Disease agent

KHVD is caused by infection with koi herpesvirus (KHV), also known as cyprinid herpesvirus 3 (CyHv3), a virus classified as a member of the family *Alloherpesviridae* within the genus *Cyprinivirus*.

Host range

Naturally occurring KHV infections have only been recorded from common carp (*Cyprinus carpio*) and varieties of this species (such as koi carp). Goldfish × common carp hybrids, produced by hybridising male goldfish with female carp, have been reported to show some susceptibility to KHV infection.

Several fish species have been described as asymptomatic carrier species. These show no clinical signs of KHVD after natural or experimental exposure to KHV, but carry viral DNA, allowing them to potentially act as vectors of the disease. Viral DNA has been also been detected in two non-fish species, amphipods (*Gammarus pulex*) and swan mussels (*Anodonta cygnea*), making them potential vectors.

Table 14 Species known to be naturally susceptible to KHVD

Common name	Scientific name
Common carp and koi carp	<i>Cyprinus carpio</i>

Table 15 Potential carriers

Common name	Scientific name
Atlantic sturgeon	<i>Acipenser oxyrinchus</i>
Common roach	<i>Rutilus rutilus</i>
Crucian carp	<i>Carassius carassius</i>
Eurasian ruffe	<i>Gymnocephalus cernua</i>
Goldfish or shubunkin	<i>Carassius auratus</i>
Grass carp	<i>Ctenopharyngodon idella</i>
Ide	<i>Leuciscus idus</i>
Redfin or European perch	<i>Perca fluviatilis</i>
Russian sturgeon	<i>Acipenser gueldenstaedtii</i>
Silver carp	<i>Hypophthalmichthys molitrix</i>
Tench	<i>Tinca tinca</i>

Table 16 Non-fish carriers

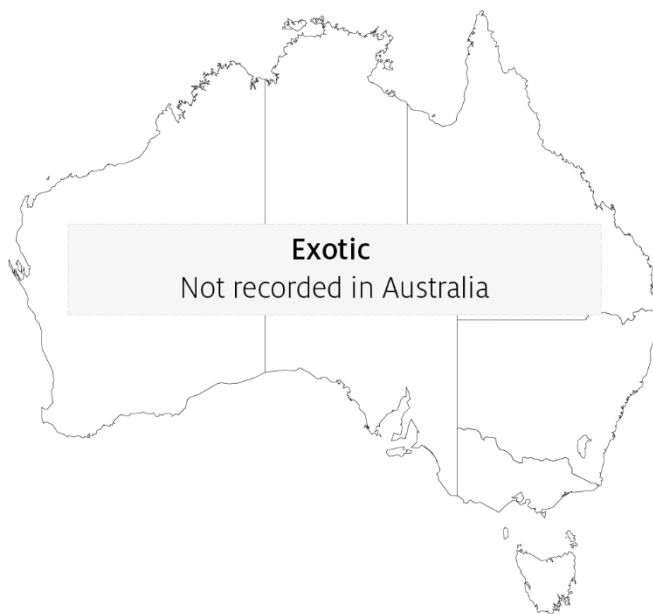Common name	Scientific name
Amphipods	<i>Gammarus pulex</i>
Swan mussels	<i>Anodonta cygnea</i>

Presence in Australia

Exotic disease—not recorded in Australia.

KHV has not been recorded from Australia, and is considered exotic. The potential use of KHV as a biological control for introduced populations of European carp is being investigated.

Map 10 Presence of KHV, by jurisdiction



Epidemiology

- An outbreak of KHVD in Japan during the spring of 2004 occurred in wild carp populations in water temperatures of 15 to 16°C. Most of the dead fish were adult. In the field, it appears that adult carp are more susceptible than juveniles.
- The virus may survive at low temperatures (5°C), but the temperature range for disease outbreaks is primarily between 16°C and 25°C. Mortalities commonly appear between 22°C and 25°C, with few at temperatures above 30°C.
- The disease affects all age classes of common and koi carp, occurring in fingerlings, juveniles and adults.
- Moving infected fish from cool (13°C) to warm (23°C) water results in rapid onset of mortality.
- Mortality rates can vary between 70% and 100%.
- Reservoirs of KHV are clinically infected fish and covert carriers. Virus is shed via faeces, urine, gills and skin mucus.
- Transmission of KHV is horizontal, mainly via water, but possibly via animal vectors and fomites.
- Vertical transmission cannot be excluded as a possible transmission route.

- Secondary gill infections (including *Flavobacterium columnare* and *Aeromonas* spp.) are often associated with KHV infection.

Differential diagnosis

The list of [similar diseases](#) in the next section refers only to the diseases covered by this field guide. Gross pathological signs may also be representative of diseases not included in this guide. Do not rely on gross signs to provide a definitive diagnosis. Use them as a tool to help identify the listed diseases that most closely account for the observed signs.

Similar diseases

Infection with *Aeromonas salmonicida*—atypical strains, infection with *Aphanomyces invadans* (EUS) and spring viraemia of carp (SVC).

Sample collection

Only trained personnel should collect samples. Using only gross pathological signs to differentiate between diseases is not reliable, and some aquatic animal disease agents pose a risk to humans. If you are not appropriately trained, phone your state or territory hotline number and report your observations. If you have to collect samples, the agency taking your call will advise you on the appropriate course of action. Local or district fisheries or veterinary authorities may also advise on sampling.

Emergency disease hotline

See something you think is this disease? Report it. Even if you're not sure.

Call the Emergency Animal Disease Watch Hotline on **1800 675 888**. They will refer you to the right state or territory agency.

Further reading

CABI Invasive Species Compendium [Koi herpesvirus disease](#)

CEFAS International Database on Aquatic Animal Diseases [Koi herpesvirus disease](#)

World Organisation for Animal Health [Manual of diagnostic tests for aquatic animals](#)

Red sea bream iridoviral disease (RSIVD)

Also known as infection with red sea bream iridovirus (RSIV)

Exotic disease

Figure 45 Red sea bream (*Pagrus major*) from South Korea infected with RSIV



Note: Swollen abdomen due to enlargement of internal organs and fluid accumulation. *P. major* is a close relative of the Australian snapper.

Source: S I Park.

Signs of disease

Important: Animals with this disease may show one or more of these signs, but the pathogen may still be present in the absence of any signs.

Disease signs at the farm, tank or pond level are:

- low to high mortality
- lethargic swimming
- obvious opercular movement (increased respiratory effort).

Gross pathological signs are:

- dark skin (change in skin colour is a significant gross sign)
- petechial (pinpoint) haemorrhage of the gills
- pale gills and enlarged spleen.

Microscopic pathological signs are:

- enlarged cells, deeply giemsa positive, in the spleen, heart, kidney, liver and gills of infected fish, which are characteristic of this disease
- small dark spots within fresh wet mounts of gill lamellae (melano-macrophage centres).

Disease agent

RSIVD is caused by infection with red sea bream iridovirus (RSIV), from the genus *Megalocytivirus* within the family *Iridoviridae*.

Host range**Table 17 Species known to be naturally susceptible to RSIV**

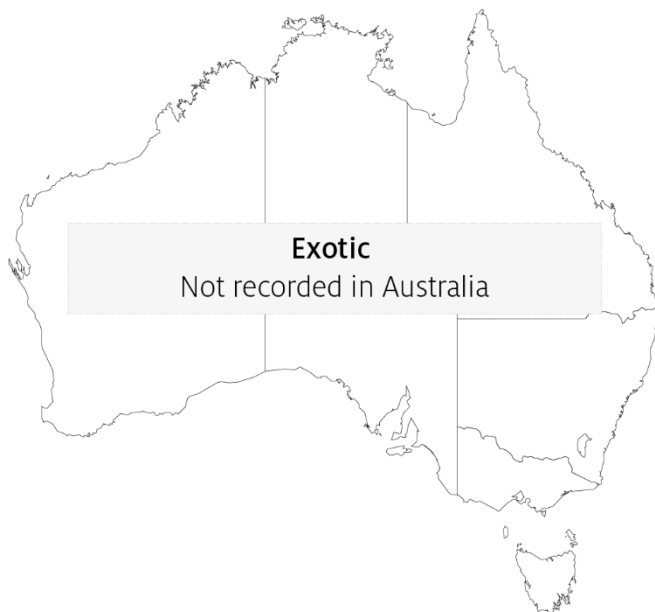Common name	Scientific name
Amberjack	<i>Seriola dumerili</i>
Barramundi	<i>Lates calcarifer</i>
Black rockfish	<i>Sebastes schlegelii</i>
Black sea bream or black porgy	<i>Acanthopagrus schlegelii</i>
Brown marbled grouper	<i>Epinephelus fuscoguttatus</i>
Chicken grunt	<i>Parapristipoma trilineatum</i>
Chinese emperor	<i>Lethrinus haematopterus</i>
Chinese perch or mandarin fish	<i>Siniperca chuatsi</i>
Chub mackerel	<i>Scomber japonicus</i>
Cobia	<i>Rachycentron canadum</i>
Coral trout	<i>Plectropomus leopardus</i>
Crescent sweetlips	<i>Plectorhinchus cinctus</i>
Crimson seabream	<i>Eyynnix japonica</i>
Large yellow croaker	<i>Larimichthys crocea</i>
Devil stinger	<i>Inimicus japonicus</i>
Estuary cod	<i>Epinephelus tauvina</i>
Giant grouper	<i>Epinephelus lanceolatus</i>
Girella or rudderfish	<i>Girella punctata</i>
Japanese flounder	<i>Paralichthys olivaceus</i>
Japanese horse mackerel	<i>Trachurus japonicus</i>
Japanese parrotfish	<i>Oplegnathus fasciatus</i>
Japanese seabass	<i>Lateolabrax japonicus</i>
Japanese spanish mackerel	<i>Scomberomorus niphonius</i>
Japanese yellowtail	<i>Seriola quinqueradiata</i>
Largemouth bass	<i>Micropterus salmoides</i>
Longtooth grouper	<i>Epinephelus bruneus</i>
Malabar grouper	<i>Epinephelus malabaricus</i>
Northern bluefin tuna	<i>Thunnus thynnus</i>
Orange-spotted grouper	<i>Epinephelus coioides</i>
Red sea bream	<i>Pagrus major</i>
Red-spotted grouper or Hong Kong grouper	<i>Epinephelus akaara</i>
Samson fish	<i>Seriola hippos</i>
Seabass	<i>Lateolabrax spp.</i>
Seven-band grouper	<i>Hyporthodus septemfasciatus</i>
Silver trevally	<i>Pseudocaranx dentex</i>
Six-bar grouper	<i>Epinephelus sexfasciatus</i>

Common name	Scientific name
Snapper	<i>Chrysophrys auratus</i>
Snubnose dart	<i>Trachinotus blochii</i>
Spangled emperor	<i>Lethrinus nebulosus</i>
Spotted coralgroupers	<i>Plectropomus maculatus</i>
Spotted halibut	<i>Verasper variegatus</i>
Spotted knifejaw	<i>Oplegnathus punctatus</i>
Tiger grouper hybrid	<i>Epinephelus fuscoguttatus</i> × <i>E. lanceolatus</i>
Tiger puffer	<i>Takifugu rubripes</i>
Yellow grouper	<i>Epinephelus awoara</i>
Yellowback seabream	<i>Evynnis tumifrons</i>
Yellowfin seabream	<i>Acanthopagrus latus</i>
Yellowtail kingfish	<i>Seriola lalandi</i>

Presence in Australia

Exotic disease—not recorded in Australia.

Map 11 Presence of RSIV, by jurisdiction



Epidemiology

- RSIVD is highly contagious.
- Juveniles are more susceptible to disease than adults.
- Mortality is highly variable (0% to 100%) and can depend on water temperature, with higher mortalities occurring at higher water temperatures.
- Transmission is horizontal, via the water column from other infected fish. Vertical transmission has yet to be confirmed.
- Outbreaks of disease occur at water temperatures greater than 20°C, with viral multiplication increasing with water temperatures up to at least 28°C.

- The virus is stable within tissue to -80°C , and can be inactivated by ether, chloroform and formalin.

Differential diagnosis

The list of [similar diseases](#) in the next section refers only to the diseases covered by this field guide. Gross pathological signs may also be representative of diseases not included in this guide. Do not rely on gross signs to provide a definitive diagnosis. Use them as a tool to help identify the listed diseases that most closely account for the observed signs.

Similar diseases

Epizootic haematopoietic necrosis (EHN), grouper iridoviral disease, infection with infectious spleen and kidney necrosis virus (ISKNV)-like viruses and Tilapia lake virus (TILV) disease.

Sample collection

Only trained personnel should collect samples. Using only gross pathological signs to differentiate between diseases is not reliable, and some aquatic animal disease agents pose a risk to humans. If you are not appropriately trained, phone your state or territory hotline number and report your observations. If you have to collect samples, the agency taking your call will advise you on the appropriate course of action. Local or district fisheries or veterinary authorities may also advise on sampling.

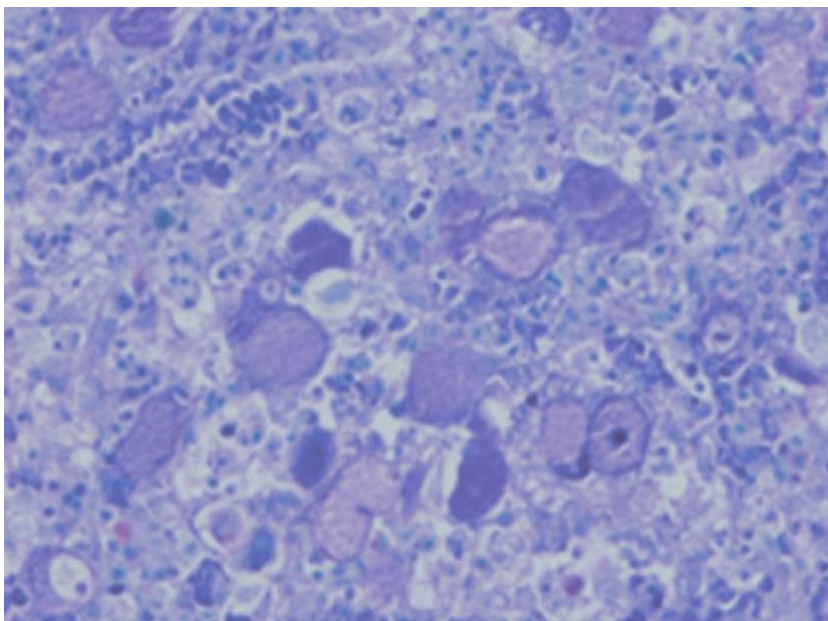
Emergency disease hotline

See something you think is this disease? Report it. Even if you're not sure.

Call the Emergency Animal Disease Watch Hotline on **1800 675 888**. They will refer you to the right state or territory agency.

Microscope images

Figure 46 Giemsa positive staining of enlarged cells within tissue section of spleen of fish with RSIVD



Note: Enlarged cells are characteristic of the disease.

Source: K Nakajima.

Further reading

CABI Invasive Species Compendium [Red Sea Bream Iridoviral Disease](#)

CEFAS International Database on Aquatic Animal Diseases [Red Sea Bream Iridoviral Disease](#)

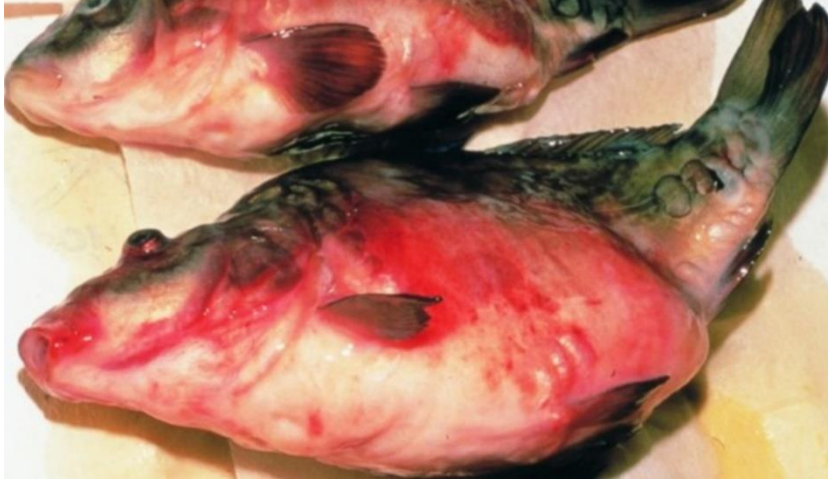World Organisation for Animal Health [Manual of diagnostic tests for aquatic animals](#)

Spring viraemia of carp (SVC)

Also known as infection with spring viraemia of carp virus (SVCV)

Exotic disease

Figure 47 SVC in common carp (*Cyprinus carpio*)



Note: Characteristic haemorrhagic skin, swollen stomach and exophthalmos (popeye).
Source: H J Schlotfeldt.

Signs of disease

Important: Animals with this disease may show one or more of these signs, but the pathogen may still be present in the absence of any signs.

Disease signs at the farm, tank or pond level are:

- mortality rates of 30 to 100%
- lethargy
- separation from shoal
- lethargic swimming
- accumulation of fish at the water inlet and sides of the pond.

Gross pathological signs are:

- exophthalmos (popeye)
- swollen abdomen and a protruding vent
- possibly a trailing white or yellowish faecal cast
- petechial (pinpoint) haemorrhages of skin, gills and eyes
- haemorrhages on skin and base of fins and around the vent
- darker body colour, with pale gills
- diffuse swelling and haemorrhage of internal organs and degeneration of gill lamellae
- ascites (fluid in abdominal cavity)
- intestines containing mucous instead of food.

Microscopic pathological signs are:

- liver hyperaemia and oedematous perivasculitis
- pericarditis and infiltration of the myocardium
- hyaline degeneration and vacuolation of the renal tubules, which are clogged with casts
- inflammatory and hyperaemic changes in all major organs.

Disease agent

SVC is caused by infection with spring viraemia of carp virus (SVCV), a rhabdovirus classified within the genus *Sprivirus*. SVCV is closely related to infectious haematopoietic necrosis virus (IHNV) and viral haemorrhagic septicaemia virus (VHSV).

Host range

SVCV infects a range of fish species and has been detected infecting amphibians (newts) imported from Asia into the USA, as well as on several non-fish carriers.

Table 18 Species known to be susceptible to SVCV

Common name	Scientific name
Bream ^a	<i>Abramis brama</i>
Bighead carp ^a	<i>Hypophthalmichthys nobilis</i>
Common carp and koi carp ^a	<i>Cyprinus carpio</i> (species most susceptible)
Common roach	<i>Rutilus rutilus</i>
Crucian carp ^a	<i>Carassius carassius</i>
Goldfish ^a	<i>Carassius auratus</i>
Grass carp ^a	<i>Ctenopharyngodon idella</i>
Guppy	<i>Poecilia reticulata</i>
Ide or orfe ^a	<i>Leuciscus idus</i>
Largemouth bass	<i>Micropterus salmoides</i>
Pike ^a	<i>Esox lucius</i>
Pumpkinseed	<i>Lepomis gibbosus</i>
Rainbow trout ^a	<i>Oncorhynchus mykiss</i>
Silver carp ^a	<i>Hypophthalmichthys molitrix</i>
Tench ^a	<i>Tinca tinca</i>
Wels catfish or sheatfish ^a	<i>Silurus glanis</i>
Zebrafish	<i>Danio rerio</i>

^a Naturally susceptible. Note: Other species have been shown to be experimentally susceptible.

Table 19 Non-fish carriers

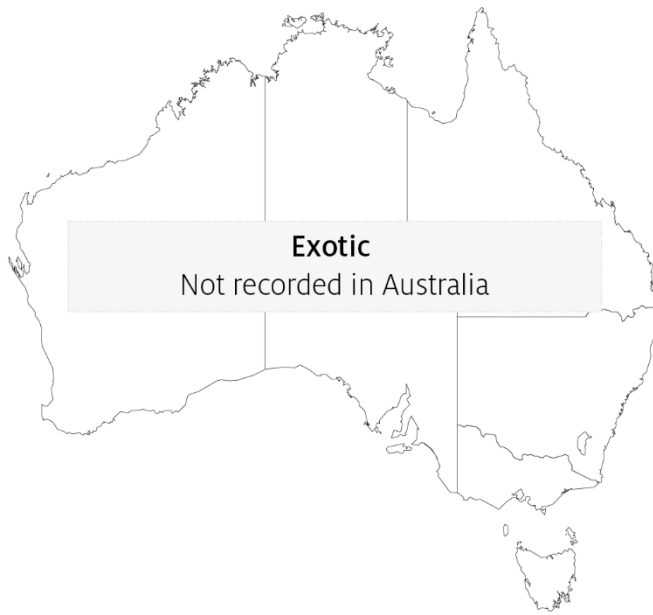Common name	Scientific name
Chinese fire belly newt	<i>Cynops orientalis</i>
Salamanders, newts and sirens	Order <i>Caudata</i>
Fish louse	<i>Argulus foliaceus</i>

Common name	Scientific name
Grey heron	<i>Ardea cinerea</i>
Leeches	<i>Piscicola</i> spp.
Piscivorous birds	Various genera and species

Presence in Australia

Exotic disease—not recorded in Australia.

Map 12 Presence of SVCV, by jurisdiction



Epidemiology

- SVC is very contagious among common carp.
- Clinical disease is linked closely to environmental disturbances.
- Mortality rate is usually less than 40% but can range from 5% to 100%, with younger fish less than 1 year old more susceptible.
- Fry are susceptible to disease at temperatures up to 23°C. However some SVCV strains from Asia replicate in-vitro at up to 28°C and can cause disease at water temperatures up to 26°C.
- Disease may also occur in older fish (greater than 1 year), usually when water temperatures are between 11°C and 17°C (associated with the stress of an abnormally cold spring in Europe, and possibly due to cold temperatures weakening the fish's immune system during the spring).
- Fish that survive SVC are presumed to carry the virus.
- Outbreaks are most likely to occur with increased stress levels, such as around the time of spawning, and coincide with increased levels of virus excreted with spawning fluids.
- Transmission of the virus to uninfected fish is horizontal, and the virus enters fish through the gills and skin.

- The virus enters the water in faeces, urine and spawning fluids. Transport of live infected fish, contaminated water and contaminated eggs of infected fish (suggestive of vertical transmission) contributes to disease spread.
- The virus also infects and causes disease in some salamanders.
- Blood-sucking parasites such as fish louse and leeches can transmit the virus from fish to fish. Piscivorous birds can also spread the disease.
- Stressors (such as overcrowding) can trigger an outbreak in apparently healthy populations.
- The virus can remain viable outside the host for 5 weeks in river water at 10°C or more than 6 weeks in pond mud at 4°C.

Differential diagnosis

The list of [similar diseases](#) in the next section refers only to the diseases covered by this field guide. Gross pathological signs may also be representative of diseases not included in this guide. Do not rely on gross signs to provide a definitive diagnosis. Use them as a tool to help identify the listed diseases that most closely account for the observed signs.

Similar diseases

Enteric redmouth disease (ERMD), enteric septicaemia of catfish, infection with *Aeromonas salmonicida*—atypical strains and koi herpesvirus disease (KHV).

Sample collection

Only trained personnel should collect samples. Using only gross pathological signs to differentiate between diseases is not reliable, and some aquatic animal disease agents pose a risk to humans. If you are not appropriately trained, phone your state or territory hotline number and report your observations. If you have to collect samples, the agency taking your call will advise you on the appropriate course of action. Local or district fisheries or veterinary authorities may also advise on sampling.

Emergency disease hotline

See something you think is this disease? Report it. Even if you're not sure.

Call the Emergency Animal Disease Watch Hotline on **1800 675 888**. They will refer you to the right state or territory agency.

Further reading

CEFAS International Database on Aquatic Animal Diseases [Spring Viraemia of Carp](#)

World Organisation for Animal Health [Manual of diagnostic tests for aquatic animals](#)

Tilapia lake virus (TiLV) disease

Also known as syncytial hepatitis of tilapia (SHT)

Exotic disease


Figure 48 Nile tilapia (*Oreochromis niloticus*) infected with TiLV



Note: Haemorrhagic skin lesion on flank.

Source: Worldfish

Figure 49 TiLV disease in Nile tilapia (*Oreochromis niloticus*) fingerlings



Note: Naturally infected fish exhibiting discolouration and scale protrusion.

Source: HT Dong.

Signs of disease

Important: Animals with this disease may show one or more of these signs, but the pathogen may still be present in the absence of any signs.

Disease signs at the farm, tank or pond level are:

- sudden unexpected increase in mortalities (greater than 2% per day) over several days during the summer months
- cumulative mortality up to 90% within 1 month of stocking fingerlings into freshwater or brackish water ponds
- high mortalities in 1 to 50g fish, lower mortalities (approximately 10%) in medium or large fish
- lethargy, loss of appetite, and respiratory distress (breathing at surface).

Gross pathological signs are:

- changes in body colour (darkening or lightening)
- skin erosion resulting in haemorrhagic dermal lesions
- scale protrusion
- exophthalmos (popeye) and opacity of the eye lens (cataract)
- abdominal distension (due to fluid or enlargement of spleen and other organs).

Microscopic pathological signs are:

- lesions in the brain including oedema, focal haemorrhages in the leptomeninges, and capillary congestion in both the white and grey matter and neural degeneration
- congestion of internal organs (liver, kidney, spleen, brain, gills) with foci of gliosis and perivascular cuffing of lymphocytes in the brain cortex, and melanomacrophage proliferation in liver and spleen
- formation of syncytia in the epithelium of hepatocytes (syncytial hepatitis of the liver)
- ocular inflammation including endophthalmitis and cataractous changes of the lens.

Disease agent

Tilapia lake virus disease, or syncytial hepatitis of tilapia (SHT), is caused by infection with tilapia lake virus (TiLV). TiLV is an enveloped, negative-sense, single-stranded RNA virus that has been classified as a relative of the *Orthomyxoviridae* family of viruses.

TiLV was first officially documented in Ecuador and Israel in 2013 and 2014, respectively. However, it is believed to have been responsible for mass mortalities in farmed tilapia in Israel since 2009. The disease agent has since been found in Thailand, Malaysia and the USA, and may have been spread to many other parts of Asia and Africa due to translocation of live tilapia for aquaculture.

Host range

Table 20 Species known to be susceptible to TiLV

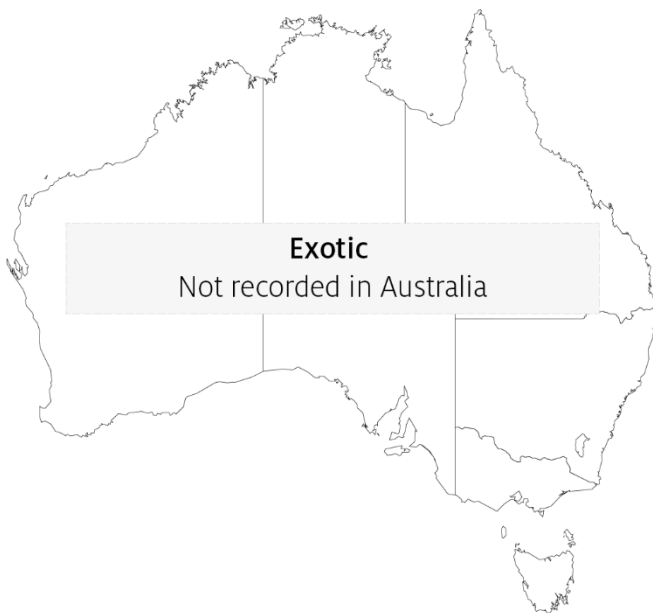Common name	Scientific name
Blue tilapia ^a	<i>Oreochromis aureus</i>
Cichlids	<i>Cichlidae, all species</i>
Malaysian red hybrid tilapia ^a	<i>Oreochromis niloticus</i> × <i>O. mossambicus</i>
Mango tilapia ^a	<i>Sarotherodon galilaeus</i>
Nile tilapia ^a	<i>Oreochromis niloticus</i>
Redbelly tilapia ^a	<i>Tilapia zilli</i>
Tilapias	Various genera and species
Tilapia hybrids ^a	<i>Oreochromis niloticus</i> × <i>O. aureus</i>
Tinfoil barb ^a	<i>Barbonymus schwanenfeldii</i>
Tvarnun simon ^a	<i>Tristramella simonis</i>

^a Naturally susceptible. Note: Other species have been shown to be experimentally susceptible.

Presence in Australia

Exotic disease—not recorded in Australia.

Map 13 Presence of TiLV, by jurisdiction



Epidemiology

- TiLV appears to cause disease mainly in tilapia and tilapia hybrids (*Oreochromis* spp., *Tilapia* spp.), but has also been detected causing disease in other wild cichlids (*Sarotherodon galilaeus*, *Tristramella* spp.) in Israel and tinfoil barb (*Barbonymus schwanenfeldii*) in Malaysia.
- TiLV viral particles are sensitive to organic solvents (ether and chloroform), due to their lipid membrane. Other orthomyxoviruses similar to TiLV can be inactivated by desiccation or heat at temperatures above 56°C for 5 minutes, but are stable in water for extended periods.
- Horizontal transmission (via the water and cohabitation) and vertical transmission have both been demonstrated. Transmission via cannibalism is likely.
- Duration of viral survival outside the host has not been determined.
- Tilapia that survive experimental infection show immunity to disease upon subsequent challenge.

Differential diagnosis

The list of [similar diseases](#) in the next section refers only to the diseases covered by this field guide. Gross pathological signs may also be representative of diseases not included in this guide. Do not rely on gross signs to provide a definitive diagnosis. Use them as a tool to help identify the listed diseases that most closely account for the observed signs.

Similar diseases

Infection with *Aphanomyces invadans* (EUS), infection with infectious spleen and kidney necrosis virus (ISKNV)-like viruses, red sea bream iridoviral disease (RSIVD) and viral encephalopathy and retinopathy (VER).

Sample collection

Only trained personnel should collect samples. Using only gross pathological signs to differentiate between diseases is not reliable, and some aquatic animal disease agents pose a risk to humans. If you are not appropriately trained, phone your state or territory hotline number and report your observations. If you have to collect samples, the agency taking your call will advise you on the appropriate course of action. Local or district fisheries or veterinary authorities may also advise on sampling.

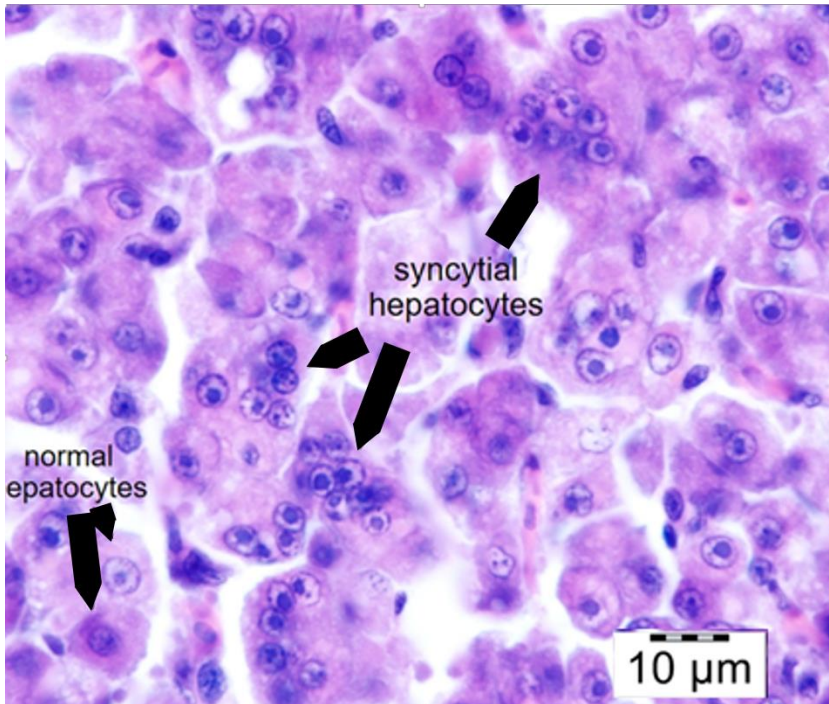
Emergency disease hotline

See something you think is this disease? Report it. Even if you're not sure.

Call the Emergency Animal Disease Watch Hotline on **1800 675 888**. They will refer you to the right state or territory agency.

Microscope images

Figure 50 Histopathology of liver of Nile tilapia (*Oreochromis niloticus*) infected with TiLV



Note: Multifocal areas of syncytial hepatitis. Scale bar = 10μm.

Source: HT Dong

Further reading

Jansen MD and Mohan CV 2017, *Tilapia lake virus (TiLV): Literature review*, Penang, Malaysia: CGIAR Research Program on Fish Agri-Food Systems

Network of Aquaculture Centres in Asia-Pacific [Tilapia Lake Virus \(TiLV\)—A novel orthomyxo-like virus](#)

Viral encephalopathy and retinopathy (VER)

Also known as viral nervous necrosis (VNN)

Figure 51 Darkened colouration in seven-band grouper (*Hyporthodus septemfasciatus*) with VER



Note: Dark groupers are diseased, light fish are normal. Change in colouration is an important indicator for VER (species differ in what colour change occurs; diseased barramundi become lighter).

Source: B Munday

Signs of disease

Important: Animals with this disease may show one or more of these signs, but the pathogen may still be present in the absence of any signs.

Disease signs at the farm, tank or pond level are:

- 50% to 100% cumulative mortality over a period of 48 hours to several weeks
- higher mortalities in larvae and juvenile fish (9 to 28 days old), although older fish (greater than 28 days) may also be affected
- anorexia
- abnormal swimming behaviours, including erratic, uncoordinated darting, spiral and/or looping swim pattern, corkscrew swimming
- fish resting belly-up (loss of equilibrium)
- hyperactivity
- sporadic protrusion of the head from the water.

Gross pathological signs are:

- colour change
 - affected fish may become lighter (such as larval barramundi) or darker (such as larval groupers), depending on the species affected and their environment
- blindness
- abrasions
- emaciation
- over-inflated swim bladder (the only significant internal gross pathological sign).

Microscopic pathological signs are:

- vacuolation of central nervous tissues, including retina
- intracytoplasmic inclusions in brain tissues as crystalline arrays or aggregates.

Disease agent

VER or VNN is a disease caused by a *Betanodavirus*, in the family *Nodaviridae*. In Australia, VER was formerly referred to as barramundi picorna-like virus.

Host range

Table 21 Species known to be susceptible to VER

Common name	Scientific name
Amberjack ^a	<i>Seriola dumerili</i>
Atlantic halibut ^a	<i>Hippoglossus hippoglossus</i>
Archer fish	<i>Toxotes chatareus</i>
Atlantic salmon ^b	<i>Salmo salar</i>
Australian bass ^a	<i>Macquaria novemaculeata</i>
Banded archerfish ^a	<i>Toxotes jaculatrix</i>
Barcoo grunter	<i>Scortum barcoo</i>
Barfin flounder ^a	<i>Verasper moseri</i>
Barramundi ^a	<i>Lates calcarifer</i>
Brown-marbled grouper ^a	<i>Epinephelus fuscoguttatus</i>
Chinese catfish ^a	<i>Silurus asotus</i>
Cobia ^a	<i>Rachycentron canadum</i>
Convict surgeonfish	<i>Acanthurus triostegus</i>
Coral trout	<i>Plectropomus leopardus</i>
Crimson snapper ^a	<i>Lutjanus erythropterus</i>
Common sole ^a	<i>Solea solea</i>
Dusky grouper	<i>Epinephelus marginatus</i>
Eastern freshwater cod ^a	<i>Maccullochella ikei</i>
Estuarine rockcod ^a	<i>Epinephelus tauvina</i>
Estuary catfish	<i>Cnidoglanis macrocephalus</i>

Common name	Scientific name
European eel ^a	<i>Anguilla anguilla</i>
European seabass ^a	<i>Dicentrarchus labrax</i>
Flounders ^a	<i>Paralichthyidae</i>
Giant grouper ^a	<i>Epinephelus lanceolatus</i>
Gilt-head sea bream ^a	<i>Sparus aurata</i>
Golden grey mullet ^a	<i>Chelon auratus</i>
Golden perch	<i>Macquaria ambigua</i>
Grouper and estuary cod ^a	<i>Epinephelus</i> spp.
Haddock ^a	<i>Melanogrammus aeglefinus</i>
Humpback grouper ^a	<i>Cromileptes altivelis</i>
Japanese flounder ^a	<i>Paralichthys olivaceus</i>
Japanese parrotfish ^a	<i>Oplegnathus fasciatus</i>
Japanese seabass ^a	<i>Lateolabrax japonicus</i>
Japanese tilefish	<i>Branchiostegus japonicus</i>
Longtooth grouper ^a	<i>Epinephelus bruneus</i>
Luderick	<i>Girella tricuspidata</i>
Macquarie perch	<i>Macquaria australasica</i>
Malabar grouper ^a	<i>Epinephelus malabaricus</i>
Mangrove jack ^a	<i>Lutjanus argentimaculatus</i>
Milkfish	<i>Chanos chanos</i>
Mullet ^a	<i>Mugilidae</i> , all species
Mulloway	<i>Argyrosomus japonicus</i>
Murray cod	<i>Maccullochella peelii</i>
Narrowstripe cardinalfish	<i>Pristiapogon exostigma</i>
Nile tilapia	<i>Oreochromis niloticus</i>
Orange-spotted grouper ^a	<i>Epinephelus coioides</i>
Permit ^a	<i>Trachinotus falcatus</i>
Red drum ^a	<i>Sciaenops ocellatus</i>
Red mullet	<i>Mullus barbatus</i>
Red-spotted grouper ^a or Hong Kong grouper	<i>Epinephelus akaara</i>
Russian sturgeon ^a	<i>Acipenser gueldenstaedtii</i>
Samson fish	<i>Seriola hippos</i>
Senegalese sole ^a	<i>Solea senegalensis</i>
Seven-band grouper ^a	<i>Hyporthodus septemfasciatus</i>
Shi drum ^a	<i>Umbrina cirrosa</i>
Silver perch	<i>Bidyanus bidyanus</i>
Silver trevally ^a	<i>Pseudocaranx dentex</i>
Six bar grouper	<i>Epinephelus sexfasciatus</i>

Common name	Scientific name
Sleepy cod	<i>Oxyeleotris lineolata</i>
Snubnose dart ^a	<i>Trachinotus blochii</i>
Spotted coral grouper	<i>Plectropomus maculatus</i>
Spotted knifejaw ^a	<i>Oplegnathus punctatus</i>
Spotted wolffish	<i>Anarhichas minor</i>
Striped trumpeter ^a	<i>Latris lineata</i>
Thread-sail filefish ^a	<i>Stephanolepis cirrhifer</i>
Tiger grouper hybrid	<i>Epinephelus fuscoguttatus</i> × <i>E. lanceolatus</i>
Tiger puffer ^a	<i>Takifugu rubripes</i>
Tilapias	various genera and species
Turbot ^a	<i>Scophthalmus maximus</i>
White grouper ^a	<i>Epinephelus aeneus</i>
White seabass ^a	<i>Atractoscion nobilis</i>
Winter flounder ^a	<i>Pseudopleuronectes americanus</i>
Winter whiting	<i>Sillago maculata</i>
Yellowfin bream	<i>Acanthopagrus australis</i>
Yellowtail kingfish	<i>Seriola lalandi</i>

a Naturally susceptible. **b** Experimentally susceptible to disease via intraperitoneal injection. Note: Other species have been shown to be experimentally susceptible.

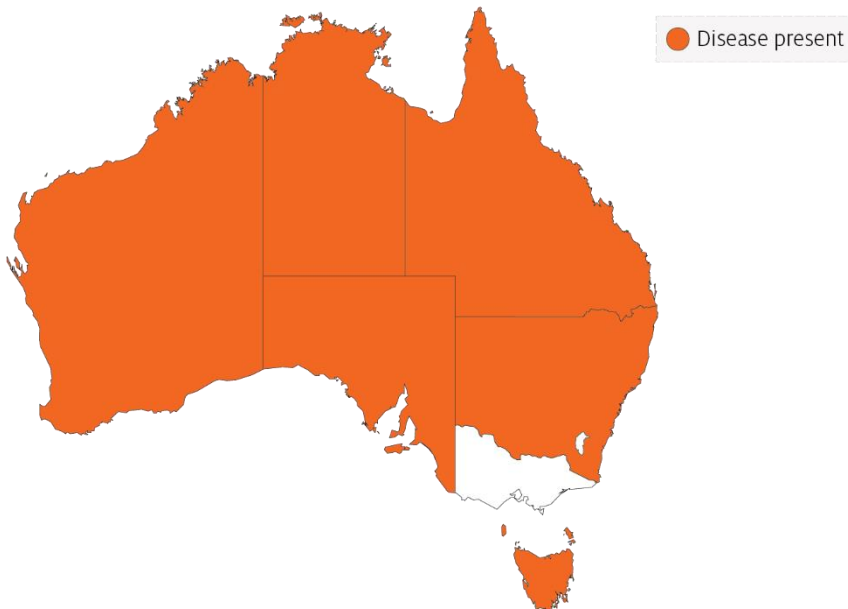
Table 22 Non-fish carriers

Common name	Scientific name
Molluscs	Various genera and species
Polychaetes	<i>Nereis</i> spp.

Presence in Australia

VER has been officially reported from New South Wales, the Northern Territory, Queensland, South Australia, Tasmania and Western Australia. It is primarily reported to affect larvae or fry.

Map 14 Presence of VER, by jurisdiction



Epidemiology

- VER has occurred in at least 70 species of marine fish from 16 families, and has been diagnosed in all inhabited continents.
- Most fish are affected as larvae or juveniles. However, in recent years, mortalities have occurred in older fish up to harvest size, particularly in European seabass, groupers (*Epinephelus* spp.) and Atlantic halibut. Disease incidence in the groupers and seabass has been associated with high water temperatures.
- Susceptibility and mortality are age dependent. Onset of clinical disease in younger fish of some species results in higher mortality.
- Batches of barramundi larvae for aquaculture are now routinely screened for this disease in Australia.
- The incubation period for the disease in barramundi is 4 days, with typical disease onset 9 to 28 days after hatching, rarely occurring in older fish (50 to 60 days old). In silver trevally, disease onset is 1 day after hatching.
- Transmission is believed to occur both horizontally through the water column (via mouth, gills and skin), and vertically (parent to offspring). The rate of transmission may be influenced by stressors, including handling, repeated spawning, high stocking densities, high ambient temperature and virulence of the particular *Betanodavirus* strain. Sand worms of the family *Nereidae*, genus *Nereis*, and bivalves collected in proximity to infected farms have had positive detection of *Betanodavirus*.

- The virus can survive for 1 year in the right environmental conditions (pH 2 to 9 and 15°C) and can persist subclinically in infected live fish. Therefore, fish products and by-products may facilitate the spread of virus to unaffected areas.
- Cumulative mortality at 1 month is typically 50% to 100% in barramundi and 100% in silver trevally. In Australian hatcheries, 100% mortality in less than 3 days in larval fish is typical.

Differential diagnosis

The list of [similar diseases](#) in the next section refers only to the diseases covered by this field guide. Gross pathological signs may also be representative of diseases not included in this guide. Do not rely on gross signs to provide a definitive diagnosis. Use them as a tool to help identify the listed diseases that most closely account for the observed signs.

Similar diseases

Grouper iridoviral disease and Tilapia lake virus (TiLV) disease.

Sample collection

Only trained personnel should collect samples. Using only gross pathological signs to differentiate between diseases is not reliable, and some aquatic animal disease agents pose a risk to humans. If you are not appropriately trained, phone your state or territory hotline number and report your observations. If you have to collect samples, the agency taking your call will advise you on the appropriate course of action. Local or district fisheries or veterinary authorities may also advise on sampling.

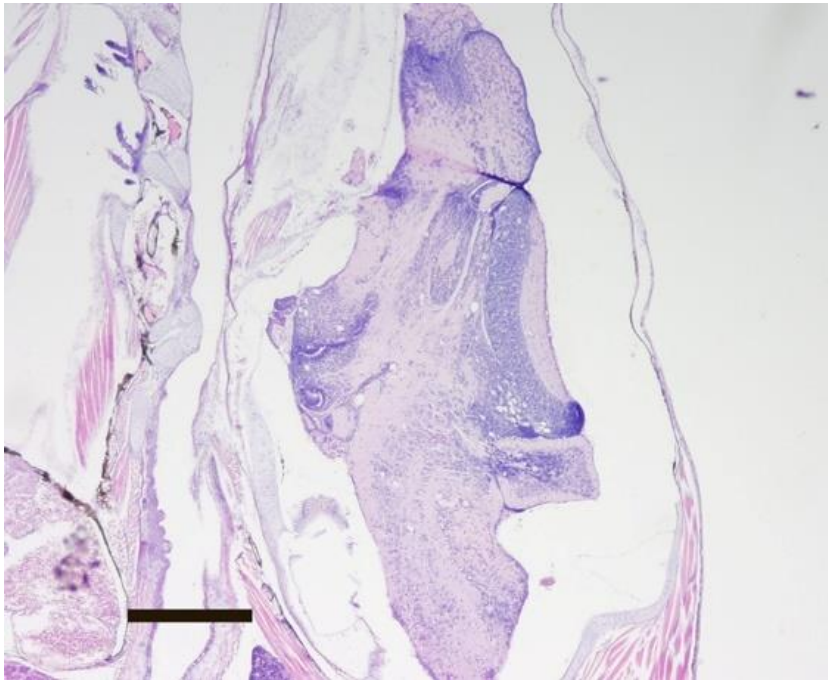
Emergency disease hotline

See something you think is this disease? Report it. Even if you're not sure.

Call the Emergency Animal Disease Watch Hotline on **1800 675 888**. They will refer you to the right state or territory agency.

Microscope images

Figure 52 Transverse histological section through head of larval (20 day old) barramundi (*Lates calcarifer*) with VER



Note: Vacuoles associated with VER infection are readily visible in the brain. Haematoxylin and eosin stain. 20x magnification, scale bar = 300µm

Source: B Jones

Further reading

CEFAS International Database on Aquatic Animal Diseases [Viral Encephalopathy and Retinopathy](#)

Department of Agriculture [AQUAVETPLAN disease strategy manual: Viral encephalopathy and retinopathy](#)

World Organisation for Animal Health [Manual of diagnostic tests for aquatic animals](#)

Viral haemorrhagic septicaemia (VHS)

Also known as infection with viral haemorrhagic septicaemia virus (VHSV)

Exotic disease

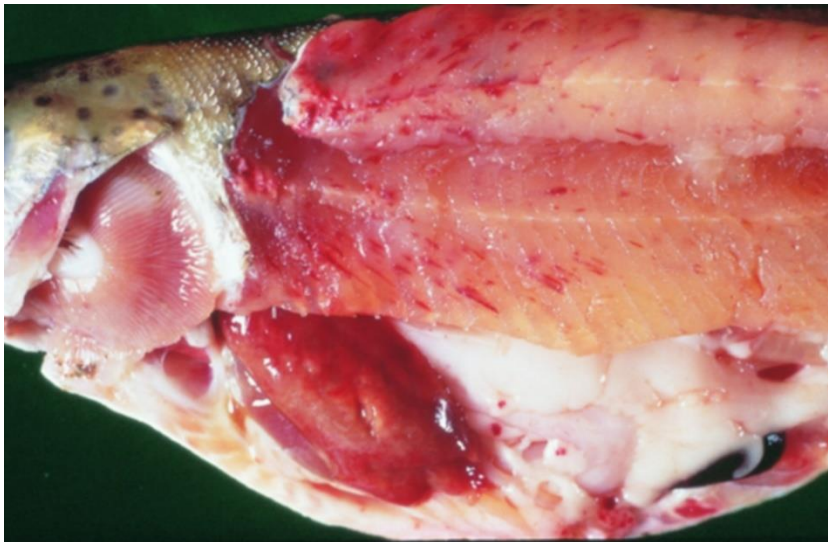
Figure 53 VHS in rainbow trout (*Oncorhynchus mykiss*)



Note: Swollen stomach and exophthalmos (popeye).

Source: T Håstein

Figure 54 Internal organs of rainbow trout (*Oncorhynchus mykiss*) with VHS



Note: Pale colour of stomach region, pinpoint haemorrhages in fillet and fatty tissue and pale gills.

Source: T Håstein

Signs of disease

Important: Animals with this disease may show one or more of these signs, but the pathogen may still be present in the absence of any signs.

Disease signs at the farm, tank or pond level are:

- acute infection
 - rapid onset of high mortality
 - lethargic swimming
 - separation from shoal
 - loss of appetite
 - crowding at pond edges.
- chronic infection
 - significant cumulative mortality (protracted)
 - uncoordinated swimming (ataxia) with rotating movement around body axis (spinning).
- neurological form
 - low mortality
 - severe abnormal swimming behaviour (flashing and spiralling).

Gross pathological signs are:

- general
 - exophthalmos (popeye)
 - haemorrhages under the skin, around the base of pectoral and pelvic fins and in the eyes
 - swollen abdomen
 - pale gills, with or without petechial (pinpoint) haemorrhages.
- acute infection
 - slight darkening of the body colour
 - exophthalmos (popeye)
 - bleeding around the eyes
 - bleeding under the skin around the base of the pectoral and pelvic fins
 - skin ulceration
 - swollen abdomen with ascites (fluid in the abdominal cavity)
 - pale gills with petechial (pinpoint) haemorrhages
 - petechial (pinpoint) haemorrhages in the fatty tissue, intestine, gonads, liver, swim bladder and muscle
 - dark-red kidneys.
- chronic infection
 - often an absence of external signs
 - intense darkening of the skin
 - exophthalmos (popeye)
 - pale gills (anaemic)

- pale abdominal organs
- pale and mottled liver (evidence of haemorrhages on surface)
- pale gastrointestinal tract that is empty of food.

Microscopic pathological signs are:

- accumulation of erythrocytes in skeletal muscle fibres
- extensive focal necrosis in the liver, kidney and spleen
- VHS virus-positive endothelial cells in vascular system evident from immunohistochemistry.

Disease agent

VHS is caused by infection with viral haemorrhagic septicaemia virus (VHSV). VHSV is a rhabdovirus classified within the genus *Novirhabdovirus*, closely related to infectious haematopoietic necrosis virus (IHNV) and spring viraemia of carp virus (SVCV).

Several genogroups or genotypes of the virus have been identified from different environments in different parts of the world:

- type I, continental Europe—freshwater group, trout farms (highly pathogenic to rainbow trout)
- type II, European marine strain (Baltic Sea)—marine strain affecting wild and cultured marine and freshwater species (has low pathogenicity in rainbow trout)
- type III, north Atlantic marine group (Flemish Cap to Norway, including North Sea near the British Isles)
- type IVa, west coast of North America and east Asian group—marine group affecting a range of free-living marine and cultured species (highly pathogenic in Pacific herring; rainbow trout appear refractory to infection with this genotype)
- type IVb, Great Lakes region-significant mortalities in wild freshwater species in the Great Lakes of North America

Host range

VHSV has been isolated from a broad range of marine and freshwater fish in Europe and the north Pacific, including cod, sprats, herring, haddock and turbot.

Table 23 Species known to be susceptible to VHSV

Common name	Scientific name
American eel	<i>Anguilla rostrata</i>
Armoured weaselfish	<i>Hoplobrotula armata</i>
Atlantic cod	<i>Gadus morhua</i>
Atlantic halibut	<i>Hippoglossus hippoglossus</i>
Atlantic herring	<i>Clupea harengus</i>
Atlantic salmon	<i>Salmo salar</i>
Black crappie	<i>Pomoxis nigromaculatus</i>
Black sea bream or black porgy	<i>Acanthopagrus schlegelii</i>
Bluegill	<i>Lepomis macrochirus</i>

Common name	Scientific name
Blue whiting	<i>Micromesistius poutassou</i>
Bluntnose minnow	<i>Pimephales notatus</i>
Brook trout	<i>Salvelinus fontinalis</i>
Brown bullhead	<i>Ameiurus nebulosus</i>
Brown trout	<i>Salmo trutta</i>
Burbot ^a	<i>Lota lota</i>
Channel catfish	<i>Ictalurus punctatus</i>
Chinook salmon	<i>Oncorhynchus tshawytscha</i>
Chub mackerel	<i>Scomber japonicus</i>
Coho salmon	<i>Oncorhynchus kisutch</i>
Dab	<i>Limanda limanda</i>
Eels	<i>Anguillidae</i> , all species
Emerald shiner	<i>Notropis atherinoides</i>
English sole	<i>Parophrys vetulus</i>
Eulachon ^a	<i>Thaleichthys pacificus</i>
European eel	<i>Anguilla anguilla</i>
European seabass	<i>Dicentrarchus labrax</i>
European sprat	<i>Sprattus sprattus</i>
Flounder	<i>Platichthys flesus</i>
Fourbeard rockling	<i>Enchelyopus cimbrius</i>
Freshwater drum ^a	<i>Aplodinotus grunniens</i>
Gilt-head sea bream	<i>Sparus aurata</i>
Gizzard shad	<i>Dorosoma cepedianum</i>
Golden trout	<i>Oncorhynchus aguabonita</i>
Grayling	<i>Thymallus thymallus</i>
Greenland halibut	<i>Reinhardtius hippoglossoides</i>
Haddock	<i>Melanogrammus aeglefinus</i>
Hairtail	<i>Trichiurus lepturus</i>
Hong Kong grouper	<i>Epinephelus akaara</i>
Hybrid (rainbow trout × coho salmon)	<i>Oncorhynchus mykiss</i> × <i>O. kisutch</i>
Iberian nase	<i>Pseudochondrostoma polylepis</i>
Japanese eel	<i>Anguilla japonica</i>
Japanese flounder ^a	<i>Paralichthys olivaceus</i>
Japanese yellowtail	<i>Seriola quinqueradiata</i>
Korean flounder	<i>Glyptocephalus stelleri</i>
Lake trout	<i>Salvelinus namaycush</i>
Lake whitefish	<i>Coregonus clupeaformis</i>
Largemouth bass	<i>Micropterus salmoides</i>

Common name	Scientific name
Lesser argentine	<i>Argentina sphyraena</i>
Sea Mullet	<i>Mugil cephalus</i>
Mummichog ^a	<i>Fundulus heteroclitus</i>
Muskellunge ^a	<i>Esox masquinongy</i>
Norway pout	<i>Trisopterus esmarkii</i>
Pacific cod	<i>Gadus macrocephalus</i>
Pacific hake ^a	<i>Merluccius productus</i>
Pacific herring ^a	<i>Clupea pallasii</i>
Pacific salmon	<i>Oncorhynchus</i> spp.
Pacific sand eel	<i>Ammodytes personatus</i>
Pacific sand lance	<i>Ammodytes hexapterus</i>
Pacific sardine ^a	<i>Sardinops sagax</i>
Pacific tomcod	<i>Microgadus proximus</i>
Pike ^a	<i>Esox lucius</i>
Plaice	<i>Pleuronectes platessa</i>
Poor cod	<i>Trisopterus minutus</i>
Pumpkinseed	<i>Lepomis gibbosus</i>
Rainbow trout ^a	<i>Oncorhynchus mykiss</i>
River lamprey	<i>Lampetra fluviatilis</i>
Rock bass	<i>Ambloplites rupestris</i>
Rockfish	<i>Sebastes</i> spp.
Round goby ^a	<i>Neogobius melanostomus</i>
Sablefish ^a	<i>Anoplopoma fimbria</i>
Sand eel	<i>Ammodytes</i> spp.
Sand goby	<i>Pomatoschistus minutus</i>
Senegalese sole	<i>Solea senegalensis</i>
Shiner perch	<i>Cymatogaster aggregata</i>
Shortfin eel	<i>Anguilla australis</i>
Shorthead redhorse	<i>Moxostoma macrolepidotum</i>
Silver pomfret	<i>Pampus argenteus</i>
Silver redhorse	<i>Moxostoma anisurum</i>
Smallmouth bass ^a	<i>Micropterus dolomieu</i>
Snapper	<i>Chrysophrys auratus</i>
Splake (lake trout × brook trout)	<i>Salvelinus namaycush</i> × <i>S. fontinalis</i>
Spottail shiner	<i>Notropis hudsonius</i>
Striped bass	<i>Morone saxatilis</i>
Surf smelt ^a	<i>Hypomesus pretiosus</i>
Three-spined stickleback	<i>Gasterosteus aculeatus</i>

Common name	Scientific name
Trout-perch	<i>Percopsis omiscomaycus</i>
Tubesnout	<i>Aulorhynchus flavidus</i>
Turbot ^a	<i>Scophthalmus maximus</i>
Walleye pollock or Alaska pollock ^a	<i>Gadus chalcogramma</i>
White bass	<i>Morone chrysops</i>
Whitefish (Muksun)	<i>Coregonus muksun</i>
Whitefish (Peled)	<i>Coregonus peled</i>
White perch	<i>Morone americana</i>
Whiting	<i>Merlangius merlangus</i>
Yellowback seabream	<i>Evynnis tumifrons</i>
Yellow perch ^a	<i>Perca flavescens</i>

^a Naturally susceptible. Note: Other species have been shown to be experimentally susceptible.

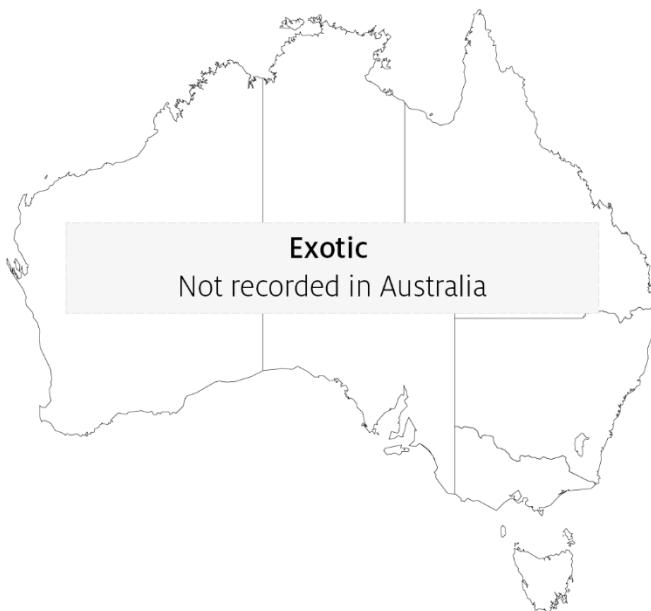Table 24 Non-fish carriers

Common name	Scientific name
Leeches	<i>Piscicola</i> spp.
Piscivorous birds	Various genera and species

Presence in Australia

Exotic disease—not recorded in Australia.

Map 15 Presence of VHS, by jurisdiction



Epidemiology

- Variant strains of VHSV are responsible for disease in different geographical locations.
- Marine and freshwater species are susceptible to VHSV infection. Younger fish are generally more susceptible to disease.
- Rainbow trout appear to be less susceptible to infection by marine strains of the virus.
- Water temperatures in an outbreak are generally near 10°C. At water temperatures between 15°C and 18°C, the disease generally takes a shorter course with a modest accumulated mortality, but transmission can occur at water temperatures up to 22°C. Mortality and morbidity have rarely been documented when water temperatures are above 18°C, although VHS virus genotype IV has caused at least one fish kill at 20 to 22°C, and some isolates can replicate in vitro at temperatures up to 25°C.
- Transmission is horizontal directly through the water, from virus shed in faeces, urine (predominantly) and sexual fluids of clinically infected or carrier fish. The virus can also be spread by birds that have consumed infected fish, via blood-feeding vectors such as leeches, and on equipment that has been in contact with water from infected fish. The virus gains entry via the gills, skin wounds, oral exposure (predation) and possibly through the skin.
- Once infected, survivors are lifelong carriers of the virus, with intermittent shedding. Stressors (including overcrowding, extreme temperatures and overfeeding) will greatly reduce an animal's resistance to infection.
- Mortality rate can range from 10% to 80%, depending on the VHSV isolate, environmental variables (temperature), age, species, route of exposure and presence of additional stressors. The highest mortality rates occur with acute infection, and lowest mortality rates in the neurological form.
- VHSV is thought to have existed in the marine environment before its apparent transfer to fresh water, where it first became virulent in trout.
- It has been suggested that the European freshwater strains of VHSV originated from fish in the northern Pacific and Atlantic oceans. The mechanism of transfer was possibly through the feeding of marine fish to cultured freshwater species.

Differential diagnosis

The list of [similar diseases](#) in the next section refers only to the diseases covered by this field guide. Gross pathological signs may also be representative of diseases not included in this guide. Do not rely on gross signs to provide a definitive diagnosis. Use them as a tool to help identify the listed diseases that most closely account for the observed signs.

Similar diseases

Enteric red mouth disease (ERMD), epizootic haematopoietic necrosis (EHN), infection with *Aphanomyces invadans* (EUS), infectious haematopoietic necrosis (IHN), infectious pancreatic necrosis (IPN) and whirling disease.

Sample collection

Only trained personnel should collect samples. Using only gross pathological signs to differentiate between diseases is not reliable, and some aquatic animal disease agents pose a risk to humans. If you are not appropriately trained, phone your state or territory hotline number and report your observations. If you have to collect samples, the agency taking your call will advise you on the appropriate course of action. Local or district fisheries or veterinary authorities may also advise on sampling.

Emergency disease hotline

See something you think is this disease? Report it. Even if you're not sure.

Call the Emergency Animal Disease Watch Hotline on **1800 675 888**. They will refer you to the right state or territory agency.

Further reading

CABI Invasive Species Compendium [Viral haemorrhagic septicaemia](#)

Department of Agriculture [AQUAVETPLAN disease strategy manual: Viral haemorrhagic septicaemia](#)

World Organisation for Animal Health [Manual of diagnostic tests for aquatic animals](#)

Bacterial diseases of finfish

Bacterial kidney disease (BKD)

Also known as infection with *Renibacterium salmoninarum*

Exotic disease

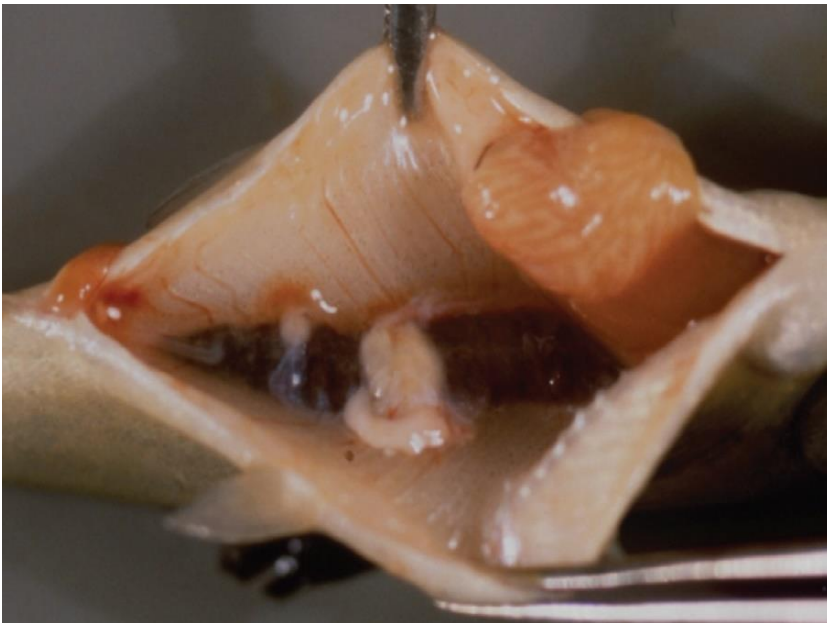
Figure 55 Ventral view of adult chinook salmon (*Oncorhynchus tshawytscha*) infected with *Renibacterium salmoninarum*



Note: Dermatitis (spawning rash) typical of BKD on bottom of fish.

Source: R Pascho and D Elliott

Figure 56 Kidneys of Juvenile chinook salmon (*Oncorhynchus tshawytscha*) affected by BKD



Note: Multiple kidney lesions.

Source: R Pascho and C O'Farrell

Signs of disease

Important: Animals with this disease may show one or more of these signs, but the pathogen may still be present in the absence of any signs.

Disease signs at the farm, tank or pond level are:

- lethargy
- Increasing mortality.

Gross pathological signs are:

- exophthalmos (popeye)
- swollen abdomen and skin blisters (spawning rash) or shallow ulcers (remnants of ruptured blisters)
- darkening of skin and pale gills
- haemorrhages at the base of the fins or at the vent
- creamy-white, granulomatous, nodular lesions in the kidney and sometimes in the liver and spleen, which may be encapsulated
- ascites (fluid in the abdominal cavity)
- haemorrhages on the abdominal wall and in the viscera
- diffuse, white membranous layer on one or more internal organs
- enlarged spleen
- cystic cavities in skeletal muscle.

Microscopic pathological signs are:

- focal or diffuse granulomatous reaction in the kidneys, liver and spleen
- small, rod-shaped bacteria (*Renibacterium salmoninarum*) in histological sections of skin lesions.

Disease agent

BKD is caused by infection with *R. salmoninarum*, a member of the family *Micrococcaceae*. BKD is a slow, progressive and frequently fatal infection of cultured and wild salmonids in both fresh and marine waters.

Host range

Table 25 Species of salmonid fish known to be susceptible to BKD

Common name	Scientific name
Arctic char	<i>Salvelinus alpinus</i>
Atlantic salmon ^a	<i>Salmo salar</i>
Black sea salmon	<i>Salmo labrax</i>
Brook trout ^a	<i>Salvelinus fontinalis</i>
Brown trout ^a	<i>Salmo trutta</i>
Chinook salmon ^a	<i>Oncorhynchus tshawytscha</i>
Chum salmon	<i>Oncorhynchus keta</i>
Coho salmon ^a	<i>Oncorhynchus kisutch</i>
Cutthroat trout ^a	<i>Oncorhynchus clarkii</i>
Danube salmon ^a	<i>Hucho hucho</i>
Masu salmon ^a	<i>Oncorhynchus masou</i>
Pink salmon ^a	<i>Oncorhynchus gorbuscha</i>
Rainbow trout ^a	<i>Oncorhynchus mykiss</i>

^a Naturally susceptible. Note: Other species have been shown to be experimentally susceptible.

Table 26 Species of non-salmonid fish known to be susceptible to BKD

Common name	Scientific name
Ayu	<i>Plecoglossus altivelis</i>
Burbot	<i>Lota lota</i>
Common shiner	<i>Luxilus cornutus</i>
Fathead minnow	<i>Pimephales promelas</i>
Grayling	<i>Thymallus thymallus</i>
Pacific herring	<i>Clupea pallasii</i>
Sablefish	<i>Anoplopoma fimbria</i>
Sea lamprey	<i>Petromyzon marinus</i>
Shiner perch	<i>Cymatogaster aggregata</i>

Table 27 Non-salmonid carriers

Common name	Scientific name
Bartail flathead	<i>Platycephalus indicus</i>
Greenling	<i>Hexagrammos otakii</i>
Japanese scallop	<i>Patinopecten yessoensis</i>

Presence in Australia

Exotic disease—not recorded in Australia.

Map 16 Presence BKD, by jurisdiction



Epidemiology

- The causative bacterium is likely to persist only within salmonids and not in the environment. However, as *R. salmoninarum* is often endemic in wild salmon populations, hatcheries can be constantly exposed to bacteria shed into the water by wild fish upstream.
- Other non-salmonid species have been demonstrated susceptible to infection with *R. salmoninarum*, but only when raised in proximity to highly infected salmonids.
- The bacterium is transmitted both horizontally (between fish via the water) and vertically (parent to offspring via eggs). Surface disinfection of eggs does not prevent vertical transmission.
- Advanced infection becomes apparent only after the first year of the fish's life.
- Coho (*Oncorhynchus kisutch*) and chinook (*O. tshawytscha*) salmon are the most important worldwide sources of infection.

Differential diagnosis

The list of [similar diseases](#) in the next section refers only to the diseases covered by this field guide. Gross pathological signs may also be representative of diseases not included in this guide. Do not rely on gross signs to provide a definitive diagnosis. Use them as a tool to help identify the listed diseases that most closely account for the observed signs.

Similar diseases

Piscirickettsiosis and viral haemorrhagic septicaemia (VHS).

Sample collection

Only trained personnel should collect samples. Using only gross pathological signs to differentiate between diseases is not reliable, and some aquatic animal disease agents pose a risk to humans. If you are not appropriately trained, phone your state or territory hotline number and report your observations. If you have to collect samples, the agency taking your call will advise you on the appropriate course of action. Local or district fisheries or veterinary authorities may also advise on sampling.

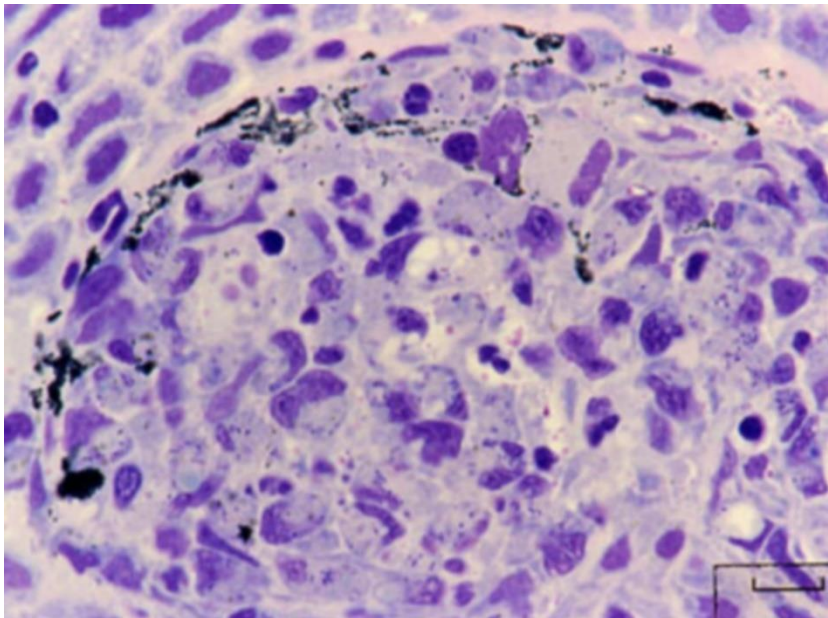
Emergency disease hotline

See something you think is this disease? Report it. Even if you're not sure.

Call the Emergency Animal Disease Watch Hotline on **1800 675 888**. They will refer you to the right state or territory agency.

Microscope images

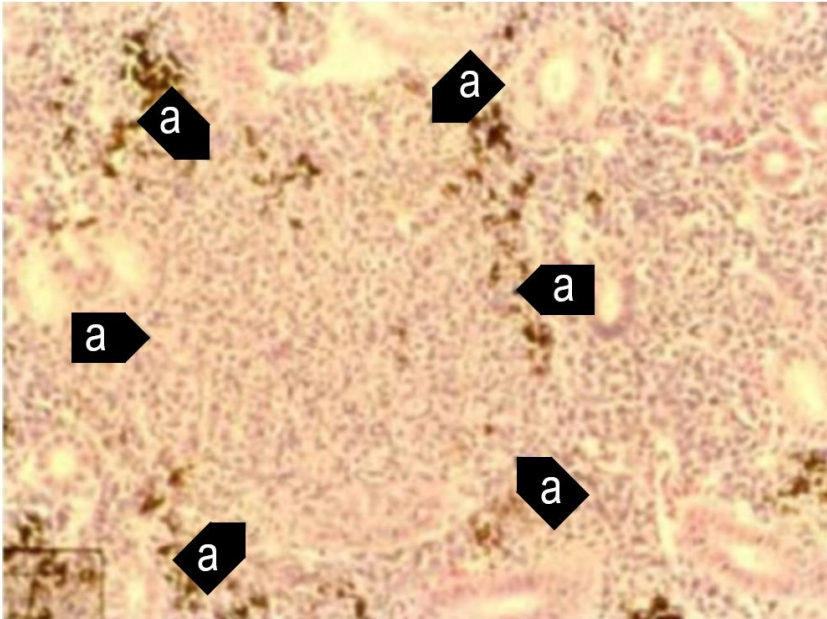
Figure 57 Histological section of skin lesion of juvenile chinook salmon (*Oncorhynchus tshawytscha*) infected with *Renibacterium salmoninarum*



Note: Most of the small, rod-shaped *R. salmoninarum* are visible within the cytoplasm of macrophages. In this Giemsa-stained preparation, bacteria are purple–blue and melanin granules are black.

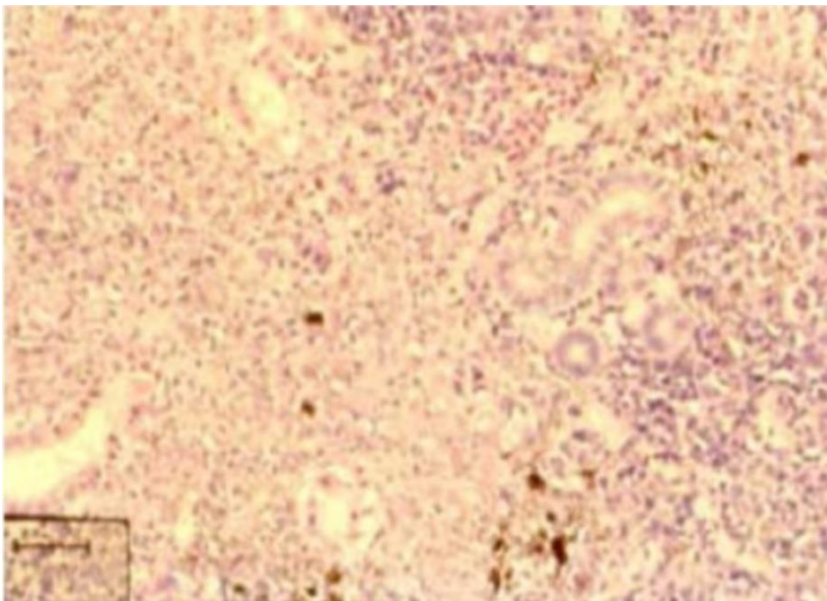
Source: R Pascho

Figure 58 Histological section of granulomas of juvenile chinook salmon (*Oncorhynchus tshawytscha*) affected by BKD



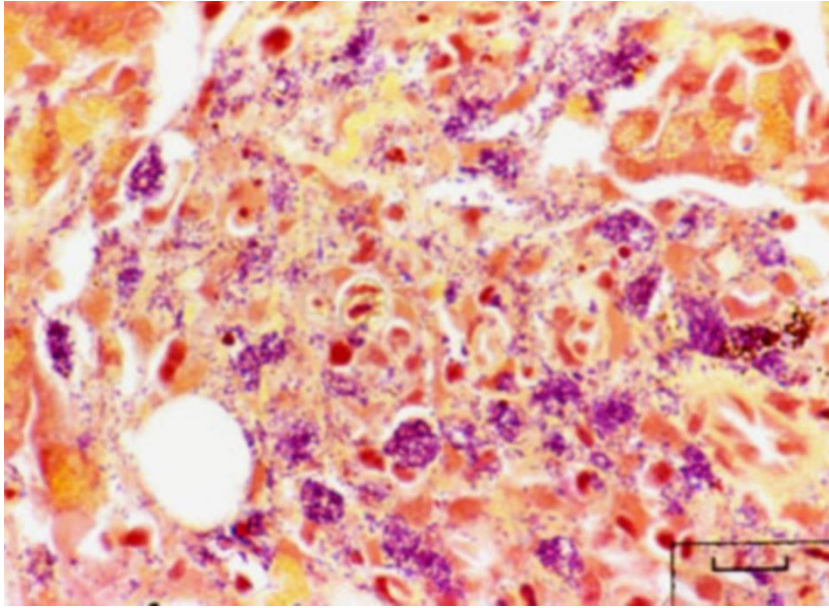
Note: Focal granulomatous inflammation (a).
Source: R Pascho and C O'Farrell

Figure 59 Histological section of granulomas of juvenile chinook salmon (*Oncorhynchus tshawytscha*) affected by BKD



Note: Diffuse granulomatous inflammation.
Source: R Pascho and C O'Farrell

Figure 60 Gram-stained histological section of pancreatic tissue of juvenile chinook salmon (*Oncorhynchus tshawytscha*) with systemic BKD



Note: Gram-positive (purple–blue) cells of *R. salmoninarum* are present extracellularly and intracellularly within macrophages, in contrast to brown–black melanin granules.

Source: R Pascho

Further reading

CABI Invasive Species Compendium [‘Renibacterium salmoninarum’](#)

CEFAS International Database on Aquatic Animal Diseases [Bacterial Kidney Disease](#)
[\(‘Renibacterium salmoninarum’\)](#)

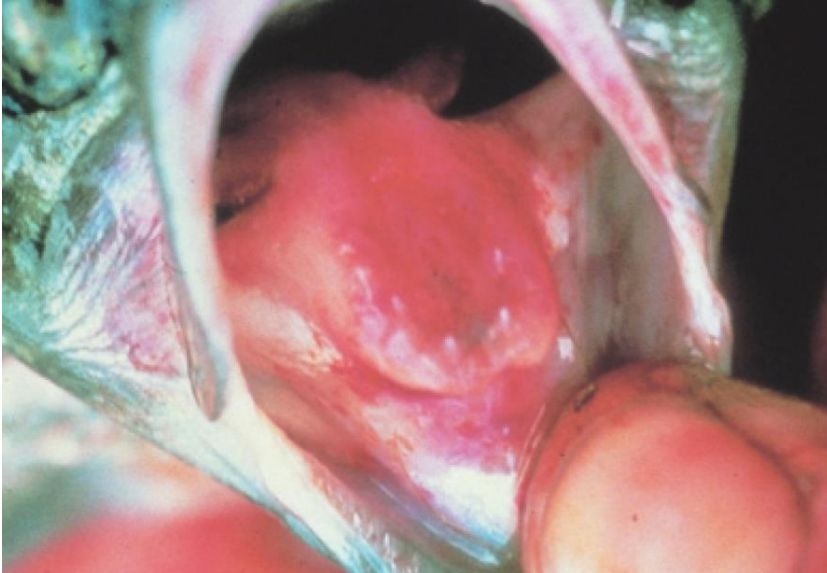
World Organisation for Animal Health [Manual of diagnostic tests for aquatic animals](#)

Enteric red mouth disease (ERMD)

Also known as infection with *Yersinia ruckeri*

Exotic disease

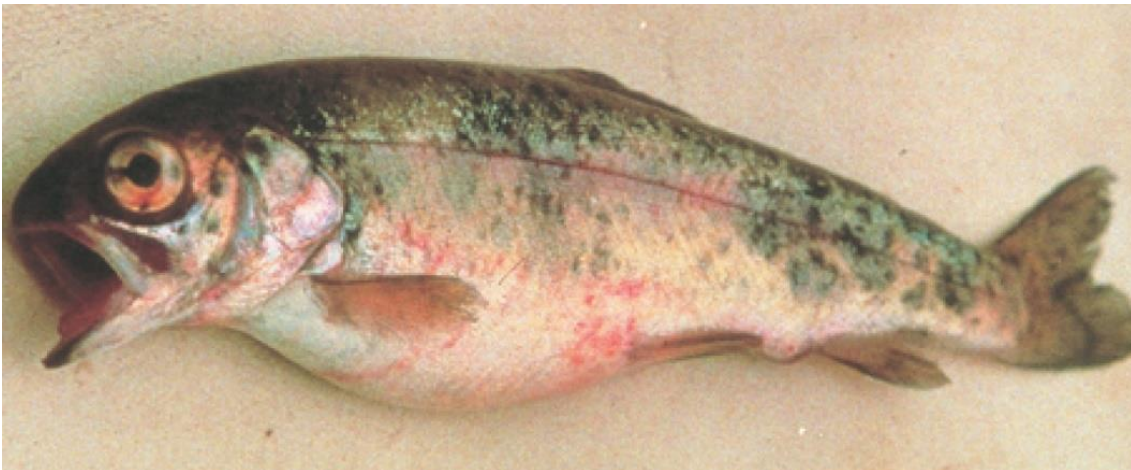Figure 61 Characteristic red mouth from ERMD in rainbow trout (*Oncorhynchus mykiss*)



Note: Reddened mouth and tongue.

Source: HJ Schlotfeldt

Figure 62 ERMD in rainbow trout (*Oncorhynchus mykiss*)



Note: Skin and eye haemorrhages, and swollen abdomen.

Source: HJ Schlotfeldt

Signs of disease

Important: Animals with this disease may show one or more of these signs, but the pathogen may still be present in the absence of any signs.

Disease signs at the farm, tank or pond level are:

- separation from other fish
- occasional nervous signs
- acute infections in fingerlings (fish of all ages may be affected, usually with sustained low-level mortalities).

Gross pathological signs are:

- dark body colour (seen in atypical infections)
- haemorrhages at base of paired fins and vent
- reddening (subcutaneous haemorrhages) of gill cover, corners of mouth, gums, palate and tongue
- exophthalmos (popeye) and orbital haemorrhages
- loss of appetite
- swollen abdomen
- ascites (fluid in the abdominal cavity)
- petechial (pinpoint) haemorrhages may occur on the surfaces of the liver, pancreas, pyloric caeca, swim bladder and in the lateral musculature
- enlarged, friable spleen is often almost black in colour
- inflamed lower intestine containing thick yellow fluid.

Microscopic pathological signs are:

- generalised haemorrhagic septicaemic inflammatory response of all tissues
- bacterial colonisation of well-vascularised tissue (spleen, liver, heart, gills, kidney)
- necrosis of haematopoietic tissue in the kidney and spleen.

Disease agent

ERMD is caused by infection with *Yersinia ruckeri* (Hagerman strain), a member of the family *Enterobacteriaceae*. There are several serotypes of the bacterium, and classification systems can be based upon whole-cell typing as well as individual cell-wall antigen groupings. The serotype responsible for ERMD is the Hagerman strain, serotype O1a, is considered to be the most virulent.

The enteric red mouth strain of *Y. ruckeri* (serotype O1a) is exotic to Australia. However, a virulent form of *Y. ruckeri* (serotype O1b) is endemic in Australia. Serotype O1b produces a septicaemic condition in Atlantic salmon (*Salmo salar*) known as yersiniosis. A characteristic of this form of the disease is exophthalmia (popeye) and the formation of pronounced haemorrhages in the eye that give rise to the description of blood spot disease. Signs typical of classical ERMD—prominent reddening of the corners of the mouth, gums and palate—do not normally occur in yersiniosis.

Host range

Table 28 Species found in Australia known to be naturally susceptible to ERMD

Common name	Scientific name
Atlantic salmon	<i>Salmo salar</i>
Brown trout	<i>Salmo trutta</i>
Brook trout	<i>Salvelinus fontinalis</i>
Common carp and koi carp	<i>Cyprinus carpio</i>
Goldfish	<i>Carassius auratus</i>
Rainbow trout	<i>Oncorhynchus mykiss</i>

Table 29 Species not commonly found in Australia known to be naturally susceptible to ERMD

Common name	Scientific name
Salmonids	
Arctic char	<i>Salvelinus alpinus</i>
Chinook salmon	<i>Oncorhynchus tshawytscha</i>
Coho salmon	<i>Oncorhynchus kisutch</i>
Cutthroat trout	<i>Oncorhynchus clarkii</i>
Sockeye salmon	<i>Oncorhynchus nerka</i>
Whitefish	<i>Coregonus</i> spp.
Whitefish (Muksun)	<i>Coregonus muksun</i>
Whitefish (Peled)	<i>Coregonus peled</i>
Non-salmonids	
Bighead carp	<i>Aristichthys nobilis</i>
Burbot	<i>Lota lota</i>
Channel catfish	<i>Ictalurus punctatus</i>
Cisco	<i>Coregonus artedi</i>
Common sole	<i>Solea solea</i>
Emerald shiner	<i>Notropis atherinoides</i>
European eel	<i>Anguilla anguilla</i>
Fathead minnow	<i>Pimephales promelas</i>
Pike	<i>Esox lucius</i>
Siberian sturgeon	<i>Acipenser baerii</i>
Silver carp	<i>Hypophthalmichthys molitrix</i>
Turbot	<i>Scophthalmus maximus</i>

Table 30 Non-fish carriers

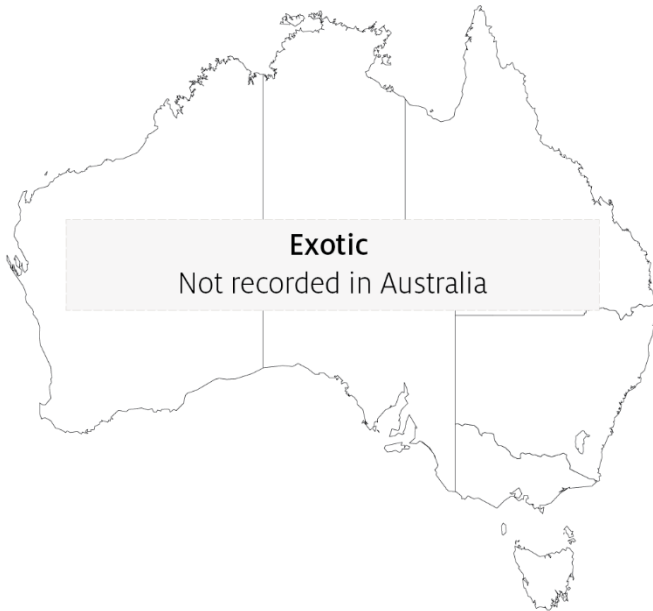Common name	Scientific name
Freshwater crayfish	Various genera and species

Presence in Australia

Exotic disease—not recorded in Australia.

A related disease known as yersiniosis or blood spot disease occurs in Australia.

Map 17 Presence of ERMD, by jurisdiction



Epidemiology

- Many other aquatic species are potential carriers but show no signs (some crustaceans, including freshwater crayfish).
- Transmission can be horizontal, via direct contact with infected fish or carriers. Carriers are particularly important sources of infection under stressful situations (such as increasing water temperature).
- *Yersinia ruckeri* can survive in the environment, with some strains able to form biofilms.
- Vertical transmission (fish to egg) is suggested by the presence of *Y. ruckeri* DNA in ovarian fluids and unfertilized eggs.
- ERMD causes septicaemia (bacteria are spread through the body via the blood).
- Fish of all ages are affected, and outbreaks usually begin with low mortalities that slowly escalate. The severity of the outbreak depends on the strain and presence of stressors.

Differential diagnosis

The list of [similar diseases](#) in the next section refers only to the diseases covered by this field guide. Gross pathological signs may also be representative of diseases not included in this guide. Do not rely on gross signs to provide a definitive diagnosis. Use them as a tool to help identify the listed diseases that most closely account for the observed signs.

Similar diseases

Infection with HPR-deleted or HPRO infectious salmon anaemia virus, infectious haematopoietic necrosis (IHN), spring viraemia of carp (SVC), viral haemorrhagic septicaemia (VHS) and whirling disease.

Sample collection

Only trained personnel should collect samples. Using only gross pathological signs to differentiate between diseases is not reliable, and some aquatic animal disease agents pose a risk to humans. If you are not appropriately trained, phone your state or territory hotline number and report your observations. If you have to collect samples, the agency taking your call will advise you on the appropriate course of action. Local or district fisheries or veterinary authorities may also advise on sampling.

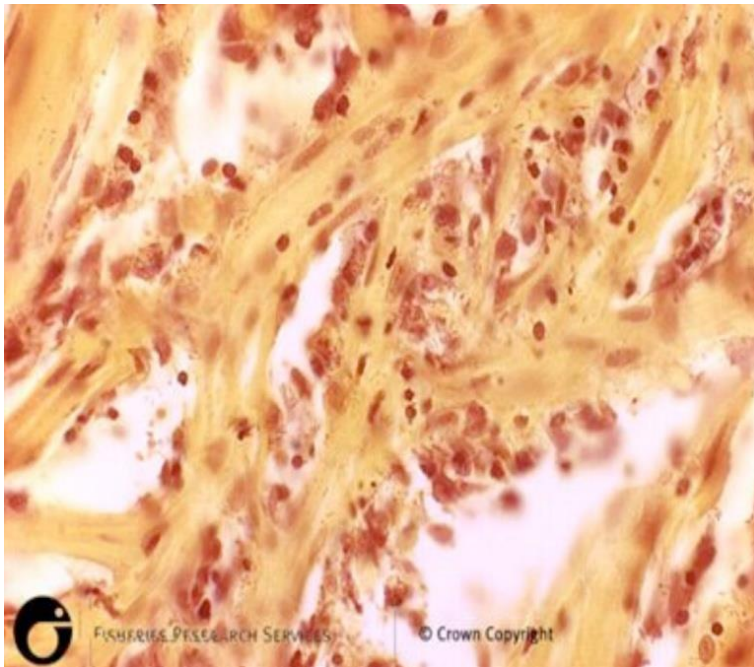
Emergency disease hotline

See something you think is this disease? Report it. Even if you're not sure.

Call the Emergency Animal Disease Watch Hotline on **1800 675 888**. They will refer you to the right state or territory agency.

Microscope images

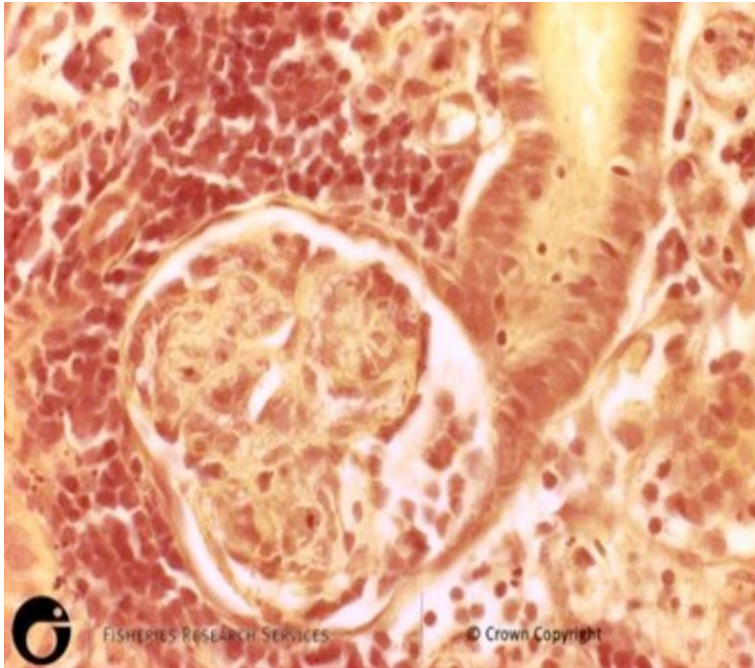
Figure 63 Skeletal muscle of rainbow trout (*Oncorhynchus mykiss*) naturally infected with *Yersinia ruckeri*



Note: Diffuse haemorrhage evident in sections of skeletal muscle.

Source: Scottish Government

Figure 64 Kidney of rainbow trout (*Oncorhynchus mykiss*) naturally infected with *Yersinia ruckeri*



Note: Diffuse haemorrhage evident in sections of kidney.

Source: Scottish Government

Further reading

CEFAS International Database on Aquatic Animal Diseases [Enteric Redmouth](#)

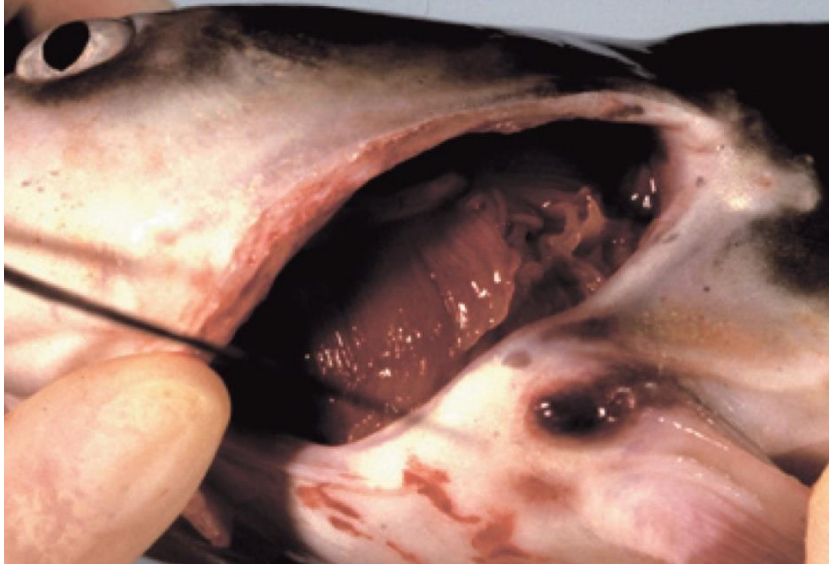Glenn RA, Taylor PW, Pelton EH, Gutenberger SK, Ahrens MA, Marchant LM, Hanson KC 2015, [Genetic evidence of vertical transmission and cycling of 'Yersinia ruckeri' in hatchery-origin fall chinook salmon 'Oncorhynchus tshawytscha'](#), *Journal of Fish and Wildlife Management*.

Kumar G, Menanteau-Ledouble S, Saleh M, El-Matbouli M 2015, ['Yersinia ruckeri', the causative agent of enteric red mouth disease in fish](#), *Veterinary Research*.

Enteric septicaemia of catfish

Also known as infection with *Edwardsiella ictaluri*, edwardsiellosis and hole-in-the-head disease

Figure 65 Ulcer in channel catfish (*Ictalurus punctatus*) with chronic enteric septicaemia of catfish



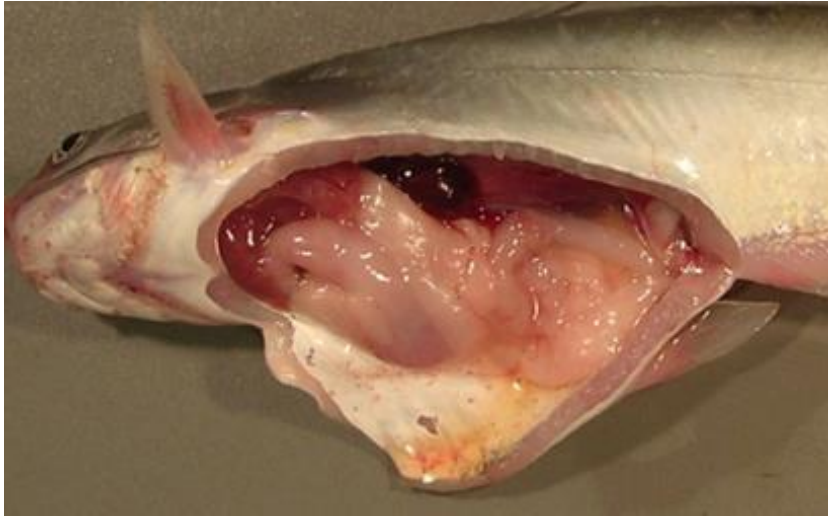Note: Ulcerative lesions in the joints of the pectoral or dorsal spines.
Source: L A Hanson

Figure 66 Cranial ulcer in channel catfish (*Ictalurus punctatus*) with enteric septicaemia of catfish



Note: Cranial ulcer, also known as a hole-in-the-head lesion.
Source: L Khoo

Figure 67 Internal organs of channel catfish (*Ictalurus punctatus*) with enteric septicaemia of catfish



Note: Signs of infection with *Edwardsiella ictaluri* include swollen posterior kidney, enlarged spleen, gastro-intestinal haemorrhage and ascites fluid.

Source: L Khoo

Signs of disease

Important: Animals with this disease may show one or more of these signs, but the pathogen may still be present in the absence of any signs.

Disease signs at the farm, tank or pond level are:

- lethargic swimming
- abnormal behaviour (alternating listlessness and chaotic swimming)
- disorientation and swimming in spirals
- loss of appetite
- surfing, with head protruding from water.

Gross pathological signs are:

- chronic encephalitic form
 - swelling on top of the head, occasionally progressing to the erosion of connective tissue and exposure of the brain (a hole-in-the-head lesion)
 - granulomatous inflammation of the brain
- acute septicaemic form
 - pale gills
 - darkening of the skin (observed in species other than channel catfish)
 - multiple small white spots on the skin
 - raised skin patches progressing to shallow ulcers on the flanks and head
 - haemorrhage at the base of the fins, around the mouth, and on the throat, operculum (gill cover) and abdomen
 - exophthalmos (popeye)

- swollen abdomen (pot-belly)
- ascites (fluid in the abdominal cavity)
- lesions on the liver and other internal organs
- intestines frequently bloody, but may be transparent or clear yellow
- red, swollen anal region with trailing faecal casts (observed in infected barramundi)
- soft and pale spleen, anterior kidney or posterior kidney, with petechial (pinpoint) haemorrhages.

Microscopic pathological signs are:

- gram-negative rods in histological sections (muscle, kidney)
- locally extensive cellulitis in the head region
- necrotising myositis.

Disease agent

. Enteric septicaemia of catfish (or edwardsiellosis) is caused by infection with the bacterium *Edwardsiella ictaluri*, belonging to the family *Enterobacteriaceae*.

Host range

Enteric septicaemia of catfish is a highly infectious bacterial disease of the catfish families *Ictaluridae*, *Plotosidae*, *Clariidae*, *Siluridae*, *Pangasiidae* and *Ariidae*. Ictalurids are particularly susceptible. Several non-catfish species are also susceptible, including salmonids.

Table 31 Species known to be susceptible to *Edwardsiella ictaluri*

Common name	Scientific name
Ayu ^a	<i>Plecoglossus altivelis</i>
Barramundi	<i>Lates calcarifer</i>
Berney's catfish	<i>Neoarius berneyi</i>
Black bullhead ^a	<i>Ameiurus melas</i>
Black catfish	<i>Neosilurus ater</i>
Blue catfish ^a	<i>Ictalurus furcatus</i>
Brown bullhead ^a	<i>Ameiurus nebulosus</i>
Channel catfish ^a	<i>Ictalurus punctatus</i>
Chinook salmon	<i>Oncorhynchus tshawytscha</i>
Glass knifefish ^a	<i>Eigenmannia virescens</i>
Rainbow trout	<i>Oncorhynchus mykiss</i>
Rosy barb ^a	<i>Puntius conchoni</i>
Sind danio ^a	<i>Danio devario</i>
Sutchi catfish ^a	<i>Pangasius hypophthalmus</i>
Tadpole madtom ^a	<i>Noturus gyrinus</i>
Toothless catfish	<i>Anodontiglanis dahlia</i>
Walking catfish ^a	<i>Clarias batrachus</i>
Wet tropics tandan ^a	<i>Tandanus tropicanus</i>

Common name	Scientific name
White catfish ^a	<i>Ameiurus catus</i>
Yellow bullhead ^a	<i>Ameiurus natalis</i>
Yellow catfish ^a	<i>Pelteobagrus fulvidraco</i>
Zebrafish ^a	<i>Danio rerio</i>

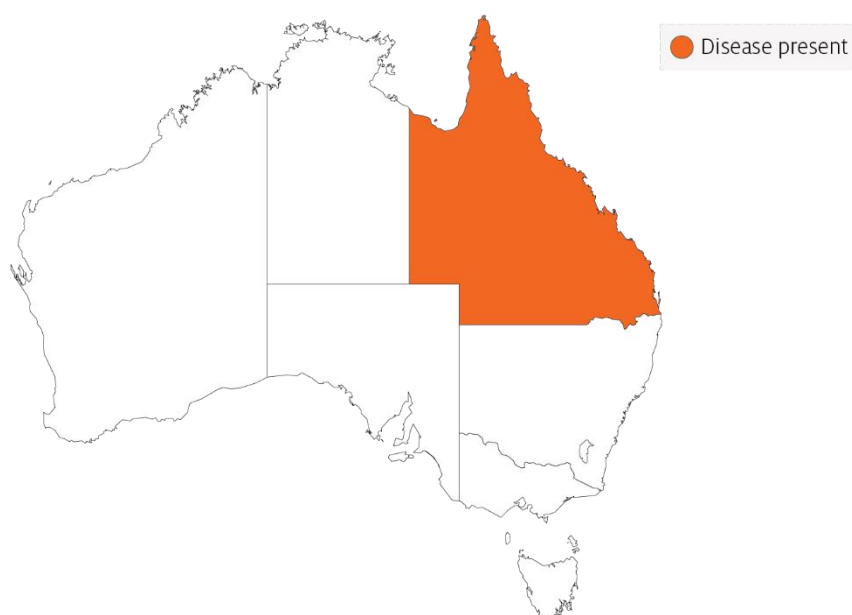
^a Naturally susceptible. Note: Other species have been shown to be experimentally susceptible.

Presence in Australia

Edwardsiella ictaluri has been isolated from healthy wild wet-tropics tandan catfish, from the Tully River valley in north Queensland, at a prevalence of 40%.

Enteric septicaemia of catfish has also been officially reported in Australia from imported aquarium fish (danios, rosy barbs) held in contained facilities in the Northern Territory and Tasmania. In 2010 and 2011, native black catfish, toothless catfish and Berney's catfish held near imported aquarium fish in a facility in the Northern Territory became infected, resulting in mortalities. There have been no detections of the disease in the wild in the Northern Territory or Tasmania.

Map 18 Presence of *Edwardsiella ictaluri*, by jurisdiction



Epidemiology

- *Edwardsiella ictaluri* has been linked to disease outbreaks in barramundi (also known as Asian seabass) and *Pangasius* (basa catfish).
- Enteric septicaemia of catfish was originally considered primarily a disease of channel catfish. However, the bacterium has since been reported to cause disease in other catfish and non-catfish species. Most of the epidemiological knowledge about the disease is based on its occurrence in channel catfish.
- Horizontal transmission is via the faecal-oral route, cannibalism, and contact with contaminated water and materials used in handling infected fish.

- Faeces are the main source of shedding and dissemination. The disease may also be spread via dead fish and contaminated equipment such as fishing nets and sorting devices.
- The intestinal tract is the primary site of infection for the acute septicaemic form. The chronic encephalitic form is thought to establish after entering fish via the olfactory epithelium.
- Surviving catfish carry the bacterium, which also seems to be able to survive in the intestinal tracts of other fish species.
- Disease occurs primarily at water temperatures between 18°C and 28°C, making spring and autumn the most common times for outbreaks. Stress is often a predisposing factor.
- The bacterium can survive 3 to 4 months in pond water, mud and vegetation.
- Environmental stressors can influence the expression of clinical signs and extend the incubation period.
- Morbidity and mortality can be high in heavily stocked ponds.

Differential diagnosis

The list of [similar diseases](#) in the next section refers only to the diseases covered by this field guide. Gross pathological signs may also be representative of diseases not included in this guide. Do not rely on gross signs to provide a definitive diagnosis. Use them as a tool to help identify the listed diseases that most closely account for the observed signs.

Similar diseases

Channel catfish virus disease, European catfish virus and European sheatfish virus, infection with *Aphanomyces invadans* and spring viraemia of carp.

Sample collection

Only trained personnel should collect samples. Using only gross pathological signs to differentiate between diseases is not reliable, and some aquatic animal disease agents pose a risk to humans. If you are not appropriately trained, phone your state or territory hotline number and report your observations. If you have to collect samples, the agency taking your call will advise you on the appropriate course of action. Local or district fisheries or veterinary authorities may also advise on sampling.

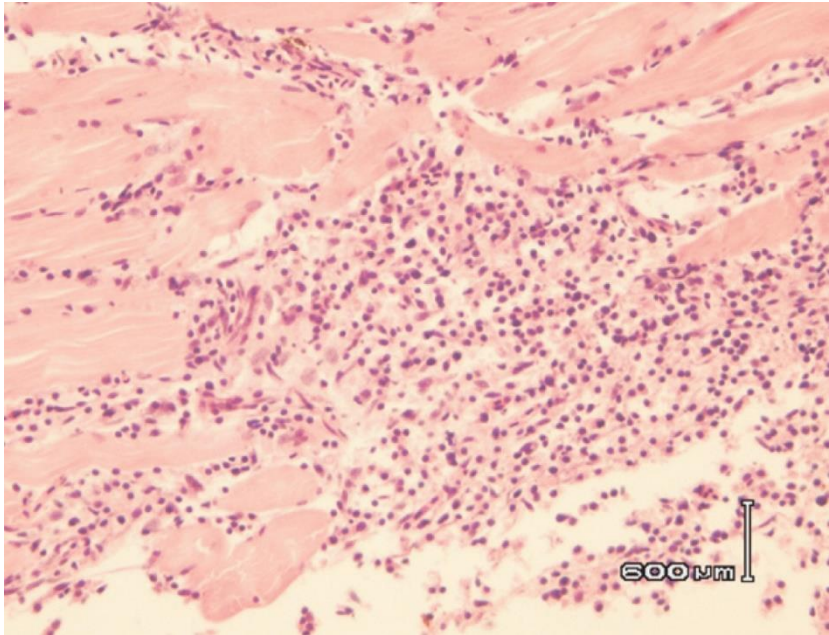
Emergency disease hotline

See something you think is this disease? Report it. Even if you're not sure.

Call the Emergency Animal Disease Watch Hotline on **1800 675 888**. They will refer you to the right state or territory agency.

Microscope images

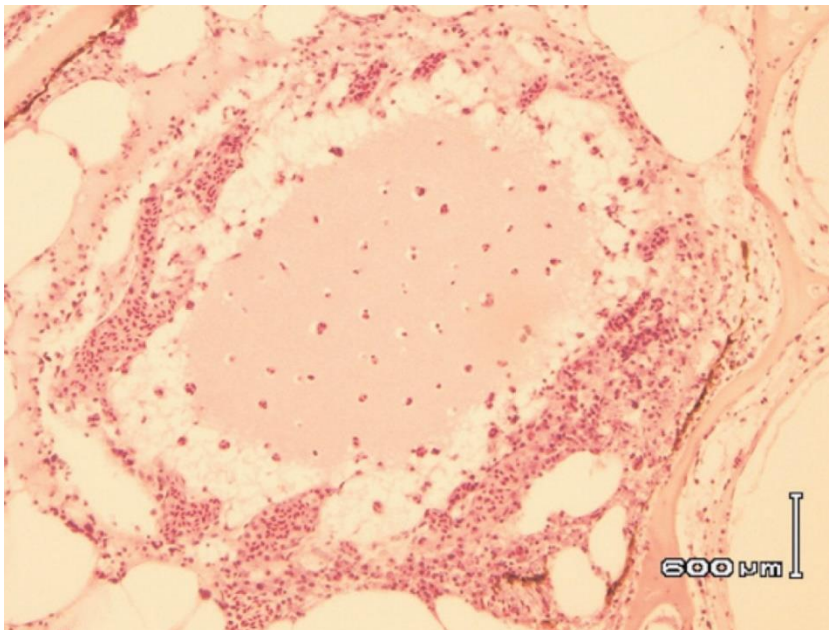
Figure 68 Histopathological section of skeletal muscle of channel catfish (*Ictalurus punctatus*) with enteric septicaemia of catfish



Note: Necrotising myositis in the skeletal muscle. Scale bar = 600μm.

Source: G Storie and H Prior

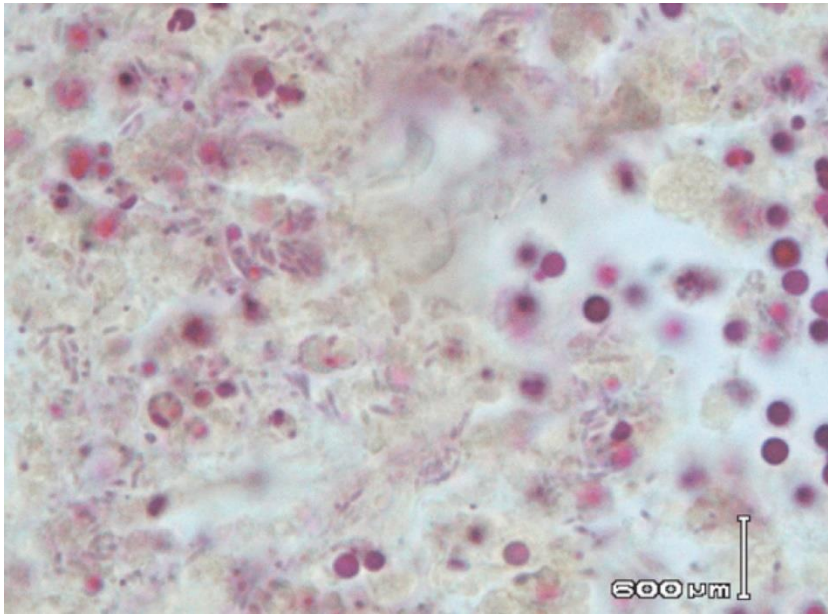
Figure 69 Histopathological section of head of channel catfish (*Ictalurus punctatus*) with enteric septicaemia of catfish



Note: Locally extensive cellulitis involving connective tissue surrounding cranial bones and cartilage. Scale bar = 600μm.

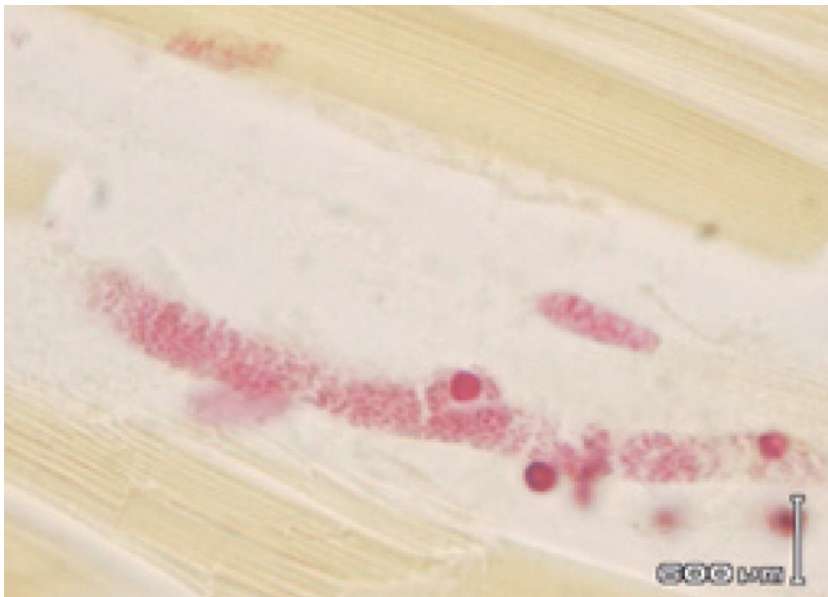
Source: G Storie and H Prior

Figure 70 Gram staining of histopathological section from kidney of channel catfish (*Ictalurus punctatus*) with enteric septicaemia of catfish



Note: Gram-negative rods are *Edwardsiella ictaluri*. Scale bar = 600μm.
Source: G Storie and H Prior

Figure 71 Gram staining of histopathological section from skeletal muscle of channel catfish (*Ictalurus punctatus*) with enteric septicaemia of catfish



Note: Gram-negative rods of *Edwardsiella ictaluri*. Scale bar = 600μm.
Source: G Storie and H Prior

Further reading

CABI Invasive Species Compendium [Enteric septicaemia of catfish](#)

CEFAS International Database on Aquatic Animal Diseases [Enteric Septicaemia of Catfish \(Edwardsiellosis\)](#)

Furunculosis

Also known as infection with *Aeromonas salmonicida* subsp. *salmonicida*

Exotic disease

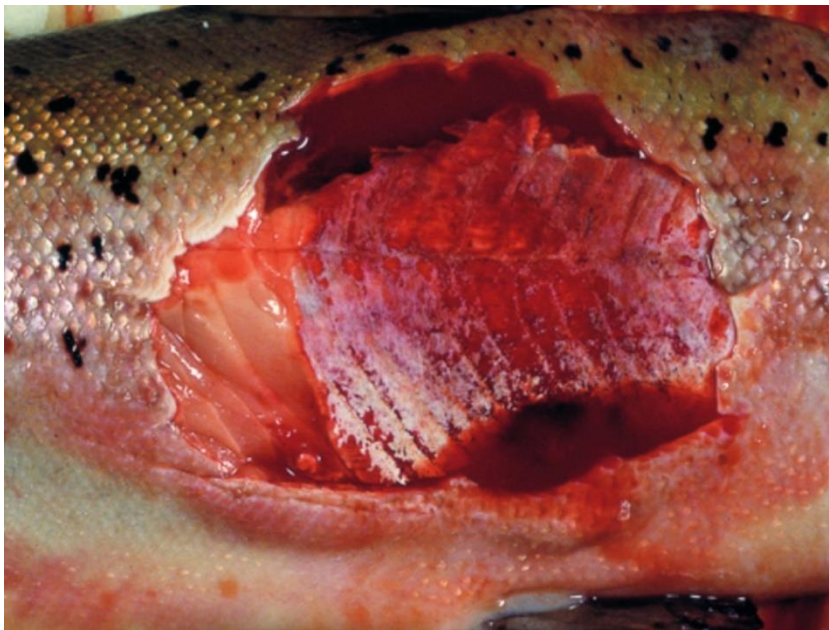Figure 72 Furunculosis in Atlantic salmon (*Salmo salar*)



Note: Large furuncle (boil) on side of fish.

Source: T Håstein

Figure 73 Atlantic salmon (*Salmo salar*) with furunculosis boil exposed below the surface of the skin



Note: Furuncle has been cut away to show underlying necrotic tissue.

Source: T Håstein

Signs of disease

Important: Animals with this disease may show one or more of these signs, but the pathogen may still be present in the absence of any signs.

Disease signs at the farm, tank or pond level are:

- sudden death, perhaps with slight exophthalmos (popeye)
- often no clinical signs in young fish with peracute form of the disease
- death within days of initial clinical signs of disease in growing fish with acute furunculosis
- high mortality
- lethargic swimming or swimming just below the surface
- loss of appetite
- respiratory distress and jumping from the water immediately before an outbreak.

Gross pathological signs are:

- furuncles (boils) involving skin and/or muscle, progressing to crater lesions (usually restricted to the subacute or chronic phase in adult salmon)
- haemorrhages on the skin, mouth and fin bases (mainly of paired fins)
- darkening of body colour and pale gills
- bloody discharge from nares and/or vent
- exophthalmos (popeye)
- haemorrhages in muscle and internal organs
- enlarged spleen and focal necrosis of the liver
- stomach filled with mucus, blood and sloughed epithelial cells
- congested intestine
- death without any clinical signs other than darkening of the skin (occurs only in peracute infections in juvenile salmon).

Microscopic pathological signs are:

- fusion of gill lamellae, with necrosis of the epithelium
- eosinophilic inflammatory changes in gills
- bacterial colonies in many tissues
- sloughing of renal tubular cells into the renal tubular lumen
- sloughing of intestinal epithelial cells into the intestinal lumen.

Disease agent

Furunculosis is caused by infection with the bacterium *Aeromonas salmonicida* subsp. *salmonicida*, a member of the family *Enterobacteriaceae*. The bacterium is intracellular and so may avoid some host immune defences after infection. During infection, the bacterium produces extracellular toxins that may play a significant role in the pathogenesis of the disease. There are four other subspecies of *A. salmonicida*; these 'atypical' strains are considered to cause a different disease syndrome, infection with *Aeromonas salmonicida*—atypical strains, which is also discussed in this guide.

Host range

All salmonids and eels are believed to be susceptible to *A. salmonicida* subsp. *salmonicida*. Species known to be susceptible are listed in Table 32. The bacterium has also been isolated from sea lice infecting lesions on fish and can be spread by piscivorous birds.

Table 32 Species known to be susceptible to *Aeromonas salmonicida* subsp. *salmonicida*

Common name	Scientific name
Amago salmon ^a	<i>Oncorhynchus rhodurus</i>
American eel ^a	<i>Anguilla rostrata</i>
Arctic char	<i>Salvelinus alpinus</i>
Atlantic cod ^a	<i>Gadus morhua</i>
Atlantic salmon ^a	<i>Salmo salar</i>
Atlantic wolfish ^a	<i>Anarhichas lupus</i>
Ayu	<i>Plecoglossus altivelis</i>
Black sea salmon	<i>Salmo labrax</i>
Brook trout ^a	<i>Salvelinus fontinalis</i>
Brown trout ^a	<i>Salmo trutta</i>
Bull trout	<i>Salvelinus confluentus</i>
Bullhead	<i>Cottus gobio</i>
Chinook salmon	<i>Oncorhynchus tshawytscha</i>
Chum salmon	<i>Oncorhynchus keta</i>
Cisco	<i>Coregonus artedii</i>
Coho salmon	<i>Oncorhynchus kisutch</i>
Common shiner	<i>Luxilus cornutus</i>
Cutthroat trout	<i>Oncorhynchus clarkii</i>
Danube salmon	<i>Hucho hucho</i>
Eels	<i>Anguillidae</i> all species
European eel	<i>Anguilla anguilla</i>
Galaxiids	<i>Galaxiidae</i> all species
Gila trout	<i>Oncorhynchus gilae</i>
Gilt-head sea bream	<i>Sparus aurata</i>
Golden trout	<i>Oncorhynchus aguabonita</i>
Grayling	<i>Thymallus thymallus</i>
Hybrid (rainbow trout × coho salmon)	<i>Oncorhynchus mykiss</i> × <i>O. kisutch</i>

Common name	Scientific name
Japanese eel	<i>Anguilla japonica</i>
Lake trout	<i>Salvelinus namaycush</i>
Lake whitefish	<i>Coregonus clupeaformis</i>
Masu salmon	<i>Oncorhynchus masou</i>
Mountain whitefish	<i>Prosopium williamsoni</i>
Pacific halibut ^a	<i>Hippoglossus stenolepis</i>
Pacific salmon ^a	<i>Oncorhynchus</i> spp.
Pike	<i>Esox lucius</i>
Pike perch	<i>Sander lucioperca</i>
Pink salmon ^a	<i>Oncorhynchus gorbuscha</i>
Rainbow trout ^a	<i>Oncorhynchus mykiss</i>
Salmonids (all presumed susceptible) ^a	<i>Salmonidae</i> all species
Sea lamprey ^a	<i>Petromyzon marinus</i>
Shortfin eel	<i>Anguilla australis</i>
Sockeye salmon ^a	<i>Oncorhynchus nerka</i>
Splake (lake trout × brook trout)	<i>Salvelinus namaycush</i> × <i>S. fontinalis</i>
Turbot	<i>Scophthalmus maximus</i>
Whitefish (Muksun)	<i>Coregonus muksun</i>
Whitefish (Peled)	<i>Coregonus peled</i>
Whitespotted char	<i>Salvelinus leucomaenis</i>
Wrasses	<i>Labridae</i> all species

^a Naturally susceptible. Note: Other species likely to be susceptible or shown to be experimentally susceptible.

Table 33 Non-fish carriers

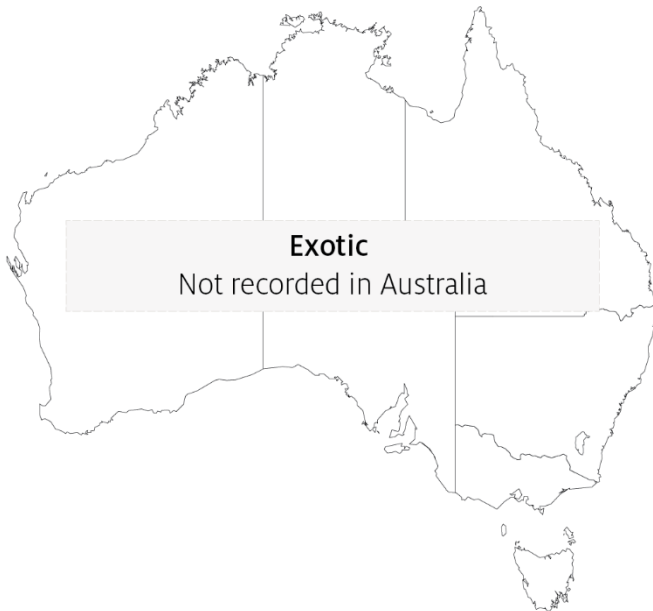Common name	Scientific name
Salmon louse A (<i>Lepeophtheirus</i> spp.)	<i>Lepeophtheirus salmonis</i>
Salmon louse B (<i>Caligus</i> spp.)	<i>Caligus elongatus</i>
Piscivorous birds	Various genera and species

Presence in Australia

Exotic disease—not recorded in Australia.

The strain of *Aeromonas* causing furunculosis in salmonids overseas (typical strain) is not present in Australia. However, atypical strains are present (see Infection with *Aeromonas salmonicida*—atypical strains).

Map 19 Presence of furunculosis, by jurisdiction



Epidemiology

- Furunculosis is highly contagious and affects fish of all ages.
- The disease is one of the most commercially significant salmonid diseases, occurring in freshwater and marine salmonid aquaculture in all countries except Australia and New Zealand.
- Overseas, this disease must be controlled on farms by medication or vaccination.
- Outbreaks typically occur at temperatures above 10°C. However outbreaks can occur in very young fish and at temperatures as low as 2 to 4°C. Disease may be precipitated by endogenous stressors (such as smoltification or spawning) and exogenous stressors (such as temperature fluctuations or poor water quality).
- Australia's relatively warm water temperatures may favour the establishment of *A. salmonicida* subsp. *salmonicida*.
- Rainbow trout are relatively resistant to the disease, but are still considered susceptible.
- Horizontal transmission occurs via the water column, but also through direct fish-to-fish contact and animal vectors (birds and invertebrates such as sea lice).
- *Aeromonas salmonicida* subsp. *salmonicida* has been detected on the surface of fertilised eggs. Surface decontamination using iodine is effective in preventing vertical transmission (passage of infection from parent to offspring).
- *Aeromonas salmonicida* subsp. *salmonicida* can survive for months in some environments.

- Non-salmonids may become infected by ingesting tissue of infected salmonids. Transmission to non-salmonids can occur where fish caught for feed are taken from waters near an outbreak.
- Susceptibility to the disease increases with damaged mucous and skin, such as occurs when fish are handled with nets.
- Fish surviving disease outbreaks are recognised as carriers of the disease. Carriers may continue to infect the remaining population without themselves showing any outward signs of infection. Stress may precipitate disease in subclinical carriers.

Differential diagnosis

The list of [similar diseases](#) in the next section refers only to the diseases covered by this field guide. Gross pathological signs may also be representative of diseases not included in this guide. Do not rely on gross signs to provide a definitive diagnosis. Use them as a tool to help identify the listed diseases that most closely account for the observed signs.

Similar diseases

Epizootic haematopoietic necrosis (EHN), infection with *Aeromonas salmonicida*—atypical strains and infectious haematopoietic necrosis (IHN).

Sample collection

Only trained personnel should collect samples. Using only gross pathological signs to differentiate between diseases is not reliable, and some aquatic animal disease agents pose a risk to humans. If you are not appropriately trained, phone your state or territory hotline number and report your observations. If you have to collect samples, the agency taking your call will advise you on the appropriate course of action. Local or district fisheries or veterinary authorities may also advise on sampling.

Emergency disease hotline

See something you think is this disease? Report it. Even if you're not sure.

Call the Emergency Animal Disease Watch Hotline on **1800 675 888**. They will refer you to the right state or territory agency.

Further reading

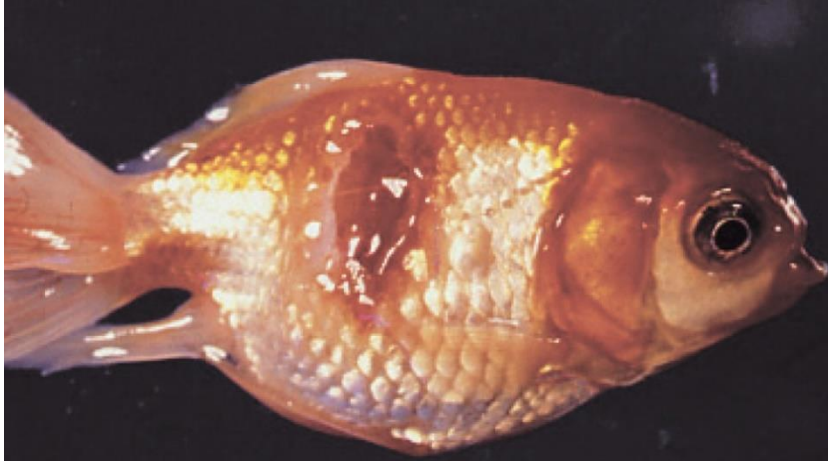CEFAS International Database on Aquatic Animal Diseases [Furunculosis](#)

Department of Agriculture [AQUAVETPLAN disease strategy manual: Furunculosis](#)

Infection with *Aeromonas salmonicida*—atypical strains

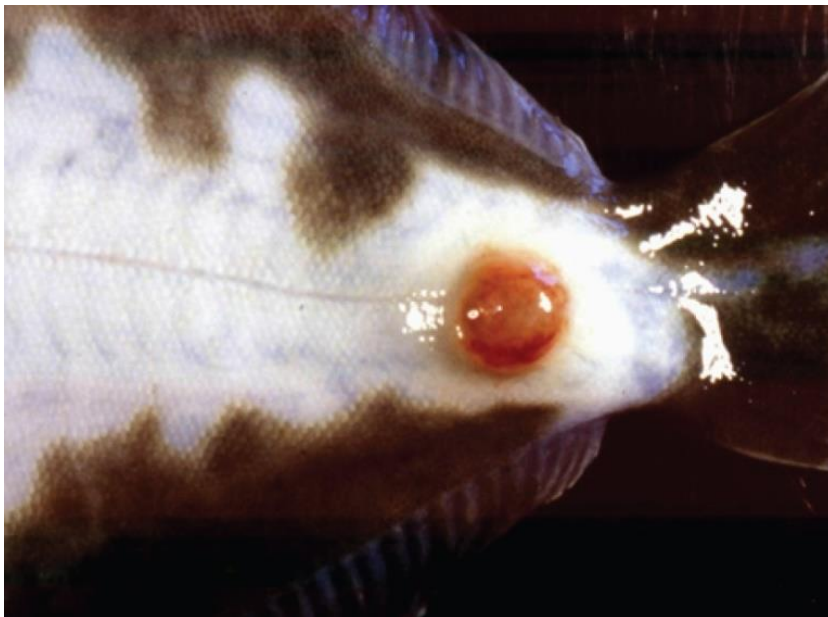Also known as infection with atypical strains of *Aeromonas salmonicida*, marine aeromonad disease of salmonids (MAS), goldfish ulcer disease, carp erythrodermatitis and ulcer disease of flounder, eel and salmon

Figure 74 Goldfish ulcer disease in goldfish (*Carassius auratus*)



Note: Characteristic ulcers on the body.
Source: J Carson

Figure 75 Greenback flounder (*Rhombosolea tapirina*) infected with greenback flounder strain of *Aeromonas salmonicida*



Note: Ulcer on ventral side of body.
Source: J Carson.

Figure 76 Infection with atypical *Aeromonas salmonicida* in silver perch (*Bidyanus bidyanus*)



Note: Ulcers on body.

Source: M Landos

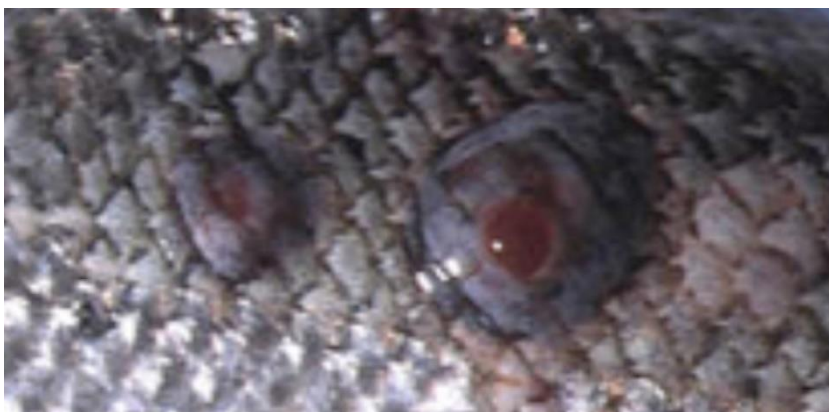Figure 77 Infection with *Aeromonas salmonicida* biovar Acheron in Atlantic salmon (*Salmo salar*)



Note: Haemorrhagic lesion on the flank typical of MAS.

Source: K Ellard

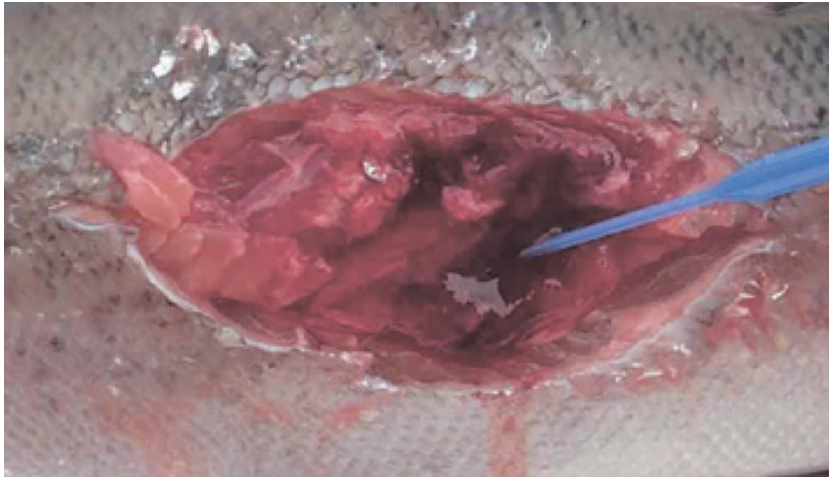
Figure 78 Atlantic salmon (*Salmo salar*) with blood filled MAS ulcerations



Note Blood-filled furuncles in MAS are rarely noted, because they rupture easily.

Source: K Ellard

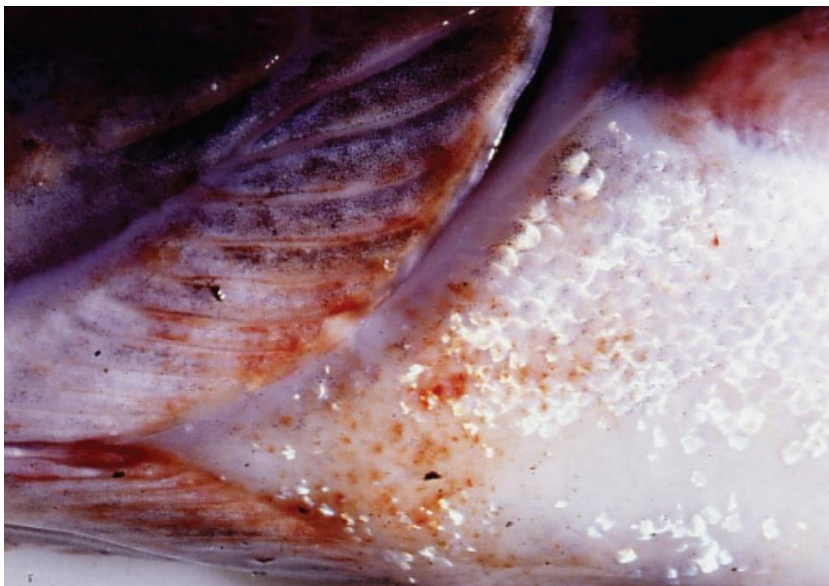Figure 79 Atlantic salmon (*Salmo salar*) with MAS ulcer exposed below the surface of the skin



Note: The MAS lesion extends into the underlying muscle.

Source: K Ellard

Figure 80 Atlantic salmon (*Salmo salar*) infected with greenback flounder strain of atypical *A. salmonicida* after cohabitation with infected flounder



Note: Haemorrhagic lesions around the isthmus and branchiostegal membranes.

Source: J Carson

Signs of disease

Important: Animals with this disease may show one or more of these signs, but the pathogen may still be present in the absence of any signs.

Disease signs at the farm, tank or pond level are:

- lethargic swimming
- abnormal swimming and disorientation
- loss of appetite
- increased mortality.

Gross pathological signs are:

- white raised patches on the skin that progress to ragged-edged red ulcers
- haemorrhages on the skin and fin bases (usually the paired fins)
- fingernail-sized ulcers found anywhere on the fish, most often on the upper side of the lateral line behind the head or at the base of the tail fin
- pale gills with petechial (pinpoint) haemorrhages
- intestinal protrusion through the abdominal wall following severe ulceration
- haemorrhages in muscle and internal organs
- swollen kidneys and spleen.

Microscopic pathological signs are:

- hyperplasia of the gills, which may contain bacterial colonies
- ulcerated areas that show oedema, hyperaemia, leukocyte infiltration and considerable degenerative changes
- hyperaemia and haemorrhage in the spleen and kidneys
- fibroblast-like cells, which may produce granulomas in the dermis, spleen and kidney.

Disease agent

Atypical strains of the *Aeromonas salmonicida* bacterium within the family *Enterobacteriaceae* differ from the typical strain causing furunculosis in salmonids. Atypical strains affect mainly non-salmonids (wild and cultured, marine and freshwater). Infection with atypical *A. salmonicida* does not necessarily result in the acute mortality and septicaemia that are characteristic of the typical furunculosis strain, but manifests more as external lesions and ulceration, often involving secondary infection. An exception is MAS in Tasmania; in such cases, Atlantic salmon are most commonly affected, and clinical presentation is similar to furunculosis.

There are five subspecies of *A. salmonicida*. *A. salmonicida salmonicida* is known as the typical strain and is the only one to cause furunculosis (listed separately in this guide). The other four subspecies (*achromogenes*, *masoucida*, *smithia* and *pectinolytica*) are referred to as atypical *A. salmonicida* and are recognised worldwide. All except *A. salmonicida pectinolytica* cause disease in fish.

A. salmonicida biovar Acheron is a new atypical strain recently described in Australia (Tasmania), causing MAS in Atlantic salmon.

Host range

Laboratory experiments indicate that all trout and salmon species, as well as many non-salmonids, are potentially susceptible to atypical strains of *A. salmonicida*. For example, Atlantic salmon and striped trumpeter can be infected by cohabitation with infected flounder.

Rainbow trout are relatively resistant to atypical strains.

Table 34 Species known to be susceptible to atypical strains of *Aeromonas salmonicida*

Common name	Scientific name
Amago salmon ^a	<i>Oncorhynchus rhodurus</i>
American eel ^a	<i>Anguilla rostrata</i>
American plaice	<i>Hippoglossoides platessoides</i>
Arctic char	<i>Salvelinus alpinus</i>
Atlantic cod ^a	<i>Gadus morhua</i>
Atlantic herring ^a	<i>Clupea harengus</i>
Atlantic salmon ^a	<i>Salmo salar</i>
Ayu	<i>Plecoglossus altivelis</i>
Black sea salmon	<i>Salmo labrax</i>
Black rockfish ^a	<i>Sebastes schlegelii</i>
Brook trout ^a	<i>Salvelinus fontinalis</i>
Brown trout ^a	<i>Salmo trutta</i>
Bull trout	<i>Salvelinus confluentus</i>
Chub ^a	<i>Leuciscus cephalus</i>
Chinook salmon	<i>Oncorhynchus tshawytscha</i>
Chum salmon ^a	<i>Oncorhynchus keta</i>
Coho salmon	<i>Oncorhynchus kisutch</i>
Common carp and koi carp ^a	<i>Cyprinus carpio</i>
Common roach ^a	<i>Rutilus rutilus</i>
Crucian carp ^a	<i>Carassius carassius</i>
Cutthroat trout	<i>Oncorhynchus clarkii</i>
Dab ^a	<i>Limanda limanda</i>
Dace ^a	<i>Leuciscus leuciscus</i>
Danube salmon	<i>Hucho hucho</i>
Eels	<i>Anguillidae</i> all species
European eel	<i>Anguilla anguilla</i>
Flounder ^a	<i>Platichthys flesus</i>
Fourbeard rockling ^a	<i>Enchelyopus cimbrius</i>
Freshwater bream ^a	<i>Abramis brama</i>
Gila trout	<i>Oncorhynchus gilae</i>
Golden trout	<i>Oncorhynchus aguabonita</i>
Goldfish ^a	<i>Carassius auratus</i>
Goldsinny ^a	<i>Ctenolabrus rupestris</i>
Grayling ^a	<i>Thymallus thymallus</i>
Great sandeel ^a	<i>Hyperoplus lanceolatus</i>
Greenback flounder ^a	<i>Rhombosolea tapirina</i>
Haddock ^a	<i>Melanogrammus aeglefinus</i>

Common name	Scientific name
Hybrid (rainbow trout × coho salmon)	<i>Oncorhynchus mykiss</i> × <i>O. kisutch</i>
Japanese eel	<i>Anguilla japonica</i>
Japanese flounder ^a	<i>Paralichthys olivaceus</i>
Lake trout	<i>Salvelinus namaycush</i>
Lake whitefish	<i>Coregonus clupeaformis</i>
Lesser sand eel	<i>Ammodytes tobianus</i>
Masu salmon ^a	<i>Oncorhynchus masou</i>
Minnow ^a	<i>Phoxinus phoxinus</i>
Pacific halibut ^a	<i>Hippoglossus stenolepis</i>
Pacific salmon ^a	<i>Oncorhynchus</i> spp.
Pike	<i>Esox lucius</i>
Pink salmon	<i>Oncorhynchus gorbuscha</i>
Plaice ^a	<i>Pleuronectes platessa</i>
Rainbow trout ^a	<i>Oncorhynchus mykiss</i>
Redfin or European perch	<i>Perca fluviatilis</i>
Rudd ^a	<i>Scardinius erythrophthalmus</i>
Sablefish	<i>Anoplopoma fimbria</i>
Salmonids (all presumed susceptible) ^a	<i>Salmonidae</i> all species
Shortfin eel	<i>Anguilla australis</i>
Shotted halibut ^a	<i>Eopsetta grigorjewi</i>
Shubunkin ^a	<i>Carassius</i> sp.
Silver bream ^a	<i>Blicca bjoerkna</i>
Silver perch ^a	<i>Bidyanus bidyanus</i>
Smallmouth bass ^a	<i>Micropterus dolomieu</i>
Sockeye salmon ^a	<i>Oncorhynchus nerka</i>
Splake (lake trout × brook trout)	<i>Salvelinus namaycush</i> × <i>S. fontinalis</i>
Spotted wolfish ^a	<i>Anarhichas minor</i>
Striped trumpeter ^a	<i>Latris lineata</i>
Tomcod ^a	<i>Gadus microgadus</i>
Turbot ^a	<i>Scophthalmus maximus</i>
Viviparous blenny ^a	<i>Zoarces viviparus</i>
Whitefish (Muksun)	<i>Coregonus muksun</i>
Whitefish (Peled)	<i>Coregonus peled</i>
Whitefish	<i>Coregonus</i> spp.
Whitespotted char	<i>Salvelinus leucomaenis</i>
Whiting ^a	<i>Merlangius merlangus</i>
Wrasse ^a	<i>Labrus bergylta</i>
Wrasses	<i>Labridae</i> all species

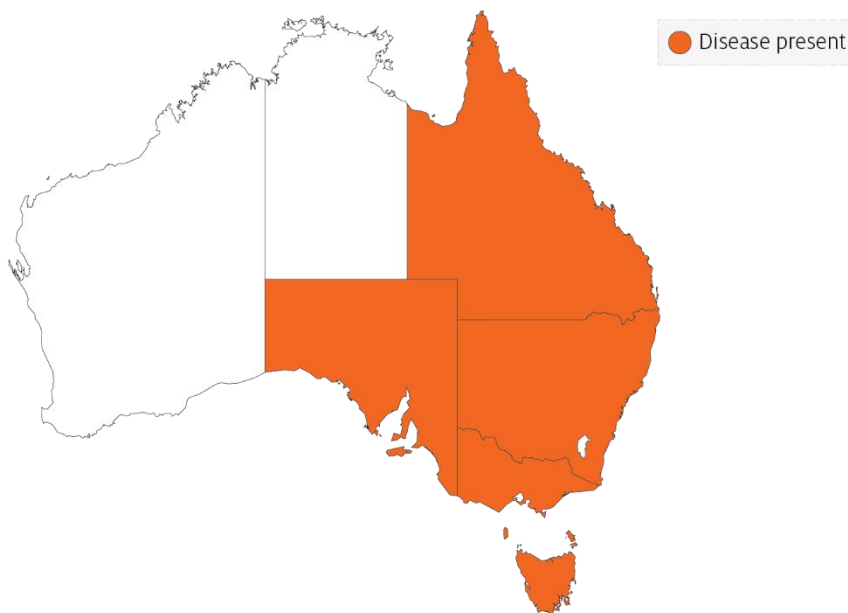
Common name	Scientific name
Yellow bass ^a	<i>Morone mississippiensis</i>

^a Naturally susceptible. Note: Other species likely to be susceptible.

Presence in Australia

Atypical *A. salmonicida* has been officially reported from New South Wales, Queensland, South Australia, Victoria (goldfish ulcer disease only) and Tasmania (greenback flounder biovar and Acheron biovar only). Movement controls are in place to prevent the spread of goldfish ulcer disease to Western Australia and Tasmania. The Acheron biovar has been reported only from Tasmania and is limited to an isolated production area.

Map 20 Presence of atypical strains of *Aeromonas salmonicida*, by jurisdiction



Epidemiology

- Transmission occurs horizontally (between fish via the water).
- Susceptibility to the disease increases with damaged mucus and skin, which occurs when fish are handled with nets.
- Outbreaks are expected to occur at water temperatures above 10°C (summer months in southern waters of Australia) and may be precipitated by stress (such as handling, overpopulation and rapid temperature fluctuations).
- Secondary infection with other bacteria often occurs.
- Fish that survive disease outbreaks are recognised as carriers of the disease. Carriers may continue to infect the remaining population without themselves exhibiting signs of infection.
- Diagnosis based on clinical or external signs of disease is difficult because clinical signs vary and skin ulcers are often infected with opportunistic bacteria and fungi. A definitive diagnosis requires laboratory examination.

Differential diagnosis

The list of [similar diseases](#) in the next section refers only to the diseases covered by this field guide. Gross pathological signs may also be representative of diseases not included in this guide. Do not rely on gross signs to provide a definitive diagnosis. Use them as a tool to help identify the listed diseases that most closely account for the observed signs.

Similar diseases

Channel catfish virus disease (CCVD), furunculosis, infection with *Aphanomyces invadans* (EUS), koi herpesvirus disease (KHV) and spring viraemia of carp (SVC).

Sample collection

Only trained personnel should collect samples. Using only gross pathological signs to differentiate between diseases is not reliable, and some aquatic animal disease agents pose a risk to humans. If you are not appropriately trained, phone your state or territory hotline number and report your observations. If you have to collect samples, the agency taking your call will advise you on the appropriate course of action. Local or district fisheries or veterinary authorities may also advise on sampling.

Emergency disease hotline

See something you think is this disease? Report it. Even if you're not sure.

Call the Emergency Animal Disease Watch Hotline on **1800 675 888**. They will refer you to the right state or territory agency.

Further reading

Menanteau-Ledouble S, Kumar G, Saleh M, El-Matbouli M 2016, [‘Aeromonas salmonicida’: updates on an old acquaintance](#), *Diseases of Aquatic Organisms*

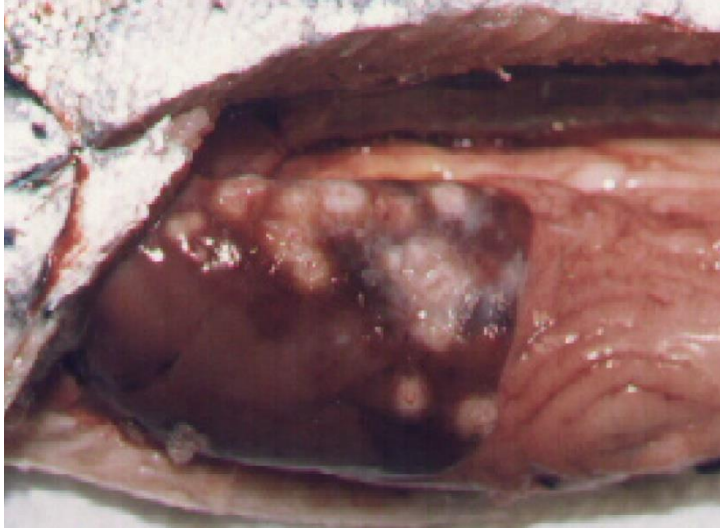
Whittington RJ, Djordjevic SP, Carson J, Callinan RB 1995, [Restriction endonuclease analysis of atypical ‘Aeromonas salmonicida’ isolates from goldfish ‘Carassius auratus’, silver perch ‘Bidyanus bidyanus’, and greenback flounder ‘Rhombosolea tapirina’ in Australia](#), *Diseases of Aquatic Organisms*

Piscirickettsiosis

Also known as infection with *Piscirickettsia salmonis*, salmonid rickettsial septicaemia

Exotic disease

Figure 81 Piscirickettsiosis in Atlantic salmon (*Salmo salar*)



Note: Pale circular granulomas in liver and pinpoint haemorrhaging in pyloric caeca.

Source: S Bravo

Signs of disease

Important: Animals with this disease may show one or more of these signs, but the pathogen may still be present in the absence of any signs.

Disease signs at the farm, tank or pond level are:

- increased mortality
- loss of appetite
- emaciation
- lethargic swimming
- circling
- swimming near the surface or at the sides of the net or pens.

Gross pathological signs are:

- progressive skin lesions that range from areas of raised scales, to white raised plaques, to shallow ulcers on flanks and head
- darkening of skin and pale gills
- swollen abdomen
- grey, swollen spleen and kidney
- mottled liver (due to diffuse haemorrhages) or ring-shaped white to pale-yellow lesions (granulomas and areas of necrosis)

- ascites (fluid in the abdominal cavity)
- signs of peritonitis, including generalised diffuse inflammation of abdominal organs, adhesions and increased volume of free abdominal fluid
- petechial (pinpoint) haemorrhages of the gastrointestinal tract, swim bladder and visceral fat.

Microscopic pathological signs are:

- vasculitis and necrosis of the liver and kidney; inflammatory macrophage infiltration
- *Rickettsia*-like organisms in macrophages and epithelial cells.

Disease agent

Piscirickettsiosis (also known as salmonid rickettsial septicaemia) is caused by infection with the bacterium *Piscirickettsia salmonis*, a member of the gammaproteobacteria, family *Piscirickettsiaceae*.

Host range

Table 35 Species known to be susceptible to piscirickettsiosis

Common name	Scientific name
Atlantic salmon ^a	<i>Salmo salar</i>
Black spot grouper	<i>Epinephelus melanostigma</i>
Chinook salmon ^a	<i>Oncorhynchus tshawytscha</i>
Coho salmon ^a	<i>Oncorhynchus kisutch</i> (most susceptible)
European seabass ^a	<i>Dicentrarchus labrax</i>
Masu salmon ^a	<i>Oncorhynchus masou</i>
Muskellunge	<i>Esox masquinongy</i>
Pink salmon ^a	<i>Oncorhynchus gorbuscha</i>
Rainbow trout ^a	<i>Oncorhynchus mykiss</i>
Tilapias	<i>Various genera and species</i>
White seabass	<i>Atractoscion nobilis</i>
Yellow perch	<i>Perca flavescens</i>

^a Susceptible to infection by *Piscirickettsia salmonis*. Note: Other species listed are infected by *Piscirickettsia*-like organisms.

Presence in Australia

Exotic disease—not recorded in Australia.

Piscirickettsiosis caused by *P. salmonis* has never been recorded in Australia and is considered exotic. However, Atlantic salmon cultured in seacages in Tasmania have been infected by a *Piscirickettsia*-like organism (Tas-RLO).

Map 21 Presence of *Piscirickettsia salmonis*, by jurisdiction



Epidemiology

- Salmonid rickettsial septicaemia describes diseases of salmonids caused by *Rickettsia*-like organisms, including *P. salmonis*. Piscirickettsiosis refers to the disease specifically caused by the bacterium *P. salmonis*. Related *Piscirickettsia*-like organisms can infect and cause disease in a range of fish species including cultured salmonids in Australia and New Zealand, tilapias cultured in waters up to 26°C in several countries, and white seabass and muskellunge in the USA.
- Outbreaks usually occur after fish are introduced to saltwater pens at water temperatures between 12°C and 18°C.
- Transmission is mainly horizontal (fish to fish). However, *P. salmonis* has been isolated from the reproductive organs of salmonids, and vertical transmission may explain outbreaks of this disease in freshwater areas following return of adult salmon from the sea to spawn.
- Bacteria are assumed to gain entry by breaching the physical barriers of the skin or gills. The invading bacteria then spread throughout the body via the blood (haematogenous spread), resulting in septicaemia.
- Mortality rates typically range between 10% and 30%, but have been recorded at 90% in seawater-raised coho salmon from Chile.

Differential diagnosis

The list of [similar diseases](#) in the next section refers only to the diseases covered by this field guide. Gross pathological signs may also be representative of diseases not included in this guide. Do not rely on gross signs to provide a definitive diagnosis. Use them as a tool to help identify the listed diseases that most closely account for the observed signs.

Similar diseases

Bacterial kidney disease (BKD) and infection with HPR-deleted or HPRO infectious salmon anaemia virus.

Sample collection

Only trained personnel should collect samples. Using only gross pathological signs to differentiate between diseases is not reliable, and some aquatic animal disease agents pose a risk to humans. If you are not appropriately trained, phone your state or territory hotline number and report your observations. If you have to collect samples, the agency taking your call will advise you on the appropriate course of action. Local or district fisheries or veterinary authorities may also advise on sampling.

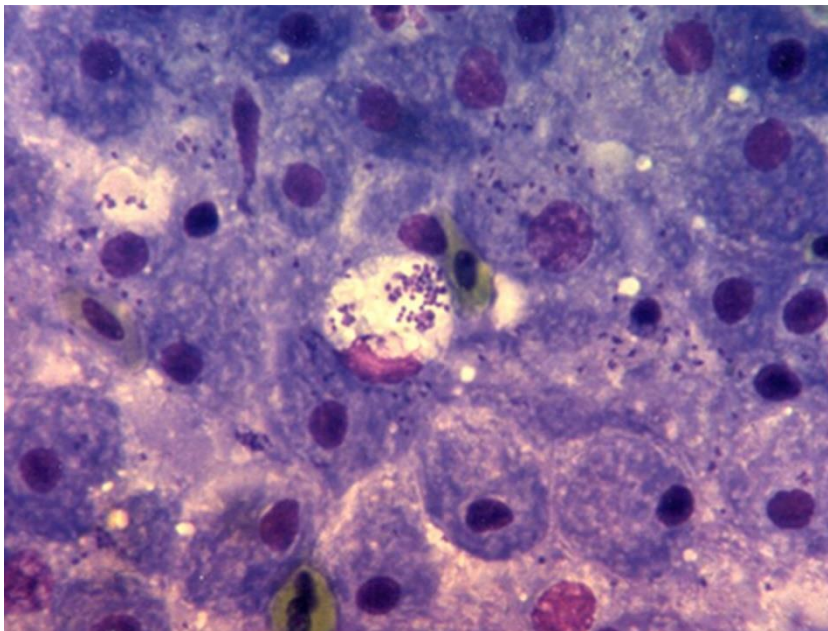
Emergency disease hotline

See something you think is this disease? Report it. Even if you're not sure.

Call the Emergency Animal Disease Watch Hotline on **1800 675 888**. They will refer you to the right state or territory agency.

Microscope images

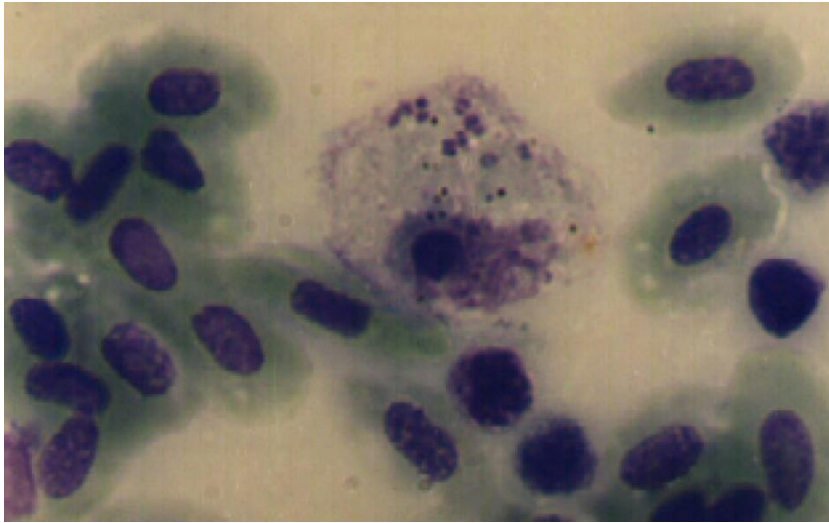
Figure 82 Piscirickettsiosis in Atlantic salmon (*Salmo salar*)



Note: Many bacteria (*P. salmonis*) evident in the tissue imprint.

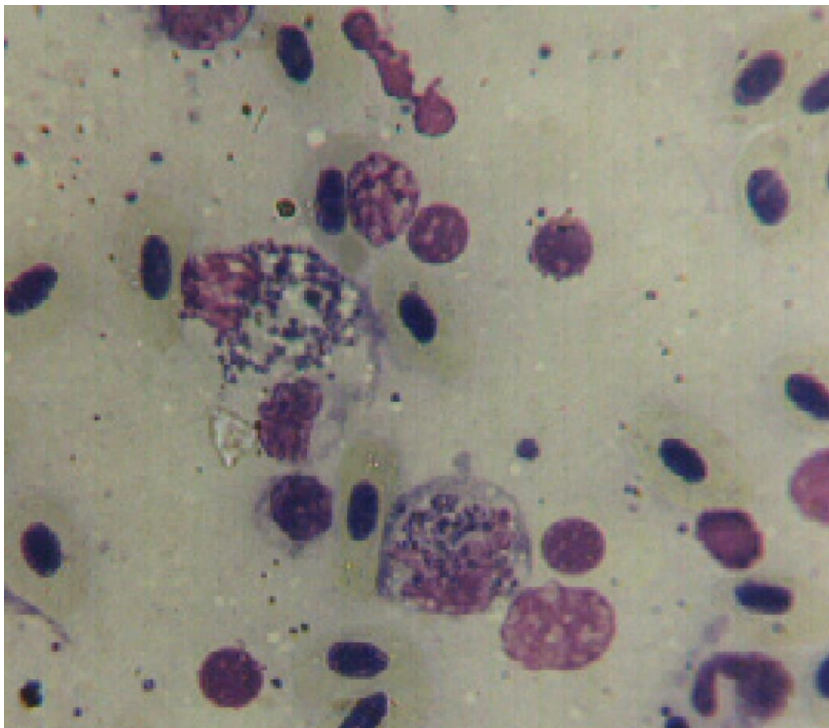
Source: European Association of Fish Pathologists

Figure 83 Stained blood smear from Atlantic salmon (*Salmo salar*) with piscirickettsiosis



Note: Several *P. salmonis* bacteria evident in the cytoplasm of an inflammatory cell.
Source: S Bravo

Figure 84 Stained blood smear from Atlantic salmon (*Salmo salar*) with piscirickettsiosis



Note: Large numbers of *P. salmonis* evident within several inflammatory cells.
Source: S Bravo

Further reading

CABI Invasive Species Compendium [Piscirickettsiosis](#)

CEFAS International Database on Aquatic Animal Diseases [Piscirickettsiosis](#)

Department of Agriculture [AQUAVETPLAN disease strategy manual: Piscirickettsiosis](#)

Parasitic diseases of finfish

Infection with *Gyrodactylus salaris*

Also known as gyrodactylosis

Exotic disease

Figure 85 Juvenile Atlantic salmon (*Salmo salar*) infected with *Gyrodactylus salaris*



Note: Excessive mucous and peeling of skin, especially around the tail.

Source: T Håstein

Signs of disease

Important: Animals with this disease may show one or more of these signs, but the pathogen may still be present in the absence of any signs.

Disease signs at the farm, tank or pond level are:

- lethargy
- high mortality in Atlantic salmon (*Salmo salar*)
- scrubbing (rubbing against objects in response to skin irritation) and flashing (darting and twisting of fish and erratic swimming)
- gathering in low-current waters when heavily infected.

Gross pathological signs are:

- ulcers
- sloughing of the skin
- greyish appearance; as disease progresses, dorsal and pectoral fins may have a whitish appearance due to thickening of the epidermis
- excess mucus on skin
- frayed fins.

There are no definitive microscopic pathological signs. Most waters have many types of monogenean flukes that are parasitic on fish gills and skin. Any evidence of infestation with these parasites beyond

what is visible to the naked eye requires identification by a parasitologist experienced in identifying *Gyrodactylus* species.

Disease agent

Gyrodactylosis is caused by infection with *Gyrodactylus salaris*, an obligate freshwater ectoparasitic flatworm (*Platyhelminthes*) belonging to the family *Gyrodactylidae* (class Monogenea). *G. salaris* occurs in Europe, mainly around the Baltic Sea and Norway.

Host range

All species of salmonids should be considered potentially susceptible to infection by *G. salaris*, unless future testing suggests otherwise.

Table 36 Species known to be naturally susceptible to *Gyrodactylus salaris*

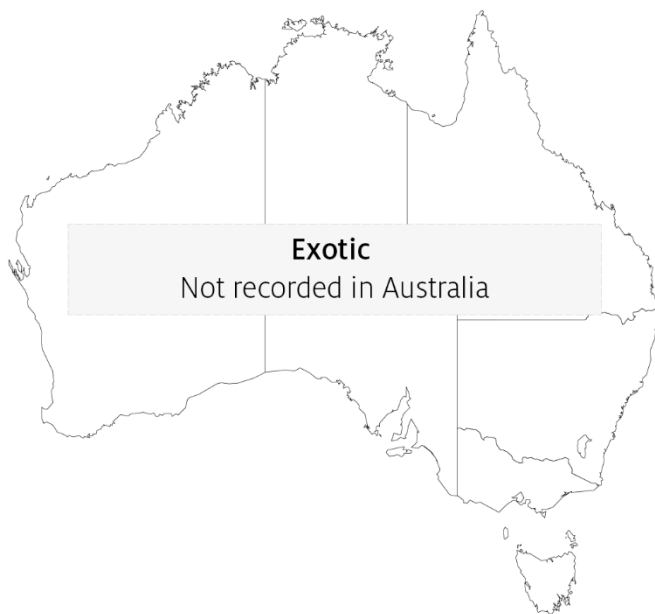Common name	Scientific name
Arctic char	<i>Salvelinus alpinus</i>
Atlantic salmon	<i>Salmo salar</i>
Brook trout	<i>Salvelinus fontinalis</i>
Brown trout ^a	<i>Salmo trutta</i>
Grayling	<i>Thymallus thymallus</i>
Lake trout	<i>Salvelinus namaycush</i>
Rainbow trout	<i>Oncorhynchus mykiss</i>
Salmonids (all presumed susceptible)	<i>Salmonidae</i> , all species

^a Susceptibility of brown trout is very low; *G. salaris* will usually only establish in a brown trout population co-existing with infected salmonids. Note: Other species not listed have been shown to be experimentally susceptible.

Presence in Australia

Exotic disease—not recorded in Australia.

Map 22 Presence of *Gyrodactylus salaris*, by jurisdiction



Epidemiology

- *Gyrodactylus salaris* may be present for years in farmed salmonids, especially rainbow trout, without the fish showing any clinical signs of disease.
- *Gyrodactylus salaris* is a freshwater parasite that cannot survive in seawater. However, it can survive a few days at salinity of up to 20 ppt.
- The parasite can survive 5 to 6 days detached from the host but cannot survive drying out.
- Transmission is horizontal (directly via the water column) by contact between infected and uninfected fish, or by contact between host fish and detached parasites on the substrate.
- Mortality in susceptible farmed Atlantic salmon can reach 100%.
- The parasite is readily spread between farms and countries through the transport of infected fish.

Differential diagnosis

The list of [similar diseases](#) in the next section refers only to the diseases covered by this field guide. Gross pathological signs may also be representative of diseases not included in this guide. Do not rely on gross signs to provide a definitive diagnosis. Use them as a tool to help identify the listed diseases that most closely account for the observed signs.

Similar diseases

Many diseases listed in this field guide appear similar to infection with *G. salaris*. Further laboratory diagnosis is required for any presumptive diagnosis.

Sample collection

Only trained personnel should collect samples. Using only gross pathological signs to differentiate between diseases is not reliable, and some aquatic animal disease agents pose a risk to humans. If you are not appropriately trained, phone your state or territory hotline number and report your observations. If you have to collect samples, the agency taking your call will advise you on the appropriate course of action. Local or district fisheries or veterinary authorities may also advise on sampling.

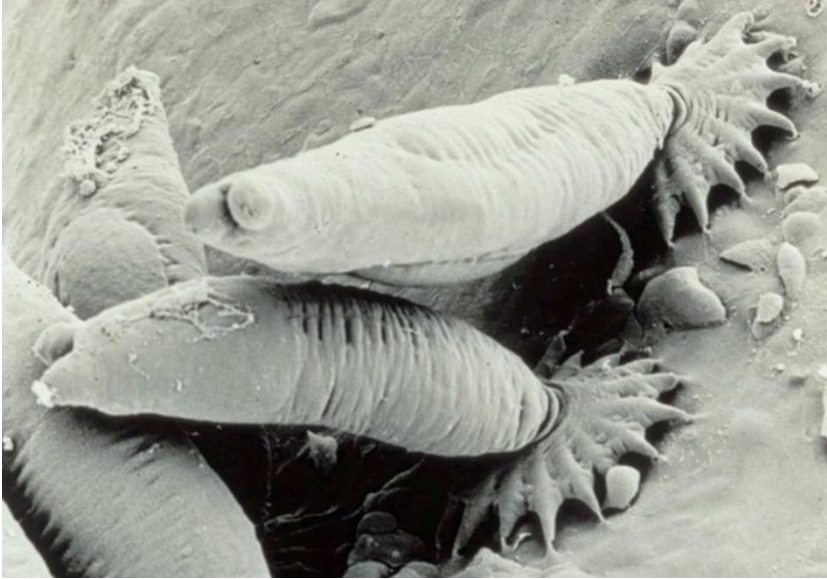
Emergency disease hotline

See something you think is this disease? Report it. Even if you're not sure.

Call the Emergency Animal Disease Watch Hotline on **1800 675 888**. They will refer you to the right state or territory agency.

Microscope images

Figure 86 Scanning electron micrograph of *Gyrodactylus salaris* attached to skin of juvenile Atlantic salmon (*Salmo salar*)



Note: Several parasites attached to the fish skin with their posterior attachment organ (opisthaptor).
Source: TA Mo

Further reading

CABI Invasive Species Compendium [‘Gyrodactylus salaris’](#)

World Organisation for Animal Health [Manual of diagnostic tests for aquatic animals](#)

Whirling disease

Also known as infection with *Myxobolus cerebralis*

Exotic disease

Figure 87 Skull deformity in rainbow trout (*Oncorhynchus mykiss*) with whirling disease



Note: Deformed skull resulting from long-term infection.

Source: T Håstein


Figure 88 Skeletal deformities in rainbow trout (*Oncorhynchus mykiss*) with whirling disease



Note Typical skeletal deformities caused by infection with *Myxobolus cerebralis*.

Source: J Bartholomew

Figure 89 Discolouration of rainbow trout (*Oncorhynchus mykiss*) with whirling disease



Note: Classic darkening of the skin from vent to tail.

Source: T Poppe

Figure 90 Discolouration of rainbow trout (*Oncorhynchus mykiss*) with whirling disease



Note Classic darkening of the skin from vent to tail.

Source: J Bartholomew

Signs of disease

Important: Animals with this disease may show one or more of these signs, but the pathogen may still be present in the absence of any signs.

Disease signs at the farm, tank or pond level are:

- mass mortalities in fry
- convulsive movements
- increased respiratory rate
- jerking backwards movements
- swimming with a whirling motion (tail chasing)
- erratic, nervous darting movements until exhausted.

Gross pathological signs are:

- darkening of the skin from the vent to the tail (blacktail)
- spinal curvature, skull deformation and shortened gill plates.

Microscopic pathological signs are:

- myxospores and other developmental stages within the cartilage of the cranium and axial skeleton of juvenile fish.

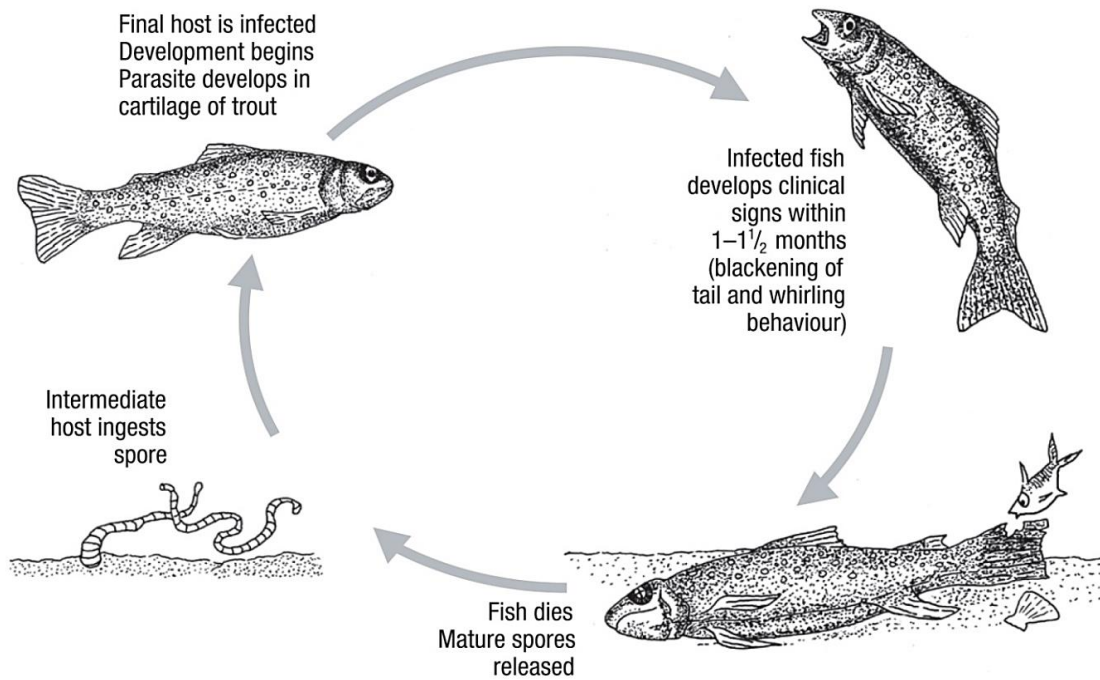
Disease agent

Whirling disease is caused by infection with *Myxobolus cerebralis*, a parasitic myxosporean that affects salmonids. *Myxosporean* parasites are multicellular disease agents related to cnidarians, most of which have a multi-host lifecycle including fish (or amphibians) and aquatic invertebrate hosts (particularly annelids).

Life cycle

- *Myxobolus cerebralis* has a complex life cycle (Figure 91) involving two hosts: fish (trout or salmon species) and an intermediate host, the tiny bottom-dwelling tubifex mud worm (*Tubifex tubifex*).
- *Myxobolus* spores (myxospores) develop in infected fish and are released into the environment when the fish dies. The myxospores are very persistent and can survive in moist environments for many years.
- Myxospores are ingested from the environment by tubifex mud worms. The spores rapidly multiply in the worm's intestine.
- A fragile waterborne spore stage of the parasite (triacinomyxon stage) is released from an infected intermediate host and infects a definitive host (fish). This must occur within the survival window of the triacinomyxon stage (over 2 weeks at 15°C). The parasite then migrates through the fish skin into the central nervous system, and ultimately into the cartilage.
- Following death and decomposition of infected fish, myxospores are released into the environment and the life cycle continues.
- Spores survive passing through the digestive tract of predators (such as piscivorous birds), and can be transferred from place to place on muddy boots, waders and other equipment.

Figure 91 Life cycle of *Myxobolus cerebralis*



Note: The lifecycle of *M. cerebralis* is indirect and requires a tubificid worm as the intermediate host.

Host range

Rainbow trout are considered to be the species most susceptible to whirling disease.

The presence of clinical signs depends on many factors, particularly the age of the primary host of the initial infection. For example, infected rainbow trout older than 9 weeks will generally show no clinical signs and chinook salmon do not exhibit clinical signs of disease beyond the age of 3 weeks.

Tubifex worms (*T. tubifex*) are known intermediate hosts that are present in Australia.

Table 37 Species of fish known to be naturally susceptible to whirling disease

Common name	Scientific name
Atlantic salmon	<i>Salmo salar</i>
Brook trout	<i>Salvelinus fontinalis</i>
Brown trout	<i>Salmo trutta</i>
Bull trout	<i>Salvelinus confluentus</i>
Chinook salmon	<i>Oncorhynchus tshawytscha</i>
Coho salmon	<i>Oncorhynchus kisutch</i>
Cutthroat trout	<i>Oncorhynchus clarkii</i>
Danube salmon	<i>Hucho hucho</i>
Gila trout	<i>Oncorhynchus gilae</i>
Golden trout	<i>Oncorhynchus aguabonita</i>
Mountain whitefish	<i>Prosopium williamsoni</i>
Rainbow trout ^a	<i>Oncorhynchus mykiss</i> (most susceptible)
Sockeye salmon	<i>Oncorhynchus nerka</i>

Note: Other species not listed have been shown to be experimentally susceptible.

Table 38 Non-fish carriers

Common name	Scientific name
Annelids	Various genera and species
Tubifex worms ^a	<i>Tubifex tubifex</i>
Piscivorous birds	Various genera and species

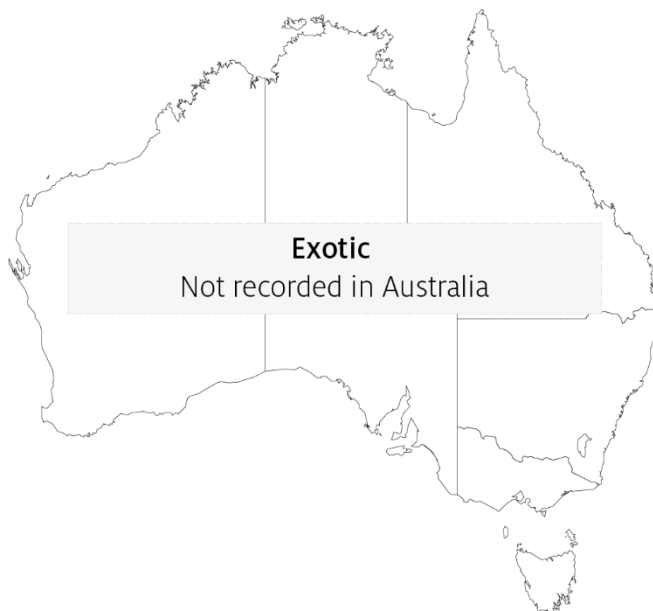^a Required intermediate host.

Presence in Australia

Exotic disease—not recorded in Australia.

Myxobolus cerebralis has not been recorded in Australia, and is considered exotic. However, various other species of *Myxobolus* have been recorded in marine and freshwater fish.

Map 23 Presence of whirling disease, by jurisdiction



Epidemiology

- Whirling disease is chronic and primarily affects young fish.
- Susceptibility is influenced by water temperature, age and species.
- Young fish are highly susceptible because the parasite attacks their soft cartilage, resulting in nerve damage, skeletal deformities and sometimes death.
- Clinical signs of the disease are not evident until fish are approximately 7cm long.
- When fish are 8 to 10cm long, cartilage forms into bone and they are no longer susceptible to disease; however they remain carriers of the parasite.
- The intermediate host, the annelid worm *T. tubifex*, is found in Australia.
- Because Tubifex worms live in mud, the disease can be partly controlled in trout farms by growing young fish in concrete raceways.

- The parasite spreads mainly through the stocking of infected fish and through the alimentary tracts of fish-eating migratory birds.
- *Myxobolus cerebralis* is highly resistant in the myxospore stage. The myxospore released from the fish can withstand freezing and desiccation, and may survive in a stream for up to 30 years with appropriate environmental conditions. However, the triactinomyxon infective stage released from the worm is short lived (up to 2 to 3 weeks at 15°C) and susceptible to standard disinfection procedures.

Differential diagnosis

The list of [similar diseases](#) in the next section refers only to the diseases covered by this field guide. Gross pathological signs may also be representative of diseases not included in this guide. Do not rely on gross signs to provide a definitive diagnosis. Use them as a tool to help identify the listed diseases that most closely account for the observed signs.

Similar diseases

Enteric red mouth disease (ERMD), infectious haematopoietic necrosis (IHN) and viral haemorrhagic septicaemia (VHS).

Sample collection

Only trained personnel should collect samples. Using only gross pathological signs to differentiate between diseases is not reliable, and some aquatic animal disease agents pose a risk to humans. If you are not appropriately trained, phone your state or territory hotline number and report your observations. If you have to collect samples, the agency taking your call will advise you on the appropriate course of action. Local or district fisheries or veterinary authorities may also advise on sampling.

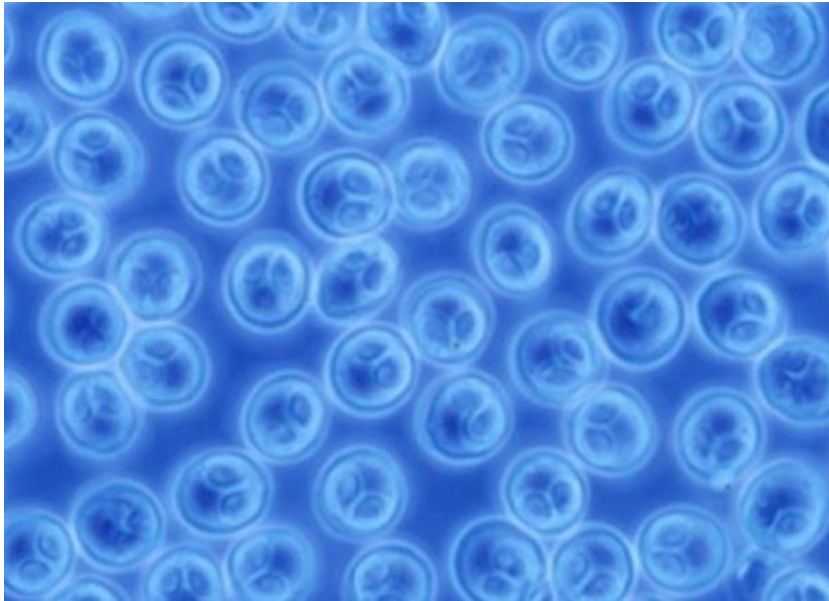
Emergency disease hotline

See something you think is this disease? Report it. Even if you're not sure.

Call the Emergency Animal Disease Watch Hotline on **1800 675 888**. They will refer you to the right state or territory agency.

Microscope images

Figure 92 Phase micrograph of *Myxobolus cerebralis* myxospores from infected rainbow trout (*Oncorhynchus mykiss*) cranial cartilage



Note Spores measure approximately 10µm in diameter. Extracted by the pepsin trypsin digest method.
Source: J Bartholomew

Further reading

CABI Invasive Species Compendium '[Myxobolus cerebralis](#)' ([whirling disease agent](#))

Department of Agriculture [AQUAVETPLAN disease strategy manual: Whirling disease](#)

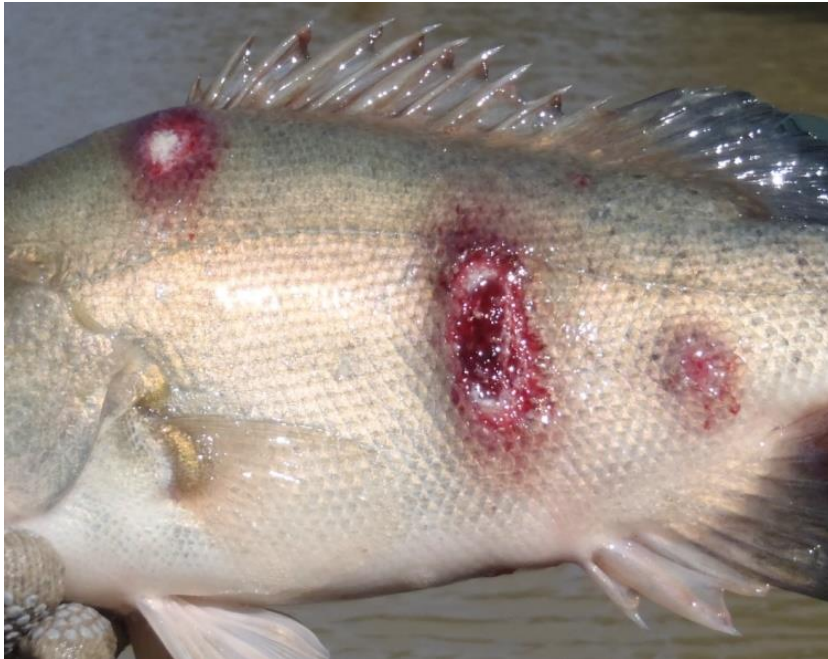Elwell LC, Stromberg KE, Ryce EK, Bartholomew JL 2009, 'Whirling disease in the United States: a summary of progress and research and management 2009', *Trout Unlimited*

Other diseases of finfish

Infection with *Aphanomyces invadans*


Also known as epizootic ulcerative syndrome (EUS), red spot disease (RSD), ulcerative mycosis (UM) and mycotic granulomatosis

Figure 93 EUS in golden perch (*Macquaria ambigua*)



Note: Multiple ulcerative lesions on flanks caused by infection with *Aphanomyces invadans*.
Source: C Boys

Figure 94 EUS in spangled perch (*Leiopotherapon unicolour*)



Note Focal haemorrhagic ulcerative lesions (a) will progress to a deep ulcer (b).
Source: C Boys

Figure 95 EUS in sand whiting (*Sillago ciliata*)



Note: Progression of red lesion (top) to deep ulcer (bottom) of classical red sores on the body.
Source: NSW Department of Primary Industries

Signs of disease

Important: Animals with this disease may show one or more of these signs, but the pathogen may still be present in the absence of any signs.

Disease signs at the farm, tank or pond level are:

- loss of appetite
- dark body colour
- mass mortality
- erratic swimming
- rubbing on the surfaces of tanks
- increased respiratory rate and effort.

Gross pathological signs are:

- lesions on the body showing as red spots, black burn-like marks or deeper ulcers with red centres and white rims
- progressive lesions
 - lesions start as reddening under a single scale but quickly spread to involve adjacent scales
 - lesions continue to widen and deepen, forming ulcers that erode underlying tissues to expose (depending on infection location) skeletal musculature, vertebrae, brain or viscera.
- unilateral or bilateral clouding of the eye (particularly in barramundi).

Microscopic pathological signs are:

- erythematous dermatitis
- hyphae (fungal threads) associated with granulomatous tissue, sometimes extending into visceral organs
- liquefactive necrosis of muscle tissue.

Disease agent

Infection with the oomycete fungus *Aphanomyces invadans* causes a disease called epizootic ulcerative syndrome (EUS); also known as red spot disease (RSD), ulcerative mycosis (UM) or mycotic granulomatosis. Although previously regarded as a fungus, the genus *Aphanomyces* is now classified with diatoms and brown algae in a group called Stramenopiles or Chromista.

Host range

More than 100 estuarine and freshwater species of fish are known to be susceptible to infection with *A. invadans*.

Table 39 Species in Australia known to be susceptible to *Aphanomyces invadans*

Common name	Scientific name
Australian bass ^a	<i>Macquaria novemaculeata</i>
Archerfish ^a	<i>Toxotes chatareus</i>
Banded archerfish ^a	<i>Toxotes jaculatrix</i>
Barcoo grunter ^a	<i>Scortum barcoo</i>
Barramundi ^a	<i>Lates calcarifer</i>
Bony bream ^a	<i>Nematalosa erebi</i>
Chanda perch ^a	<i>Ambassis agassizii</i>
Cichlids ^a	<i>Cichlidae</i>
Climbing perch ^a	<i>Anabas testudineus</i>
Cyprinids ^a	<i>Cyprinidae</i>
Dusky flathead ^a	<i>Platycephalus fuscus</i>
Eastern freshwater cod	<i>Maccullochella ikei</i>
Eels	<i>Anguillidae</i> all species
Estuarine rockcod ^a	<i>Epinephelus tauvina</i>
Flathead goby ^a	<i>Glossogobius giuris</i>
Fork-tailed catfish	<i>Arius</i> spp.
Froggatt's catfish	<i>Cinetodus froggatti</i>
Giant glassfish ^a	<i>Parambassis gulliveri</i>
Giant grouper	<i>Epinephelus lanceolatus</i>
Giant gudgeon ^a	<i>Oxyeleotris selheimi</i>
Goldfish	<i>Carassius auratus auratus</i>
Golden perch	<i>Macquaria ambigua</i>
Grouper and estuary cod ^a	<i>Epinephelus</i> spp.

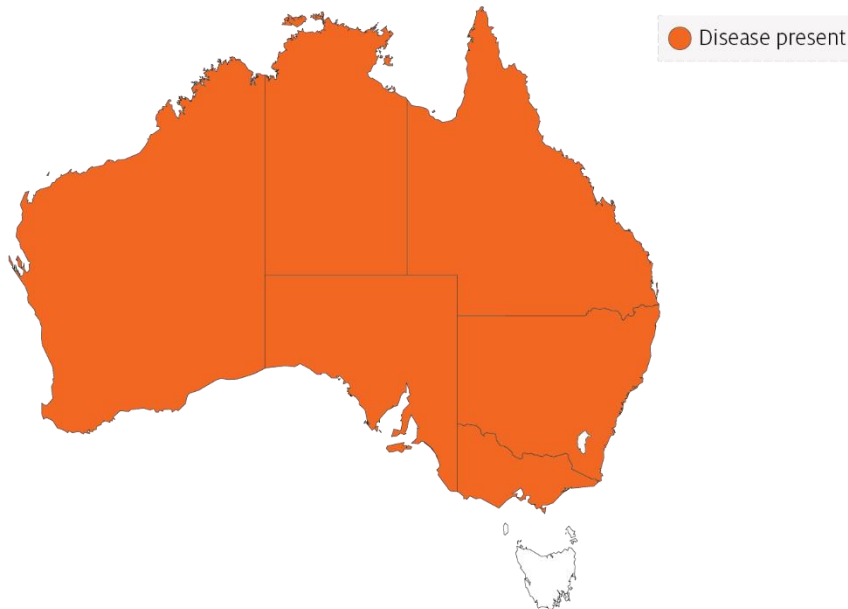
Common name	Scientific name
Long tom ^a	<i>Strongylura krefftii</i>
Mangrove jack ^a	<i>Lutjanus argentimaculatus</i>
Mouth almighty ^a	<i>Glossamia aprion</i>
Sea mullet ^a	<i>Mugil cephalus</i>
Mulletts ^a	<i>Mugilidae</i>
Murray cod	<i>Maccullochella peelii</i>
Nurseryfish	<i>Kurtus gulliveri</i>
Primitive archer fish ^a	<i>Toxotes lorentzi</i>
Rainbow fish ^a	<i>Melanotaenia splendida</i>
Rainbow trout	<i>Oncorhynchus mykiss</i>
Saratoga ^a	<i>Scleropages jardini</i>
Scat ^a	<i>Scatophagus argus</i>
Shortfin eel ^a	<i>Anguilla australis</i>
Silver perch ^a	<i>Bidyanus bidyanus</i>
Silver trevally ^a	<i>Pseudocaranx dentex</i>
Sleepy cod ^a	<i>Oxyeleotris lineolatus</i>
Striped grunter ^a	<i>Amniataba percoides</i>
Spangled perch ^a	<i>Leiopotherapon unicolor</i>
Triangular shield catfish ^a	<i>Neoarius leptaspis</i>
Tropical two-winged flying fish ^a	<i>Exocoetus volitans</i>
Whiting ^a	<i>Sillago ciliata</i>
Yellowfin bream ^a	<i>Acanthopagrus australis</i>

a Naturally susceptible. Note: Other species have been shown to be experimentally susceptible. A current list of known susceptible species found both within and outside of Australia is included in the World Organisation for Animal Health [Manual of diagnostic tests for aquatic animals](#).

Presence in Australia

EUS is endemic in many freshwater catchments and estuaries in Australia. The disease has been officially reported from New South Wales, the Northern Territory, Queensland, Victoria, South Australia and Western Australia.

Map 24 Presence of *Aphanomyces invadans*, by jurisdiction



Epidemiology

- The disease is seen in more than 100 freshwater and estuarine species of fish and infection has spread rapidly throughout Asia, associated with the movement of ornamental fish.
- Predisposing factors leading to skin damage (such as parasites, bacterial or viral infection, physical trauma or acidic water) are normally required to allow the *Aphanomyces* oomycete to initiate clinical signs of EUS. Secondary opportunistic infections are also a common finding.
- Disease is often associated with acid water run-off and can appear after heavy rains (particularly after a long dry period) with water temperatures of 18°C to 22°C favouring sporulation.
- Disease transmission is through zoospore transfer in freshwater, direct contact between fish and skin contamination (penetration assisted by damage to skin).
- Zoospores can encyst if they do not find a host, and can survive for at least 19 days.
- Water salinity above 2 ppt can stop the spread of this obligate freshwater disease agent.

Differential diagnosis

The list of [similar diseases](#) in the next section refers only to the diseases covered by this field guide. Gross pathological signs may also be representative of diseases not included in this guide. Do not rely on gross signs to provide a definitive diagnosis. Use them as a tool to help identify the listed diseases that most closely account for the observed signs.

Similar diseases

Enteric septicaemia of catfish, grouper iridoviral disease, infection with *Aeromonas salmonicida*—atypical strains, koi herpesvirus disease (KHV), viral haemorrhagic septicaemia (VHS) and tilapia lake virus (TiLV) disease.

Sample collection

Only trained personnel should collect samples. Using only gross pathological signs to differentiate between diseases is not reliable, and some aquatic animal disease agents pose a risk to humans. If you are not appropriately trained, phone your state or territory hotline number and report your observations. If you have to collect samples, the agency taking your call will advise you on the appropriate course of action. Local or district fisheries or veterinary authorities may also advise on sampling.

Emergency disease hotline

See something you think is this disease? Report it. Even if you're not sure.

Call the Emergency Animal Disease Watch Hotline on **1800 675 888**. They will refer you to the right state or territory agency.

Further reading

CABI Invasive Species Compendium [Epizootic ulcerative syndrome](#)

Network of Aquaculture Centres in Asia–Pacific [Epizootic ulcerative syndrome: Disease card](#)

World Organisation for Animal Health [Manual of diagnostic tests for aquatic animals](#)

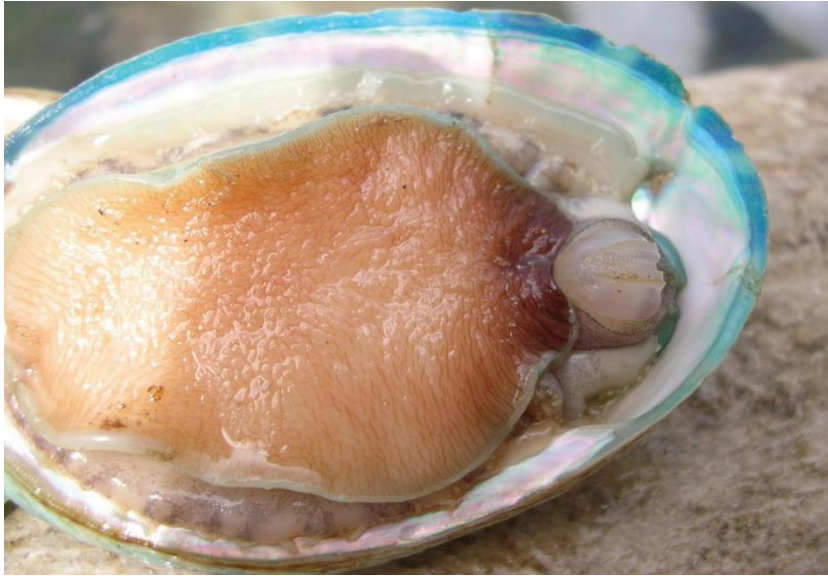3. Diseases of molluscs

Viral diseases of molluscs

Abalone viral ganglioneuritis (AVG)

Also known as infection with abalone herpesvirus (AbHV), infection with haliotid herpesvirus 1 (HaHV-1) and abalone viral mortality

Figure 96 Greenlip abalone (*Haliotis laevis*) with AVG



Note: Swollen and protruding mouth parts, particularly the prominent radula (toothed chitinous ribbon). The retracted (curled) foot margins expose bare shell beneath.

Source: Victorian Department of Primary Industries

Figure 97 Healthy greenlip abalone (*Haliotis laevis*)



Note: No evidence of any protruding mouth parts or foot curl.

Source: Victorian Department of Primary Industries

Figure 98 Foot of tiger hybrid greenlip × blacklip abalone (*Haliotis rubra* × *H. laevigata*) with AVG



Note: Blistering of foot (lesion near forceps).

Source: L Williams, CSIRO Australian Animal Health Laboratory

Signs of disease

Important: Animals with this disease may show one or more of these signs, but the pathogen may still be present in the absence of any signs.

Disease signs at the farm, tank or pond level are:

- rapid and high cumulative mortality of up to 90%
- inability to adhere to the substrate
- inability of individuals to right themselves when upside down.

Gross pathological signs are:

- swollen and protruding mouth parts
- reduced activity of the pedal muscle
- edges of the foot curled inwards, leading to exposure of clean, shiny shell
- tetany or 'hard foot', sometimes with blistering
- excessive mucous production
- abnormal spawning and bloating.

Microscopic pathological signs are:

- inflammation and necrosis of neural tissue.

Disease agent

AVG is caused by infection with abalone herpesvirus (AbHV), also known as haliotid herpesvirus 1 or HaHV-1. The virus is a member of the *Haliotivirus* genus in the family *Malacoherpesviridae*.

Host range

Several species of abalone are known to be susceptible to infection with AbHV. However, the New Zealand paua (*Haliotis iris*) appears highly resistant to infection.

Table 40 Species known to be naturally susceptible to infection with AbHV

Common name	Scientific name
Blacklip abalone ^a	<i>Haliotis rubra</i>
Brownlip abalone	<i>Haliotis conicopora</i>
Disc abalone ^a	<i>Haliotis discus hannai</i>
Diversicolor or jiucong abalone ^a	<i>Haliotis diversicolor</i>
Greenlip abalone ^a	<i>Haliotis laevigata</i>
Pink abalone	<i>Haliotis corrugata</i>
Tiger abalone ^a	<i>Haliotis rubra</i> × <i>laevigata</i>

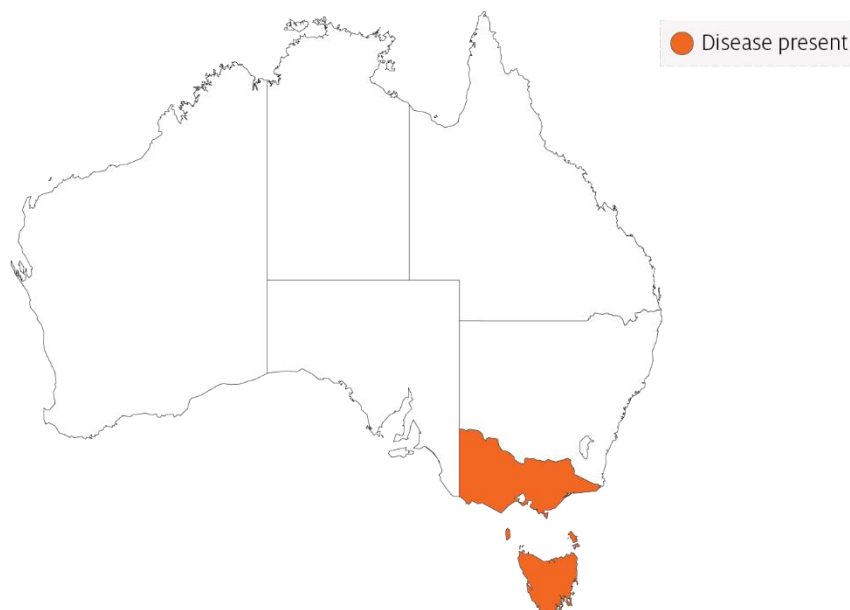^a Naturally susceptible. Note: Other species have been shown to be experimentally susceptible.

Presence in Australia

Victoria and Tasmania have officially reported the presence of AVG. In Victoria, AVG has been observed in farmed and wild abalone.

In Tasmania, the disease has not been observed in wild abalone populations. However, AbHV has been detected in wild abalone and the disease has been observed in abalone held in holding facilities and aquaculture facilities.

Map 25 Presence of AbHV, by jurisdiction



Epidemiology

- AVG affects the nervous system of abalone.
- AVG affects abalone of all ages.
- Horizontal transmission has been demonstrated by:
 - exposing healthy abalone to water containing diseased abalone in the same tank, but without direct contact between the diseased and healthy abalone
 - placing healthy abalone in water that was previously inhabited by diseased abalone
 - intramuscular injection of healthy abalone with a filtered tissue homogenate from diseased abalone.
- Mortality can occur within 4 days of infection and within 1 to 2 days following the onset of clinical signs.
- Apparently healthy wild-caught abalone subjected to sensitive molecular diagnostic tests have tested positive for the virus.
- At least 5 variants of AbHV have been identified: Vic1, Tas1, Tas2, Tas3 and Tas4. All virus variants cause disease and mortality in all Australian native abalone stocks tested to date.

Differential diagnosis

The list of [similar diseases](#) in the next section refers only to the diseases covered by this field guide. Gross pathological signs may also be representative of diseases not included in this guide. Do not rely on gross signs to provide a definitive diagnosis. Use them as a tool to help identify the listed diseases that most closely account for the observed signs.

Similar diseases

No diseases in this field guide are similar to Abalone viral ganglioneuritis.

Sample collection

Only trained personnel should collect samples. Using only gross pathological signs to differentiate between diseases is not reliable, and some aquatic animal disease agents pose a risk to humans. If you are not appropriately trained, phone your state or territory hotline number and report your observations. If you have to collect samples, the agency taking your call will advise you on the appropriate course of action. Local or district fisheries or veterinary authorities may also advise on sampling.

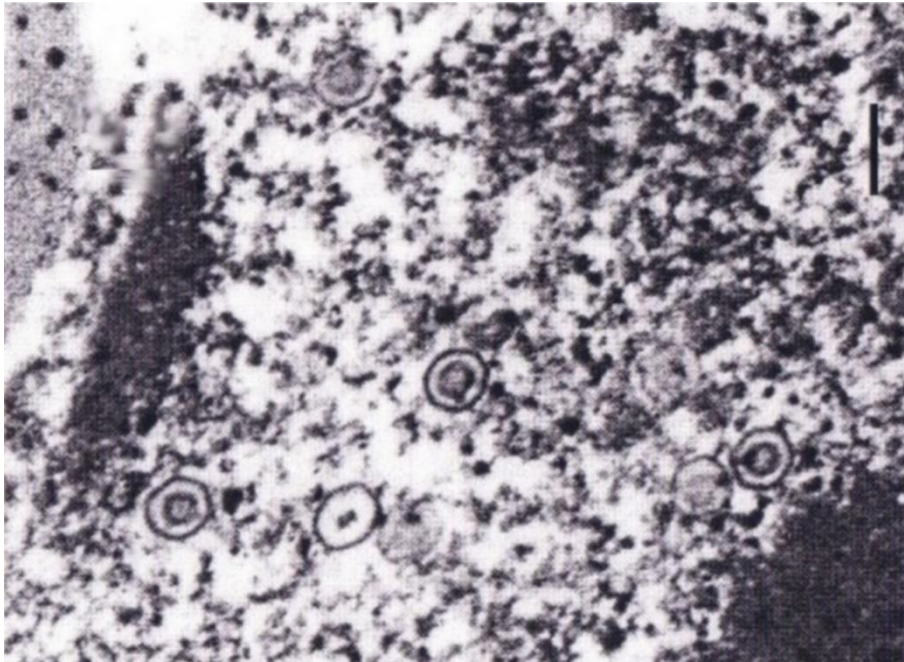
Emergency disease hotline

See something you think is this disease? Report it. Even if you're not sure.

Call the Emergency Animal Disease Watch Hotline on **1800 675 888**. They will refer you to the right state or territory agency.

Microscope images

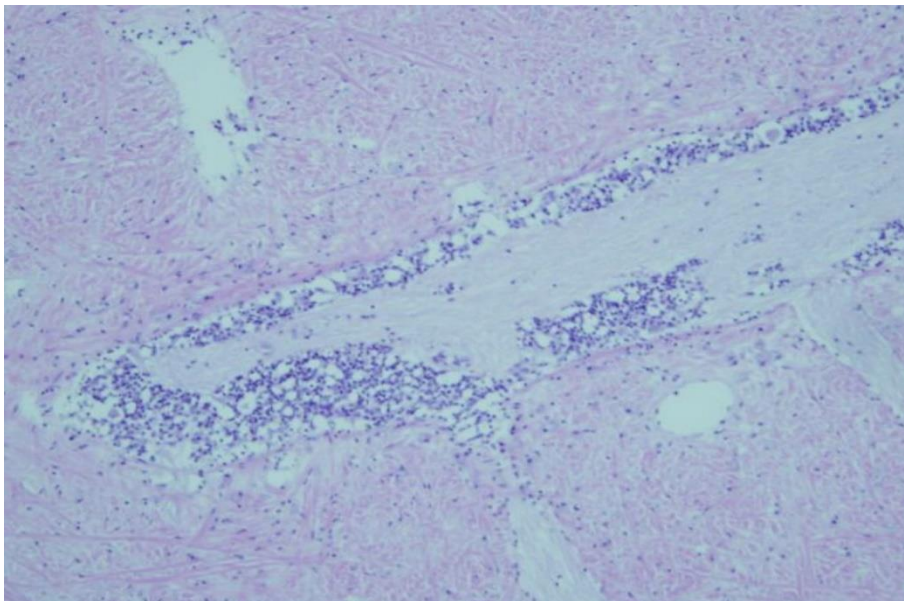
Figure 99 Electron micrograph of AbHV responsible for causing AVG



Note: Several enveloped herpesvirus particles are visible.

Source: CSIRO Australian Animal Health Laboratory

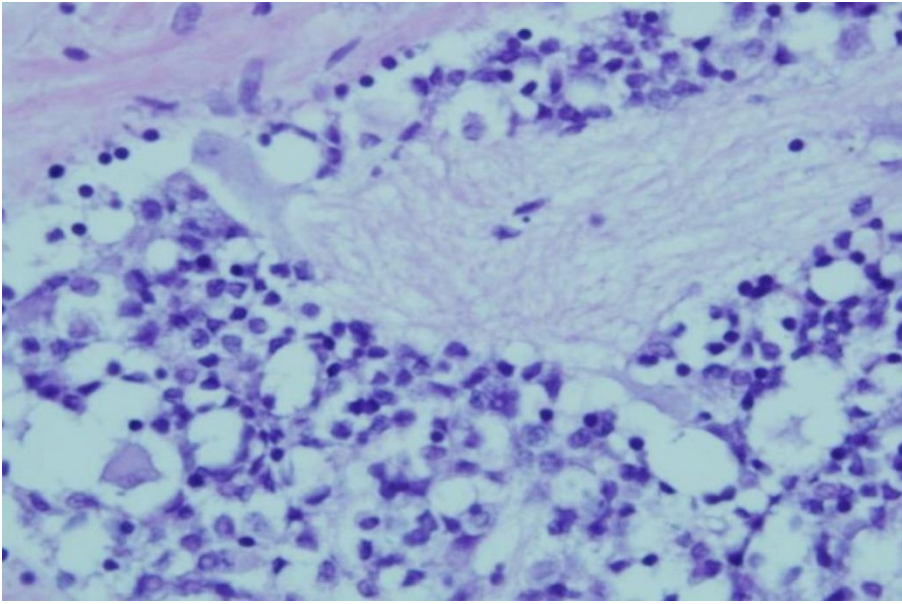
Figure 100 Histological section of foot of abalone with clinical AVG



Note: Florid inflammatory response (darker spots) around the nerve ganglia is typical of clinical AVG.

Source: Victorian Department of Primary Industries

Figure 101 Higher magnification histological section of foot of abalone with clinical AVG



Note: Higher magnification of bottom left quadrant of Figure 100. Shows numerous inflammatory cells surrounding the affected nerve ganglion.

Source: Victorian Department of Primary Industries

Further reading

CEFAS International Database on Aquatic Animal Diseases [Infection with abalone herpesvirus](#)

Department of Agriculture [AQUAVETPLAN disease strategy manual: Abalone viral ganglioneuritis](#)

World Organisation for Animal Health [Manual of diagnostic tests for aquatic animals](#)

Infection with ostreid herpesvirus-1 microvariant (OsHV-1 μ var)

Also known as Pacific oyster mortality syndrome (POMS)

Figure 102 Juvenile Pacific oysters (*Crassostrea gigas*) infected with OsHV-1 μ var



Note: Large number of dead juvenile oysters resulting from mass mortality due to infection with OsHV-1 μ var.

Source: The University of Sydney

Signs of disease

Important: Animals with this disease may show one or more of these signs, but the pathogen may still be present in the absence of any signs.

Disease signs at the farm, tank or pond level are:

- rapid and high cumulative mortalities in Pacific oysters, approaching 100% within 8 to 10 days of infection.

Gross pathological signs are:

- cessation of feeding and swimming by larvae, which exhibit velar lesions
- gaping in adults
- pale digestive gland in spat and older oysters.

Microscopic pathological signs are:

- ulcerative and erosive lesions in the connective tissue of mantle, gills, labial palps and digestive tissue
- nuclear hypertrophy, nuclear chromatin margination and pyknosis
- inflammatory changes ranging from mild and localised, to severe and extensive.

Disease agent

POMS is caused by infection with a microvariant genotype of ostreid herpesvirus-1 (OsHV-1 μ var). The virus is the only member of the genus *Ostreavirus* (family *Malacoherpesviridae*, order *Herpesvirales*).

Host range

Pacific oysters and Portuguese oysters are known to be susceptible to infection with OsHV-1 μ var. Multiple bivalve species (cupped oysters, flat oysters, clams, scallops) are known to be susceptible to other genotypes of OsHV-1. Several of these may also act as carriers and reservoirs for the microvariant strains.

Table 41 Species known to be susceptible to infection with OsHV-1 μ var

Common name	Scientific name
Blue mussel	<i>Mytilus edulis</i>
Hairy mussels	<i>Trichomya hirsuta</i>
Mediterranean mussel	<i>Mytilus galloprovincialis</i>
Pacific oyster ^a	<i>Crassostrea gigas</i>
Portuguese oyster ^a	<i>Crassostrea angulata</i>
Sydney cockle or mud arc	<i>Anadara trapezia</i>
Sydney rock oyster	<i>Saccostrea glomerata</i>

^a Naturally susceptible. Note: Other species have been shown to be potential reservoir hosts.

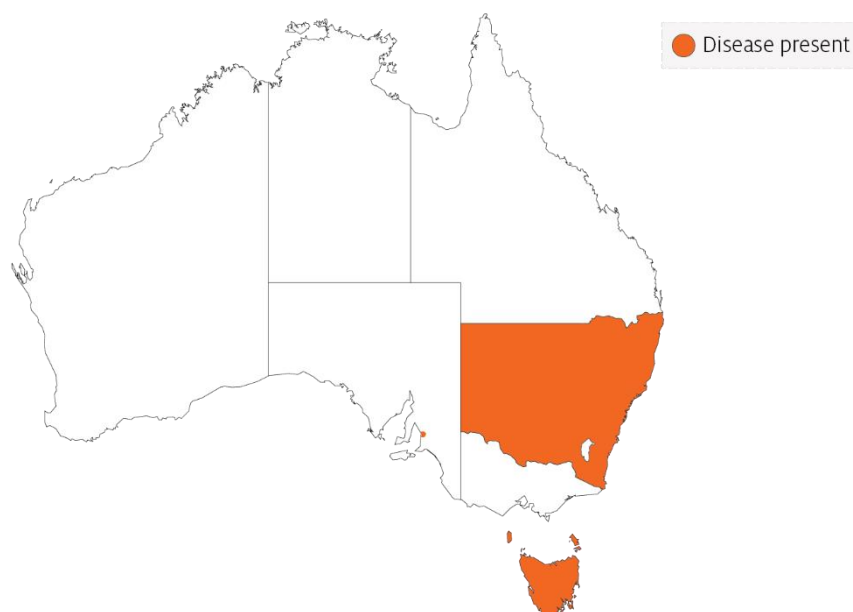Table 42 Non-bivalve carriers

Common name	Scientific name
Barnacles	<i>Balanus</i> spp.
Mud whelks	<i>Pyrazus</i> spp., <i>Batillaria</i> spp.

Presence in Australia

Outbreaks of POMS due to infection with OsHV-1 μ var have been officially reported from oyster growing areas in several regions of New South Wales and Tasmania. Pacific oysters infected with OsHV-1 μ var have also been reported from wild Pacific oysters in Port Adelaide in South Australia.

Map 26 Presence of OsHV-1 μ var, by jurisdiction



Epidemiology

- The disease can affect all age groups of susceptible oysters. There may be higher mortality in the younger life stages.
- Higher mortality appears to be associated with higher water temperature and crowding.
- Infected adult oysters may be a source of infection for larvae or spat. However, it is not certain if true vertical transmission occurs. Horizontal transmission has been demonstrated.
- Some adult *Crassostrea gigas* may survive with subclinical OsHV-1 infections, and act as carriers of the virus.
- The introduction of OsHV-1 μ var into new areas is thought to be due to introduction of infected hosts or carriers in biofouling on shipping, often followed by human movements of subclinically infected oysters.
- Water filtration reduces risk of disease entry into hatcheries, suggesting spread of the disease within a water body may be due to movements of infected oyster larvae or free virus adhered to plankton or other particles.

Differential diagnosis

The list of [similar diseases](#) in the next section refers only to the diseases covered by this field guide. Gross pathological signs may also be representative of diseases not included in this guide. Do not rely on gross signs to provide a definitive diagnosis. Use them as a tool to help identify the listed diseases that most closely account for the observed signs.

Similar diseases

Iridoviroses.

Sample collection

Only trained personnel should collect samples. Using only gross pathological signs to differentiate between diseases is not reliable, and some aquatic animal disease agents pose a risk to humans. If you are not appropriately trained, phone your state or territory hotline number and report your observations. If you have to collect samples, the agency taking your call will advise you on the appropriate course of action. Local or district fisheries or veterinary authorities may also advise on sampling.

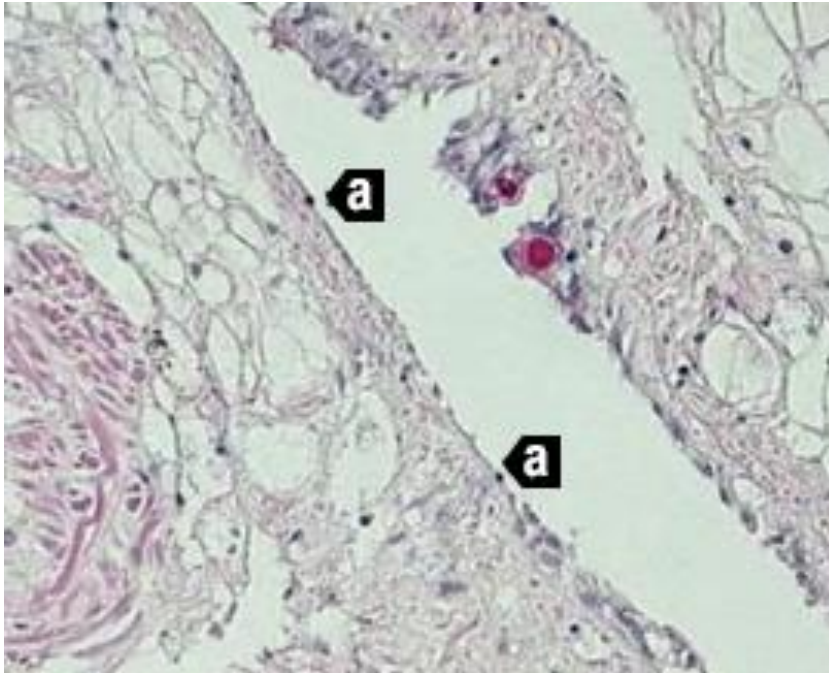
Emergency disease hotline

See something you think is this disease? Report it. Even if you're not sure.

Call the Emergency Animal Disease Watch Hotline on **1800 675 888**. They will refer you to the right state or territory agency.

Microscope images

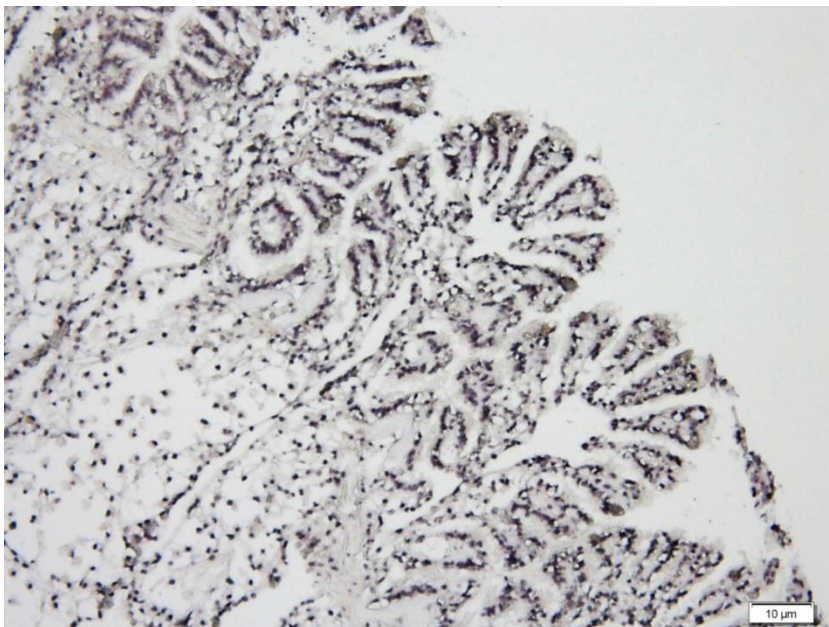
Figure 103 Histological section of Pacific oyster (*Crassostrea gigas*) infected with OsHV-1 μ var



Note: High viral load causing multifocal to coalescing ulceration with attenuation of epithelium and pyknotic nuclei (a). 20x magnification.

Source: M Gabor

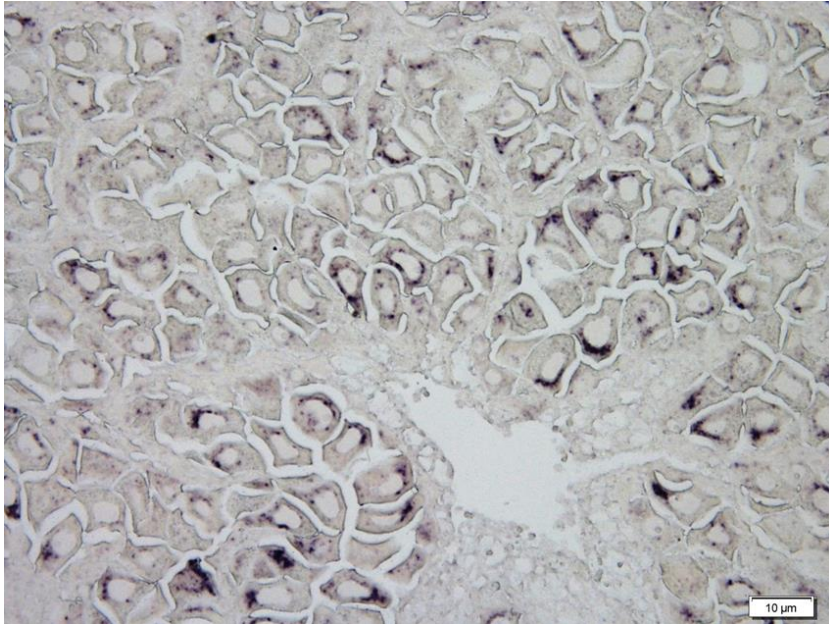
Figure 104 In-situ hybridisation of gill of Pacific oyster (*Crassostrea gigas*) infected with OsHV-1 μ var



Note: Massive infection of epithelia and connective tissues (black staining). Scale bar 10 μ m.

Source: C Jenkins

Figure 105 In-situ hybridisation of gonad of Pacific oyster (*Crassostrea gigas*) infected with OsHV-1 μ var



Note: Viral infection (black staining) in many eggs. Scale bar 10 μ m.

Source: C Jenkins

Further reading

CEFAS International Database on Aquatic Animal Diseases [Infection with ostreid herpesvirus 1 microvariant](#)

Department of Agriculture [AQUAVETPLAN disease strategy manual: Ostreid herpesvirus 1 microvariant](#)

World Organisation for Animal Health [Manual of diagnostic tests for aquatic animals](#)

Iridoviroses

Including gill necrosis virus, oyster velar virus disease, gill disease of Portuguese oysters and blister disease

Exotic disease

Figure 106 Gill necrosis virus in oyster



Note: Visible multifocal necrotic yellow or brown lesions in the gill tissue.

Source: D Alderman

Signs of disease

Important: Animals with this disease may show one or more of these signs, but the pathogen may still be present in the absence of any signs.

Disease signs at the farm, tank or pond level are:

- high mortality.

Gross pathological signs are:

- yellow or green pustules on mantle or adductor muscle
- yellow spots on gills and labial palps that spread as the disease progresses
- spots that increase in size and develop brown centres as the tissue dies, leaving a hole in the gill structure.

Microscopic pathological signs are:

- necrosis of gill or labial palp tissue
- massive haemocytic cellular infiltration around lesions
- basophilic cytoplasmic inclusions found in most lesions.

Disease agent

Iridoviroses are diseases caused by infection with one of several iridoviruses. Infections include gill necrosis virus, an icosahedral deoxyribonucleic acid (DNA) virus with affinities with the *Iridoviridae*.

Host range

Various species of oysters are known (or suspected) to be susceptible to infection with iridoviruses. It is reasonable to assume that the Sydney rock oyster (*Saccostrea glomerata*) is susceptible.

Table 43 Species known or suspected to be susceptible to infection with iridoviruses

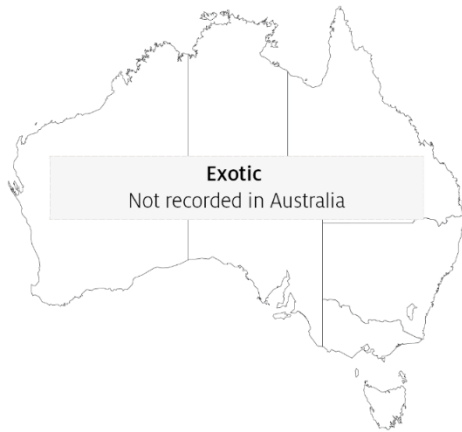Common name	Scientific name
European flat oyster ^a	<i>Ostrea edulis</i>
Pacific oyster ^a	<i>Crassostrea gigas</i>
Portuguese oyster ^a	<i>Crassostrea angulata</i>
Sydney rock oyster	<i>Saccostrea glomerata</i>

^a Naturally susceptible. Note: Other species are suspected to be susceptible.

Presence in Australia

Exotic disease—not recorded in Australia.

Map 27 Presence of iridoviroses, by jurisdiction



Epidemiology

- A number of iridoviruses that cause disease in oysters have been identified. Not all are associated with gill necrosis and some affect oysters at different life stages.
- Horizontal transmission occurs directly via the water column through the surface of the gills.
- Little is known about the distribution of the organisms responsible for this condition. However, molluscan iridoviruses are generally considered to be distributed in oceans worldwide.
- A protist, *Thankatostrea polymorpha* in the phylum Sarcomastigophora, has also been associated with this disease.
- Outbreaks usually occur in spring and sometimes in summer.
- Surviving oysters do not repair perforated gill structures and are potential carriers of the virus.

Differential diagnosis

The list of [similar diseases](#) in the next section refers only to the diseases covered by this field guide. Gross pathological signs may also be representative of diseases not included in this guide. Do not rely on gross signs to provide a definitive diagnosis. Use them as a tool to help identify the listed diseases that most closely account for the observed signs.

Similar diseases

Infection with ostreid herpesvirus-1 microvariant (OshV-1 μ var).

Sample collection

Only trained personnel should collect samples. Using only gross pathological signs to differentiate between diseases is not reliable, and some aquatic animal disease agents pose a risk to humans. If you are not appropriately trained, phone your state or territory hotline number and report your observations. If you have to collect samples, the agency taking your call will advise you on the appropriate course of action. Local or district fisheries or veterinary authorities may also advise on sampling.

Emergency disease hotline

See something you think is this disease? Report it. Even if you're not sure.

Call the Emergency Animal Disease Watch Hotline on **1800 675 888**. They will refer you to the right state or territory agency.

Further reading

CEFAS International Database on Aquatic Animal Diseases [Infection with Irido-like virosis](#)

Fisheries and Oceans Canada [Gill disease of Portuguese oyster](#)

Fisheries and Oceans Canada [Oyster velar virus disease](#)

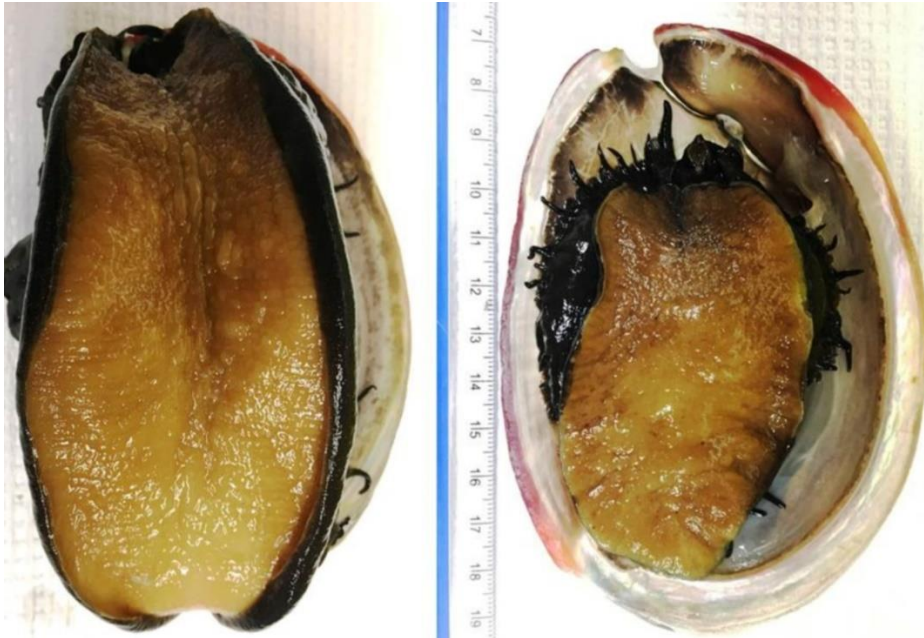
Bacterial diseases of molluscs

Infection with *Xenohaliotis californiensis*

Also known as withering syndrome of abalone (WS)

Exotic disease

Figure 107 Healthy red abalone (*Haliotis rufescens*), compared with atrophy of specimen with WS



Note: Infected abalone (right) shows severe atrophy or withering of foot muscle and retraction of mantle.

Source: J Moore

Signs of disease

Important: Animals with this disease may show one or more of these signs, but the pathogen may still be present in the absence of any signs.

Disease signs at the farm, tank or pond level are:

- reduced feeding
- inability of individuals to right themselves when upside down
- weakness and lethargy (clinging to horizontal surfaces rather than to vertical or inverted)
- inability to adhere to the substrate
- increased mortality.

Gross pathological signs are:

- wasting of body mass
- retraction of mantle
- atrophy of the foot muscle
- decreased response to tactile stimuli
- diminished reproductive output

- mottling of digestive gland (dark brown with small foci of tan-coloured tissue).

Microscopic pathological signs are:

- presence of intracellular bacteria in the cells of the digestive epithelia
- atrophy of digestive tubules
- increase in connective tissue, inflammation and metaplasia of the digestive gland.

Disease agent

WS is caused by the obligate intracellular bacterium *Xenohaliotis californiensis*. The bacterium is closely related to the *Neorickettsia* genus. It is the ancestral form of the family *Anaplasmataceae*, within the order Rickettsiales.

Host range

Five *Haliotis* species native to the Californian coast are known to be susceptible to infection with *X. californiensis*. Disease susceptibility profiles of other *Haliotis* species (including Australian species) to infection with *X. californiensis* has not been assessed, but appears likely. Assume that all Australian species of *Haliotis* are susceptible.

Table 44 Species known to be susceptible to infection with *Xenohaliotis californiensis*

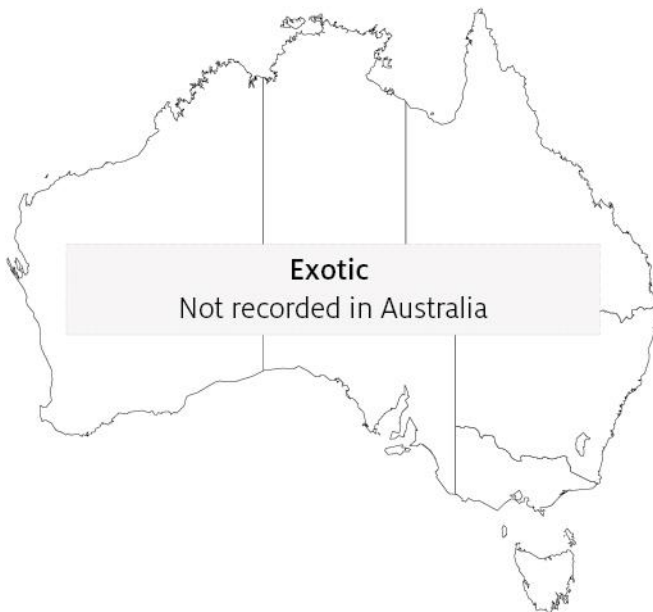Common name	Scientific name
Black abalone ^a	<i>Haliotis cracherodii</i>
Blacklip abalone	<i>Haliotis rubra</i>
Brownlip abalone	<i>Haliotis conicopora</i>
European abalone ^a	<i>Haliotis tuberculata</i>
Flat abalone	<i>Haliotis wallalensis</i>
Green abalone ^a	<i>Haliotis fulgens</i>
Greenlip abalone	<i>Haliotis laevigata</i>
Japanese abalone	<i>Haliotis discus hannai</i>
Pink abalone ^a	<i>Haliotis corrugata</i>
Red abalone ^a	<i>Haliotis rufescens</i>
Small abalone ^a	<i>Haliotis diversicolor supertexta</i>
Tiger abalone	<i>Haliotis rubra x laevigata</i>
White abalone ^a	<i>Haliotis sorenseni</i>

^a Naturally susceptible. Note: Other species likely to be susceptible or shown to be experimentally susceptible.

Presence in Australia

Exotic disease—not recorded in Australia.

Map 28 Presence of *Xenohaliotis californiensis*, by jurisdiction



Epidemiology

- The pathogen *X. californiensis* occurs in marine waters.
- The bacterium attacks the lining of the digestive tract, causing metaplastic cellular changes and apparently obstructing the production of digestive enzymes. As a result, the abalone starve and catabolise their musculature. This causes withering of the foot, which impairs their ability to adhere to substrates and makes them vulnerable to predation.
- Abalone not eaten by predators usually die from starvation.
- Susceptibility varies between species of abalone (99% cumulative decline in black abalone and 30% in red abalone since the disease was first observed in 1986).
- Abalone can be infected with the bacterium without developing the disease.
- Transmission occurs horizontally by cohabitation with infected abalone (via the faecal–oral route).
- Environmental stressors, such as elevated water temperature, may predispose carriers of the bacterium to disease. Survivors can remain carriers of the bacterium.
- The disease can be treated with antibiotics. Severity of the disease may be reduced by infection of *X. californiensis* with hyperparasitic bacteriophages, which can give the rickettsial inclusions a distinctively altered (pleomorphic) appearance.

Differential diagnosis

The list of [similar diseases](#) in the next section refers only to the diseases covered by this field guide. Gross pathological signs may also be representative of diseases not included in this guide. Do not rely on gross signs to provide a definitive diagnosis. Use them as a tool to help identify the listed diseases that most closely account for the observed signs.

Similar diseases

No diseases in this field guide are similar to infection with *Xenohaliotis californiensis*.

Sample collection

Only trained personnel should collect samples. Using only gross pathological signs to differentiate between diseases is not reliable, and some aquatic animal disease agents pose a risk to humans. If you are not appropriately trained, phone your state or territory hotline number and report your observations. If you have to collect samples, the agency taking your call will advise you on the appropriate course of action. Local or district fisheries or veterinary authorities may also advise on sampling.

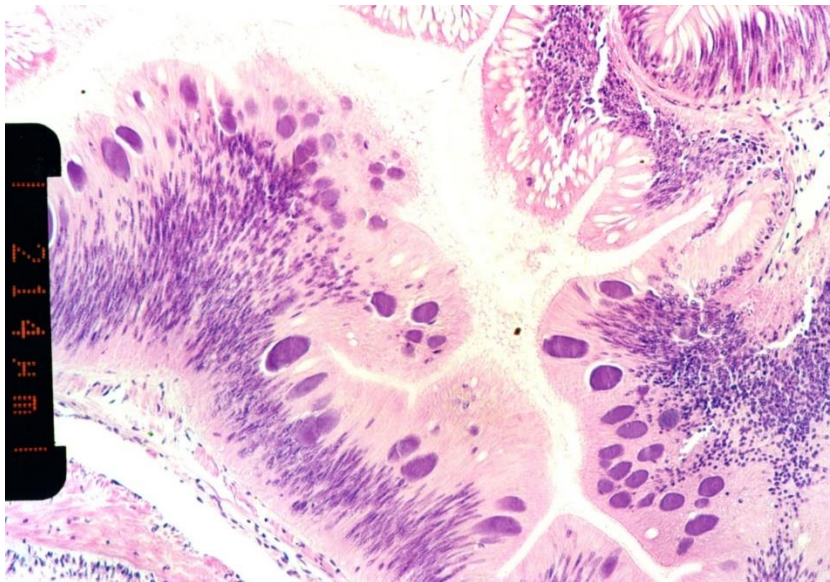
Emergency disease hotline

See something you think is this disease? Report it. Even if you're not sure.

Call the Emergency Animal Disease Watch Hotline on **1800 675 888**. They will refer you to the right state or territory agency.

Microscope images

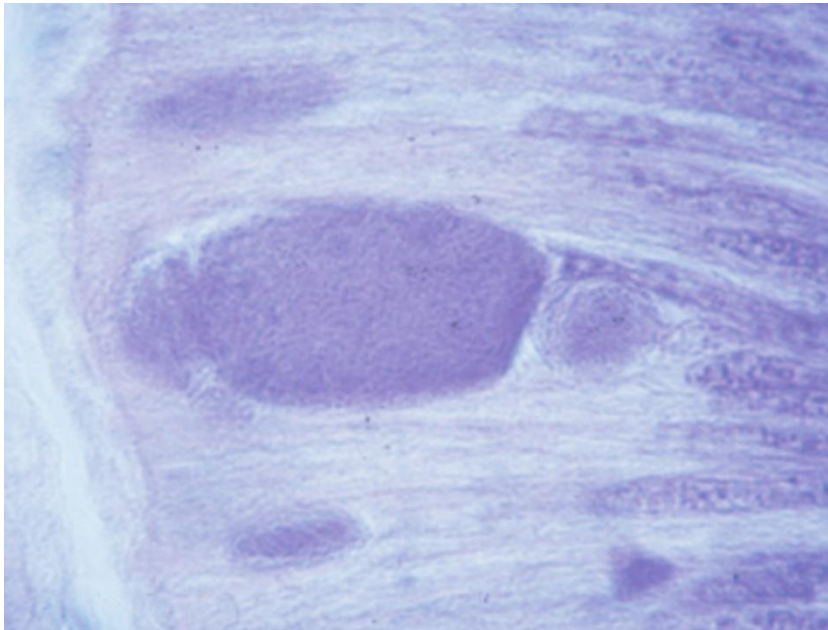
Figure 108 Histological section of postoesophagus tissue from farmed black abalone (*Haliotis cracherodii*) infected with *Xenohaliotis californiensis*



Note: Numerous basophilic inclusions in epithelial cells, each containing thousands of individual bacteria. Scale bar =214 µm.

Source: B Diggles

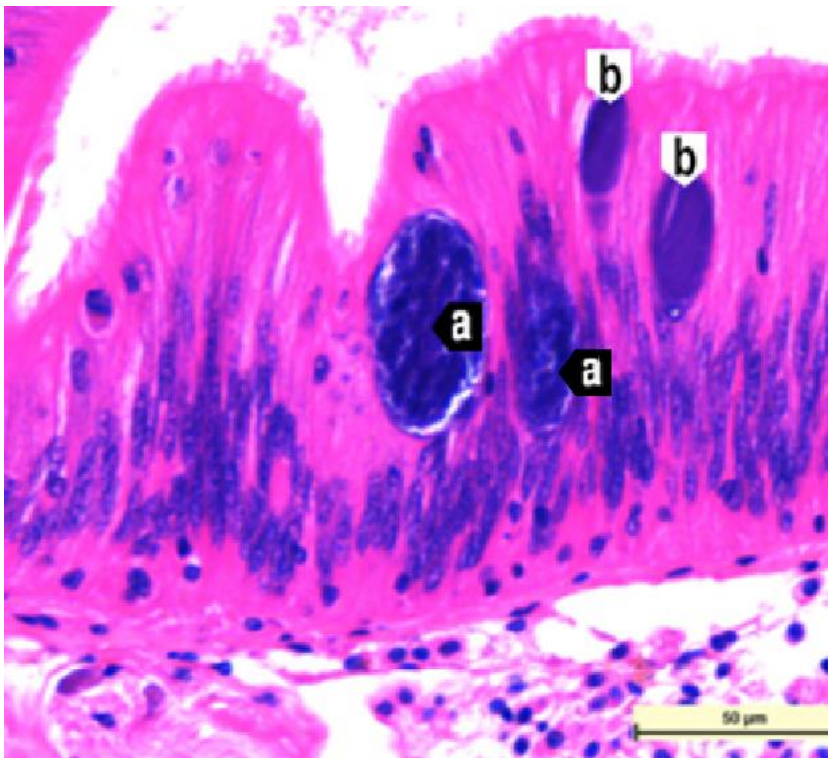
Figure 109 High power micrograph of epithelium of postoesophagus of red abalone (*Haliotis rufescens*) infected with *Xenohaliotis californiensis*



Note: Large basophilic cytoplasmic inclusion filled with *X. californiensis*.

Source: J Moore

Figure 110 Histological section of postoesophagus tissue of red abalone (*Haliotis rufescens*)



Note: The 2 larger pleomorphic *Xenohaliotis californiensis* inclusions (a) are infected by a bacteriophage. The 2 smaller inclusions (b) are normal. 40x magnification, scale bar = 50μm.

Source: J Moore

Further reading

CABI Invasive Species Compendium [‘Xenohaliotis californiensis’](#)

CEFAS International Database on Aquatic Animal Diseases [Infection with ‘Xenohaliotis californiensis’](#)

World Organisation for Animal Health [Manual of diagnostic tests for aquatic animals](#)

Parasitic diseases of molluscs

Infection with *Bonamia exitiosa*

Also known as bonamiosis

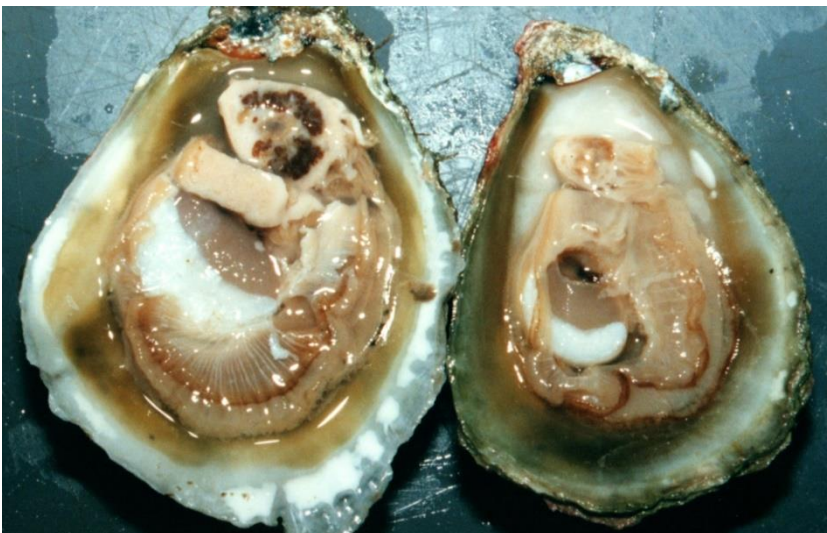Figure 111 Australian flat oysters (*Ostrea angasi*) infected with *Bonamia exitiosa*



Note: Gaping of oysters and high mortality rate due to infection with *Bonamia exitiosa*.

Source: B Diggles

Figure 112 New Zealand dredge oysters (*Ostrea chilensis*) with digestive gland sectioned



Note: Normal healthy oyster gland (left) compared with pale atrophied digestive gland of oyster with heavy *Bonamia exitiosa* infection (right).

Source: B Diggles

Signs of disease

Important: Animals with this disease may show one or more of these signs, but the pathogen may still be present in the absence of any signs.

Diseases caused by any of the microcell species are similar. In cases of light infection, few signs or no clinical or gross signs are present. Concurrent infections with more than one species of *Bonamia* may also occur. Definitive identification of *Bonamia* or *Mikrocytos* species requires histological laboratory examination and molecular diagnostic techniques.

Disease signs at the farm, tank or pond level are:

- dead or gaping oysters
- increased mortality.

Gross pathological signs are:

- stunted growth and poor condition
- weakened shell closure, leading to slight gaping
- watery flesh, pale atrophied digestive gland in clinically diseased oysters
- algae-covered shell lips after the mantle shrinks and no longer reaches the edges
- deformities of the gill margins.

Infection with *Bonamia exitiosa* rarely results in gross pathological signs of disease in oysters under natural conditions—most infections are asymptomatic.

Microscopic pathological signs are:

- microcell parasites within haemocytes and vesicular connective tissues (especially the gill or mantle)
- individual microcells are basophilic, spherical or ovoid parasites, 2 to 3µm in diameter
- microcells of *B. exitiosa* tend to be larger than those of *B. ostreae* when both occur in the same host
- In Australian flat oysters (*Ostrea angasi*), apparently low numbers of parasites cause massive focal haemocyte aggregation with necrotic foci.

Disease agent

Bonamiosis is caused by infection with *Bonamia exitiosa*. This is an intrahaemocytic protist classified in the order Haplosporidia (class Ascetosporea). It causes lethal infection of flat oysters. Recent evidence confirms that *B. exitiosa* that infects Australian flat oysters is the same species that infects dredge oysters (*O. chilensis*) in New Zealand.

Host range

Bonamia exitiosa is mainly a parasite of flat oysters. However, microcells that are occasionally visible in Pacific oysters have been confirmed to be *B. exitiosa* by PCR analysis. Sydney rock oysters may also occasionally be subclinical carriers of *B. exitiosa* and appear to harbour very low numbers of these parasites.

Table 45 Species known to be naturally susceptible to infection with *Bonamia exitiosa*

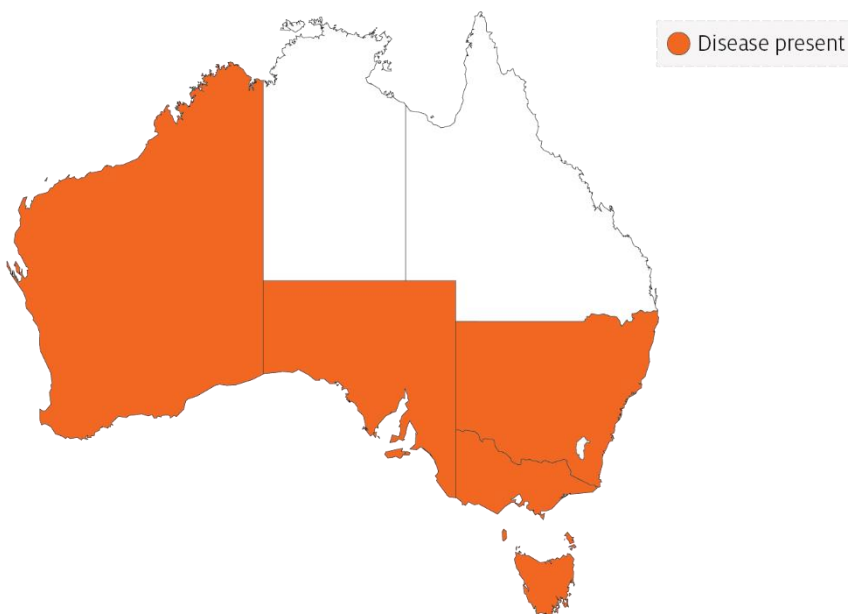
Common name	Scientific name
American eastern oyster	<i>Crassostrea virginica</i>
Argentinian flat oyster	<i>Ostrea puelchana</i>
Dwarf oyster	<i>Ostrea stentina</i>
European flat oyster	<i>Ostrea edulis</i>
New Zealand dredge oyster	<i>Ostrea chilensis</i>
Olympia oyster	<i>Ostrea lurida</i>
Pacific oyster	<i>Crassostrea gigas</i>
Southern mud oyster or Australian flat oyster	<i>Ostrea angasi</i>
Sydney rock oyster	<i>Saccostrea glomerata</i>

Presence in Australia

Bonamia exitiosa has been recorded in flat oysters in Victoria and New South Wales as well as in a very low percentage of Sydney rock oysters in New South Wales. It is likely that *Bonamia* spp. previously recorded in flat oysters in Tasmania, South Australia and Western Australia are also *B. exitiosa*.

Bonamia ostreae and other *Bonamia* spp. are exotic to Australia, so any differential diagnosis of *Bonamia* spp. infection in Australian oysters requires specific confirmation using molecular diagnostic techniques to differentiate between the endemic *B. exitiosa* and exotic *B. ostreae* and *Bonamia* spp.

Map 29 Presence of *Bonamia exitiosa*, by jurisdiction



Epidemiology

- Mortalities can occur all year, but the highest prevalence is in mid to late summer after the host spawns.
- The disease dynamics of *B. exitiosa* in the New Zealand dredge oyster can be affected by exposure to temperature extremes (below 7°C or above 26°C), high salinity (40ppt), starvation (prolonged holding in filtered seawater), handling (vigorous stirring 4 times per day) or heavy coinfection with apicomplexan protists.
- Cohabitation of infected and uninfected oysters in holding tanks facilitates horizontal transmission of infection to the uninfected oysters.
- A seasonal pattern of disease has been observed in New Zealand since 1964. Separate epizootics in 1985 to 1991 and 1998 to 2003 resulted in cumulative mortality of more than 90% in wild populations of New Zealand dredge oysters.
- Transmission is thought to occur from host to host via infective stages that are carried from one oyster bed to another by water currents.
- The introduction of *B. exitiosa* into New Zealand and Australia is thought to be due to introduction of infected hosts carried in biofouling on shipping, followed by human movements of subclinically infected oysters.

Differential diagnosis

The list of [similar diseases](#) in the next section refers only to the diseases covered by this field guide. Gross pathological signs may also be representative of diseases not included in this guide. Do not rely on gross signs to provide a definitive diagnosis. Use them as a tool to help identify the listed diseases that most closely account for the observed signs.

Similar diseases

Infection with *Bonamia ostreae*, infection with *Bonamia* spp. and infection with *Mikrocytos mackini*.

There are few or no visual cues to the presence of these diseases other than poor condition, shell gaping and increased mortality. Consequently, it is impossible to use gross signs alone to differentiate between infection by *Bonamia* species and *Mikrocytos*. Concurrent infections with more than one species of *Bonamia* may also occur. Any presumptive diagnosis requires further laboratory examination.

Light microscopy can contribute diagnostic information, but further laboratory examination and molecular diagnostic techniques are required for a definitive diagnosis.

Sample collection

Only trained personnel should collect samples. Using only gross pathological signs to differentiate between diseases is not reliable, and some aquatic animal disease agents pose a risk to humans. If you are not appropriately trained, phone your state or territory hotline number and report your observations. If you have to collect samples, the agency taking your call will advise you on the appropriate course of action. Local or district fisheries or veterinary authorities may also advise on sampling.

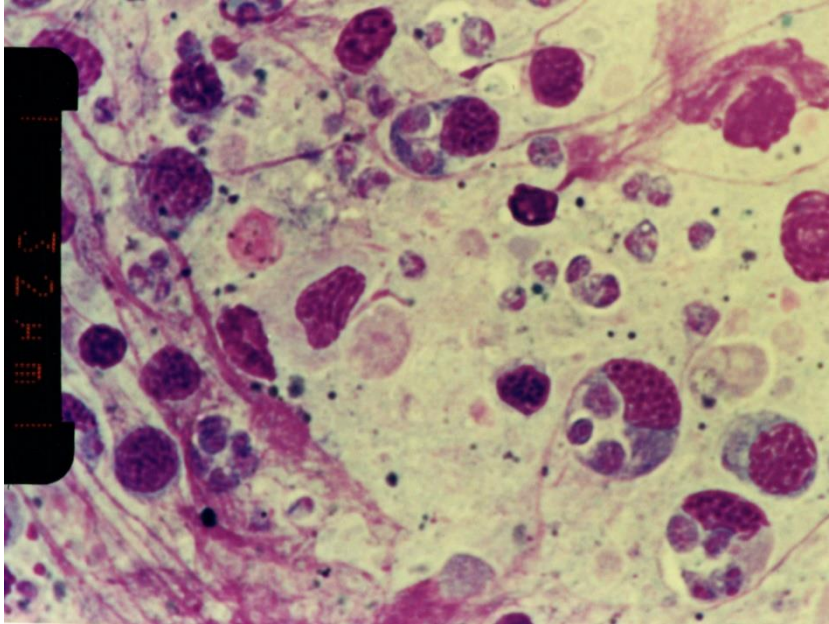
Emergency disease hotline

See something you think is this disease? Report it. Even if you're not sure.

Call the Emergency Animal Disease Watch Hotline on **1800 675 888**. They will refer you to the right state or territory agency.

Microscope images

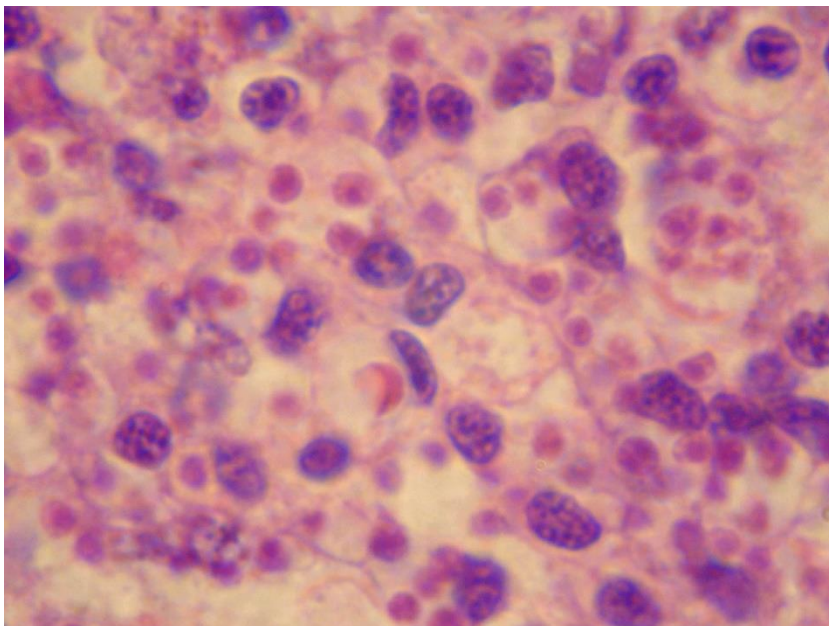
Figure 113 Stained heart imprint from New Zealand dredge oyster (*Ostrea chilensis*)



Note: Several microcells of *Bonamia exitiosa* within and outside haemocytes. Scale bar = 32µm.

Source: B Diggles

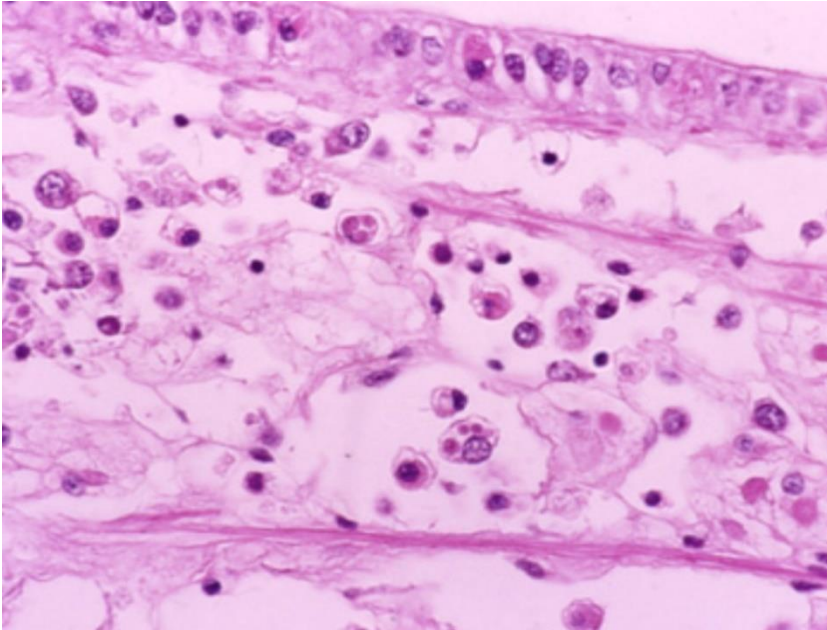
Figure 114 Histological section of heavy *Bonamia exitiosa* infection in vesicular connective (leydig) tissue of gonad of New Zealand dredge oyster (*Ostrea chilensis*)



Note: The pink spherical microcells of *B. exitiosa* are smaller than the basophilic host cell nuclei.

Source: B Diggles

Figure 115 Histological section through vesicular connective (leydig) tissue of New Zealand dredge oyster (*Ostrea chilensis*)



Note: Numerous circulating haemocytes, many containing *Bonamia exitiosa* (the small pink spheres in the haemocyte cytoplasm, smaller than a nucleus).

Source: B Jones

Further reading

CABI Invasive Species Compendium [Bonamiosis \('Bonamia exitiosa'\)](#)

CEFAS International Database on Aquatic Animal Diseases [Infection with 'Bonamia exitiosa'](#)

World Organisation for Animal Health [Manual of diagnostic tests for aquatic animals](#)

Infection with *Bonamia ostreae*

Also known as bonamiosis

Exotic disease

Figure 116 Mortality of European flat oysters (*Ostrea edulis*) infected with *Bonamia ostreae*



Note: Classic gaping of diseased oysters.

Source: D Alderman

Signs of disease

Important: Animals with this disease may show one or more of these signs, but the pathogen may still be present in the absence of any signs.

Diseases caused by any of the microcell species are similar. In cases of light infection, few or no clinical or gross signs are present. Concurrent infections with more than one species of *Bonamia* may also occur. Definitive identification of *Bonamia* or *Mikrocytos* species requires histological laboratory examination and molecular diagnostic techniques.

Disease signs at the farm, tank or pond level are:

- dead or gaping oysters
- increased mortality.

Gross pathological signs are:

- generally poor condition
- gills appearing eroded
- yellow discolouration of the gills and mantle.

Infection with *Bonamia ostreae* rarely results in gross pathological signs of disease in oysters. Often the only sign is increased mortality.

Microscopic pathological signs are:

- dense infiltrations of haemocytes, some containing microcell parasites in the connective tissue of the gill and mantle and in the vascular sinuses around the stomach and intestine
- extensive lesions, including perforated ulcers in the connective tissue of the gills, mantle and digestive gland.

Disease agent

Bonamiosis is caused by infection with *Bonamia ostreae*, an intrahaemocytic protist classified in the order Haplosporidia (class Ascetosporea). *B. ostreae* causes lethal infection of flat oysters.

Host range

B. ostreae is mainly a parasite of European flat oysters (*Ostrea edulis*). Australian flat oysters reared in France have been shown to be susceptible to *B. ostreae*. Microcells of *B. ostreae* are also occasionally detectable in cupped oysters (Pacific oysters, Portuguese oysters and Suminoe oysters) that co-occur in areas where *B. ostreae* epizootics occur in *O. edulis*.

Table 46 Species known to be naturally susceptible to infection with *Bonamia ostreae*

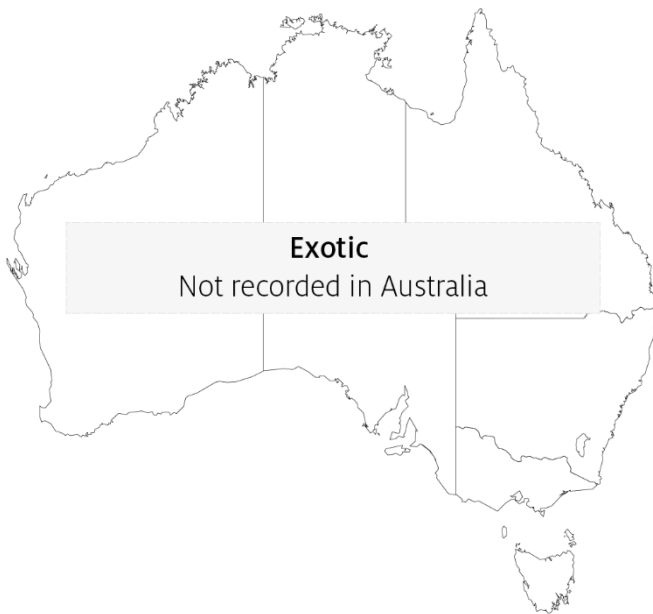Common name	Scientific name
Argentinian flat oyster	<i>Ostrea puelchana</i>
Asiatic oyster	<i>Ostrea denselammellosa</i>
European flat oyster	<i>Ostrea edulis</i>
New Zealand dredge oyster	<i>Ostrea chilensis</i>
Pacific oyster	<i>Crassostrea gigas</i>
Portuguese oyster	<i>Crassostrea angulata</i>
Southern mud oyster or Australian flat oyster	<i>Ostrea angasi</i>
Suminoe oyster	<i>Crassostrea ariakensis</i>

Presence in Australia

Exotic disease—not recorded in Australia.

Bonamia ostreae has not been recorded and is considered exotic to Australia. Any differential diagnosis of *Bonamia* spp. infection in Australian oysters requires specific confirmation using molecular diagnostic techniques to discriminate between the endemic *B. exitiosa* and exotic *B. ostreae* and *Bonamia* spp.

Map 30 Presence of *Bonamia ostreae*, by jurisdiction



Epidemiology

- The critical host age for development of disease appears to be 2 years. However, other age classes are susceptible to infection.
- Significant mortalities usually occur at water temperatures of 12 to 20°C.
- Systemic infection of haemocytes effectively starves the oyster of energy required for survival. The infected animal eventually dies from exhaustion and starvation.
- Some studies suggest that prevalence and intensity of infection increase during late winter and autumn. However, the disease may occur at any time during the year.
- The pre-patent period is up to 5 months.
- Horizontal transmission of the parasite can occur directly from host to host and indirectly between oyster beds via the water.
- *Bonamia ostreae* is thought to have spread from California to Europe by human movement of infected oysters. It has also been detected in New Zealand (including in concurrent infections with *B. exitiosa*) and was possibly introduced by infected hosts carried in biofouling on shipping.

Differential diagnosis

The list of [similar diseases](#) in the next section refers only to the diseases covered by this field guide. Gross pathological signs may also be representative of diseases not included in this guide. Do not rely on gross signs to provide a definitive diagnosis. Use them as a tool to help identify the listed diseases that most closely account for the observed signs.

Similar diseases

Infection with *Bonamia exitiosa*, infection with *Bonamia* spp. and infection with *Mikrocytos mackini*.

There are few or no visual cues to the presence of this disease other than poor condition, shell gaping and increased mortality. Consequently, it is impossible to use gross signs alone to differentiate between infection by *Bonamia* species and *Mikrocytos* species. Concurrent infections with more than one species of *Bonamia* may also occur. Any presumptive diagnosis requires further laboratory examination.

Light microscopy can contribute diagnostic information, but further laboratory examination and molecular diagnostic techniques are required for a definitive diagnosis.

Sample collection

Only trained personnel should collect samples. Using only gross pathological signs to differentiate between diseases is not reliable, and some aquatic animal disease agents pose a risk to humans. If you are not appropriately trained, phone your state or territory hotline number and report your observations. If you have to collect samples, the agency taking your call will advise you on the appropriate course of action. Local or district fisheries or veterinary authorities may also advise on sampling.

Emergency disease hotline

See something you think is this disease? Report it. Even if you're not sure.

Call the Emergency Animal Disease Watch Hotline on **1800 675 888**. They will refer you to the right state or territory agency.

Further reading

CABI Invasive Species Compendium '[Bonamia ostreae](#)'

CEFAS International Database on Aquatic Animal Diseases [Infection with 'Bonamia ostreae'](#)

World Organisation for Animal Health [Manual of diagnostic tests for aquatic animals](#)

Infection with *Bonamia* species

Also known as bonamiosis

Exotic disease

Signs of disease

Important: Animals with this disease may show one or more of these signs, but the pathogen may still be present in the absence of any signs.

Diseases caused by any of the microcell species are similar. In cases of light infection, few signs or no clinical or gross signs may be present. Concurrent infections with more than one species of *Bonamia* may also occur. Definitive identification of infection with *Bonamia* or *Mikrocytos* species requires histological laboratory examination and molecular diagnostic techniques.

Disease signs at the farm, tank or pond level are:

- dead or gaping oysters
- increased mortality.

Gross pathological signs are:

- stunted growth and poor condition
- weakened shell closure, leading to slight gaping
- watery flesh, pale atrophied digestive gland in clinically diseased oysters
- algae-covered shell lips after the mantle shrinks and no longer reaches the edges
- deformities to the gill margins.

Infection with *Bonamia* spp. rarely results in gross pathological signs of disease in oysters under natural conditions.—Most infections are asymptomatic.

Microscopic pathological signs are:

- microcell parasites in or near epithelia-may be in very low numbers
- microcells may also occur within haemocytes and vesicular connective tissues (especially the gill or mantle)
- individual microcells are basophilic, spherical or ovoid parasites, 2 to 3µm in diameter
- some species of exotic *Bonamia* spp. produce spores (such as *B. perspora*).

Disease agent

Bonamiosis is caused by infection with *Bonamia* spp., intrahaemocytic protists classified in the order Haplosporidia (class Ascetospora). Both flat and cupped oysters may become infected.

This disease listing includes *B. perspora* and unidentified *Bonamia* spp., but excludes *B. exitiosa* and *B. ostreae*, which are addressed in separate disease listings.

Host range

Table 47 Species known to be naturally susceptible to infection with *Bonamia* spp.

Common name	Scientific name
Crested oyster	<i>Ostrea equestris</i>
Dwarf oyster	<i>Ostrea stentina</i>
European flat oyster	<i>Ostrea edulis</i>
Hawaiian oyster	<i>Dendostrea sandvicensis</i>
New Zealand dredge oyster	<i>Ostrea chilensis</i>
Pacific oyster	<i>Crassostrea gigas</i>
Southern mud oyster or Australian flat oyster	<i>Ostrea angasi</i>

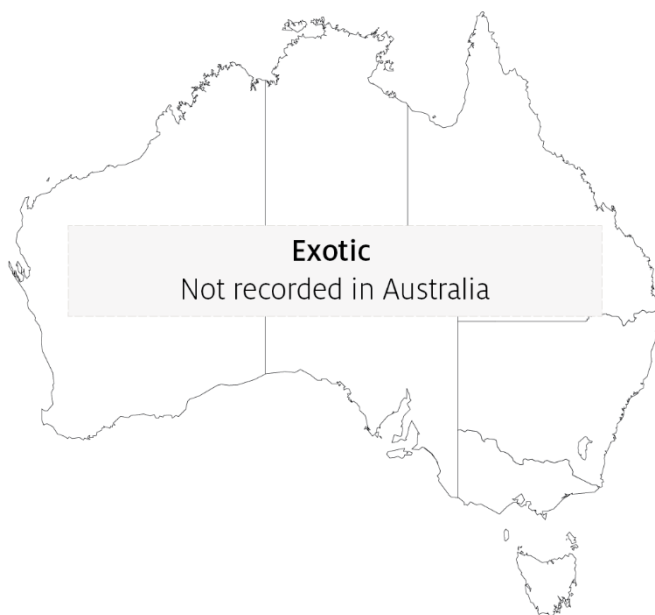Presence in Australia

Exotic disease—not recorded in Australia.

Bonamia exitiosa has been recorded from flat oysters in Victoria and New South Wales, and in a very low percentage of Sydney rock oysters in New South Wales. It is likely that *Bonamia* spp. previously recorded in flat oysters in Tasmania, South Australia and Western Australia are also *B. exitiosa*.

Bonamia ostreae and other *Bonamia* spp. are exotic to Australia, so any differential diagnosis of *Bonamia* spp. infection in Australian oysters requires specific confirmation using molecular diagnostic techniques to differentiate between the endemic *B. exitiosa* and exotic *B. ostreae* and *Bonamia* spp.

Map 31 Presence of *Bonamia* spp. (excluding *B. exitiosa*), by jurisdiction



Epidemiology

- Mortalities may occur all year, but usually happen in spring and summer.
- In most cases, oysters are lightly infected without mortalities. Factors that contribute to disease outbreaks are often unclear.
- *Bonamia* spp. are thought to be spread by human movements of subclinically infected oysters, and via infected hosts carried in biofouling on shipping.

Differential diagnosis

The list of [similar diseases](#) in the next section refers only to the diseases covered by this field guide. Gross pathological signs may also be representative of diseases not included in this guide. Do not rely on gross signs to provide a definitive diagnosis. Use them as a tool to help identify the listed diseases that most closely account for the observed signs.

Similar diseases

Infection with *Bonamia exitiosa*, infection with *Bonamia ostreae* and infection with *Mikrocytos mackini*.

There are few or no visual cues to the presence of this disease other than poor condition, shell gaping and increased mortality. Consequently, it is impossible to use gross signs alone to differentiate between infection by *Bonamia* species and *Mikrocytos* species. Concurrent infections with more than one species of *Bonamia* may also occur. Any presumptive diagnosis requires further laboratory examination.

Light microscopy can contribute diagnostic information (such as in the case of *B. perspora* infection when spores are present), but further laboratory examination and molecular diagnostic techniques are required for a definitive diagnosis.

Sample collection

Only trained personnel should collect samples. Using only gross pathological signs to differentiate between diseases is not reliable, and some aquatic animal disease agents pose a risk to humans. If you are not appropriately trained, phone your state or territory hotline number and report your observations. If you have to collect samples, the agency taking your call will advise you on the appropriate course of action. Local or district fisheries or veterinary authorities may also advise on sampling.

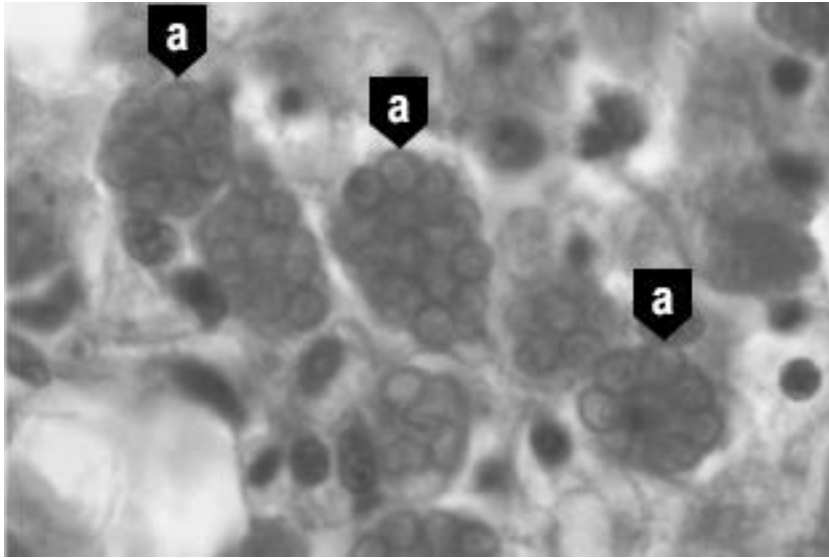
Emergency disease hotline

See something you think is this disease? Report it. Even if you're not sure.

Call the Emergency Animal Disease Watch Hotline on **1800 675 888**. They will refer you to the right state or territory agency.


Microscope images

Figure 117 Histological section of digestive gland of crested oyster (*Ostrea equestris*) with *Bonamia perspora* sporocysts



Note: Sporocysts of *B. perspora* (a).
Source: R Carnegie

Figure 118 Histological section of digestive gland of crested oyster (*Ostrea equestris*) with *Bonamia perspora* spores



Note: Individual spores of *B. perspora* (a) released into the lumen of the digestive gland tubule. Scale bar = 10µm.
Source: R Carnegie

Further reading

Australia and New Zealand standard diagnostic procedure [Bonamiosis in Australian 'Ostrea angasi'](#)

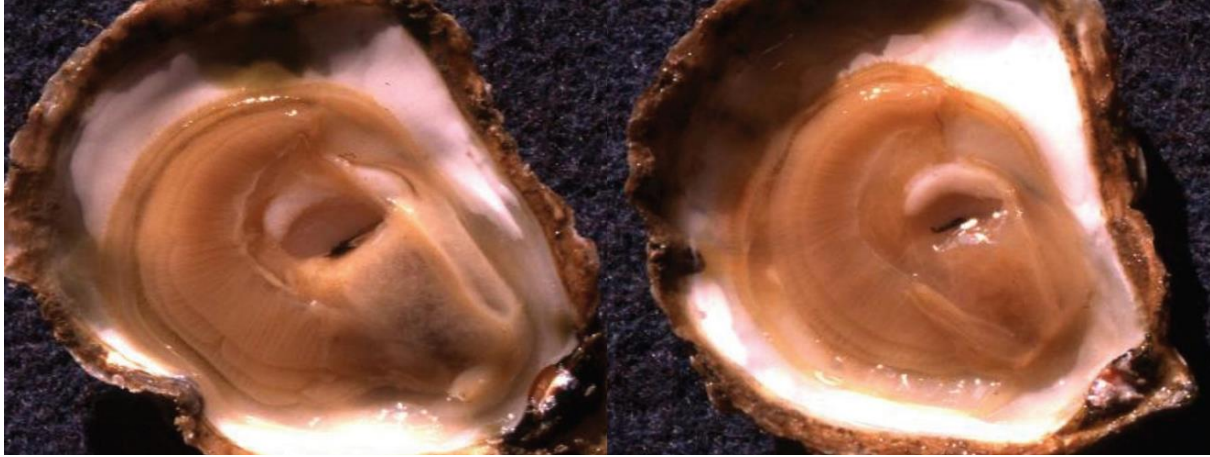CEFAS International Database on Aquatic Animal Diseases [Bonamiosis](#)

Infection with *Marteilia refringens*

Also known as marteiliosis and Aber disease

Exotic disease

Figure 119 European flat oyster (*Ostrea edulis*) infected with *Marteilia refringens*



Note: A healthy oyster (left) with full, creamy-coloured digestive gland. The infected oyster (right) has a translucent, watery, shrunken digestive gland.

Source: French Research Institute for Exploration of the Sea

Signs of disease

Important: Animals with this disease may show one or more of these signs, but the pathogen may still be present in the absence of any signs.

Disease signs at the farm, tank or pond level are:

- high mortality
- reduced growth rate
- gaping shells.

Gross pathological signs are:

- poor condition and emaciation
- pale, watery digestive gland
- inhibited gonad development.

Microscopic pathological signs are:

- tissue necrosis
- massive infection of the digestive gland tubule epithelium with sporogenic stages.

Disease agent

Marteiliosis (or Aber disease) is caused by infection with *Marteilia refringens*. This is a protozoan parasite (order Paramyxida, class Ascetosporea) that affects the digestive system of multiple bivalve species, including oysters, mussels, cockles and clams. Other closely related species of *Marteilia* may cause similar diseases, including *M. pararefringens* in oysters and mussels, *M. cochillia* in cockles, *M. octospora* in razor shells and *M. sydneyi* in Sydney rock oysters.

Host range

Table 48 Species known to be susceptible to infection with *Marteilia refringens*

Common name	Scientific name
American eastern oyster ^a	<i>Crassostrea virginica</i>
Argentinian flat oyster	<i>Ostrea puelchana</i>
Asiatic oyster ^a	<i>Ostrea denselammellosa</i>
Blue mussel ^a	<i>Mytilus edulis</i>
Calico scallop	<i>Argopecten gibbus</i>
Common cockle ^a	<i>Cerastoderma edule</i>
Dwarf oyster	<i>Ostrea stentina</i>
European flat oyster ^a	<i>Ostrea edulis</i>
European razor clam ^a	<i>Solen marginatus</i>
Mediterranean mussel ^a	<i>Mytilus galloprovincialis</i>
New Zealand dredge oyster ^a	<i>Ostrea chilensis</i>
Olympia oyster ^a	<i>Ostrea conchaphila</i>
Pacific oyster	<i>Crassostrea gigas</i>
Rock oyster ^a	<i>Saccostrea cucullata</i>
Small brown mussel	<i>Xenostrobus securis</i>
Southern mud oyster or Australian flat oyster	<i>Ostrea angasi</i>
Striped venus clam ^a	<i>Chamelea gallina</i>
Planktonic copepods ^a	<i>Paracartia grani</i>

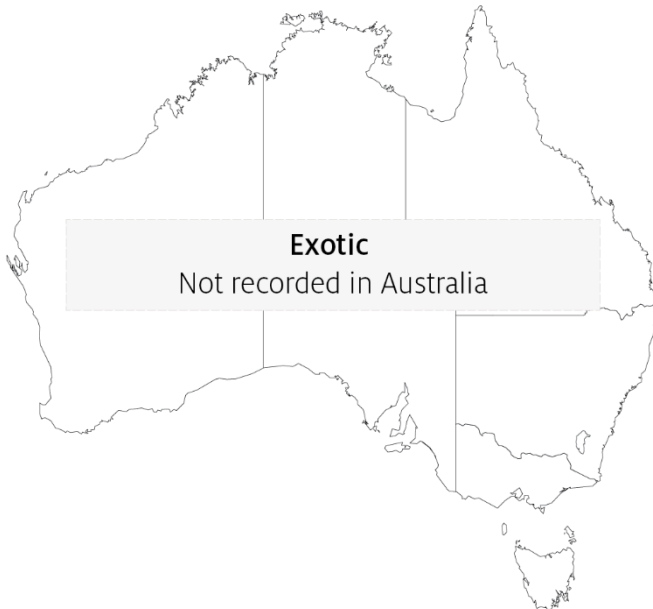^a Naturally susceptible. Note: Other species have been shown to be experimentally susceptible.

Presence in Australia

Exotic disease—not recorded in Australia.

Marteilia refringens has never been recorded in Australia and is considered exotic. However, related species of *Marteilia* have been detected in various oyster species in Queensland, New South Wales and Western Australia.

Map 32 Presence of *Marteilia refringens*, by jurisdiction



Epidemiology

- *Marteilia refringens* infections result in high cumulative mortality (50 to 90%) and is associated with sporulation of the parasite in the epithelial cells of the digestive tubules.
- Highest cumulative mortalities usually occur during summer and autumn.
- Earlier stages of sporulation occur in epithelia of the digestive ducts and possibly the gills.
- Several intermediate hosts or a free-living stage are thought to be required during the life cycle of *M. refringens*. The planktonic copepod *Paracartia grani* is one intermediate host and may be involved in transmission of *M. refringens* between bivalves.
- *Marteilia refringens* can exist in a carrier state in apparently healthy oysters, which can be potential reservoirs of infection.
- Factors triggering a pathogenic host response are not clearly established. Factors may include environmental stresses and differences in susceptibility to disease between different host populations.
- The temperature threshold for parasite sporulation and transmission is 17°C. However, this is thought to vary with other environmental factors.

Differential diagnosis

The list of [similar diseases](#) in the next section refers only to the diseases covered by this field guide. Gross pathological signs may also be representative of diseases not included in this guide. Do not rely on gross signs to provide a definitive diagnosis. Use them as a tool to help identify the listed diseases that most closely account for the observed signs.

Similar diseases

Infection with *Marteilia sydneyi*.

The clinical signs of infection with *M. refringens* are almost identical to those of infection with other *Ascetosporea*. These include high mortalities associated with colourless and translucent tissue, poor condition, pale digestive gland and a shrunken body. Any presumptive diagnosis requires further laboratory examination. Light microscopy can contribute diagnostic information, but further laboratory examination and molecular diagnostic techniques are required for a definitive diagnosis.

Sample collection

Only trained personnel should collect samples. Using only gross pathological signs to differentiate between diseases is not reliable, and some aquatic animal disease agents pose a risk to humans. If you are not appropriately trained, phone your state or territory hotline number and report your observations. If you have to collect samples, the agency taking your call will advise you on the appropriate course of action. Local or district fisheries or veterinary authorities may also advise on sampling.

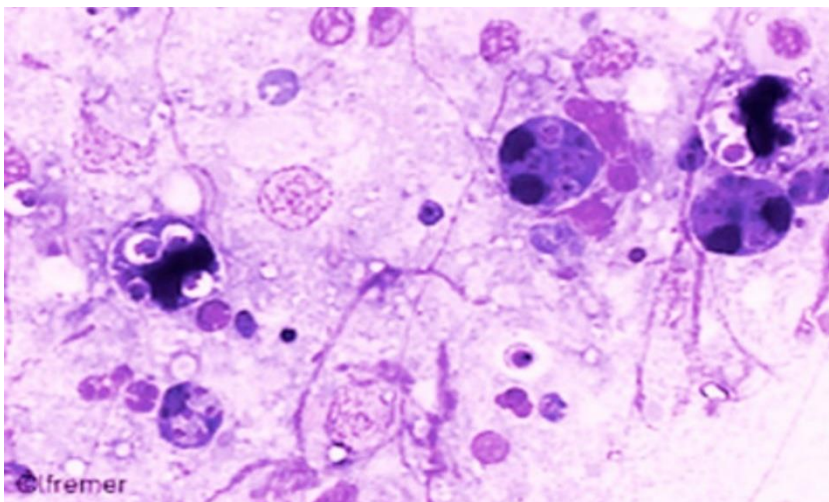
Emergency disease hotline

See something you think is this disease? Report it. Even if you're not sure.

Call the Emergency Animal Disease Watch Hotline on **1800 675 888**. They will refer you to the right state or territory agency.

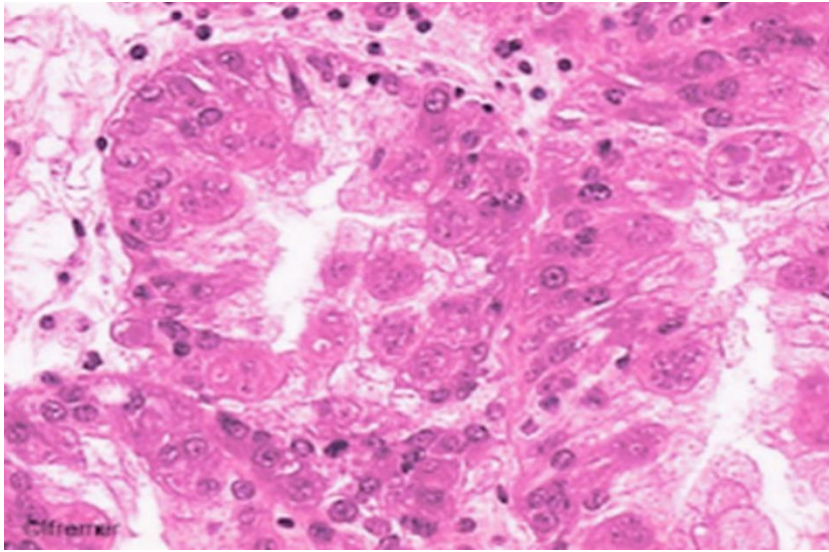
Microscope images

Figure 120 Stained digestive gland imprint from European flat oyster (*Ostrea edulis*) infected with *Marteilia refringens*



Note: Several dark-staining *M. refringens* sporonts containing pairs of spores. 120x magnification.
Source: French Research Institute for Exploration of the Sea

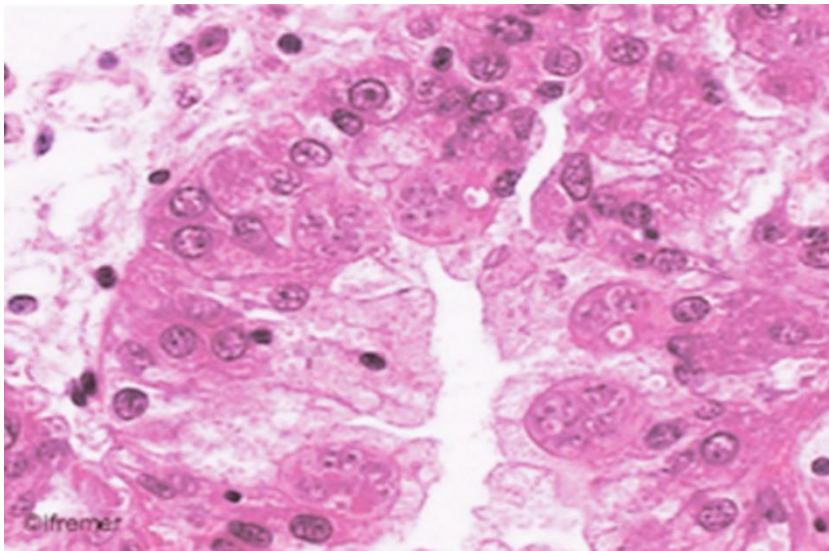
Figure 121 Histological section through digestive gland of European flat oyster (*Ostrea edulis*)



Note: Large numbers of sporogenic stages of *M. refringens* in the tubule epithelium. 80x magnification.

Source: French Research Institute for Exploration of the Sea

Figure 122 Histological section through digestive gland of European flat oyster (*Ostrea edulis*)



Note: Sporogenic stages of *M. refringens* in the tubule epithelium. 120x magnification.

Source: French Research Institute for Exploration of the Sea

Further reading

CABI Invasive Species Compendium [Infection with 'Marteilia refringens'](#)

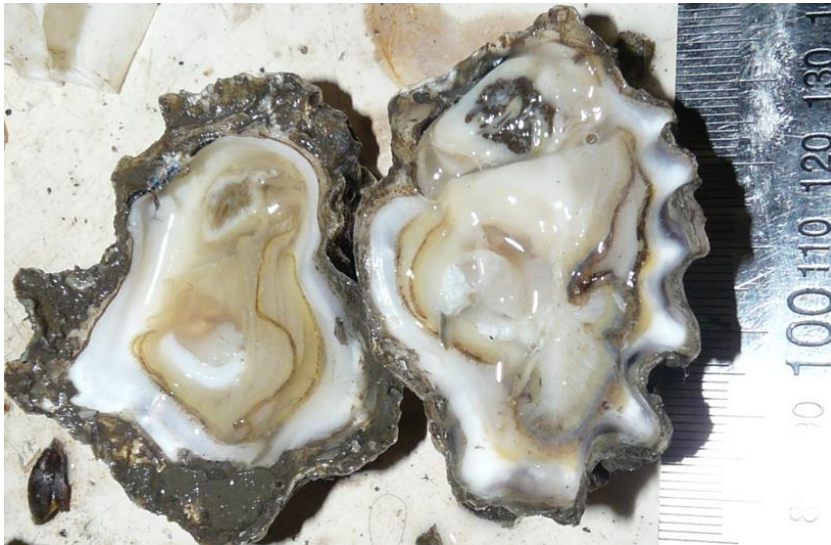CEFAS International Database on Aquatic Animal Diseases [Infection with 'Marteilia refringens'](#)

World Organisation for Animal Health [Manual of diagnostic tests for aquatic animals](#)

Infection with *Marteilia sydneyi*

Also known as Marteiliosis and QX disease

Figure 123 Sydney rock oysters (*Saccostrea glomerata*) infected with *Marteilia sydneyi*



Note: Shrunken, pale yellowish, watery digestive gland typical of oyster infected with QX disease (left). Normal digestive gland of oyster is darker (right).

Source: B Diggles

Signs of disease

Important: Animals with this disease may show one or more of these signs, but the pathogen may still be present in the absence of any signs.

Disease signs at the farm, tank or pond level are:

- reduced growth rate
- gaping shells
- high cumulative mortalities of up to 100%.

Gross pathological signs are:

- shrunken, watery body
- generally poor condition
- death often within 60 days of infection
- colourless and translucent tissue because the gonad is completely resorbed
- digestive gland (usually a deep green or brown colour) becomes pale yellow or brown.

Microscopic pathological signs are:

- focal haemocytic inflammation of the gills
- hyperplasia of the connective tissue and gill epithelium, with fusion of gill filaments
- massive infection of the digestive gland tubule epithelium with sporogenic stages.

Disease agent

Marteiliosis (also known as QX disease) is caused by infection with *Marteilia sydneyi*. This protozoan parasite (order Paramyxida, class Ascetosporea) infects the digestive system of Sydney rock oysters and mud dwelling polychaete worms. Other closely related species of *Marteilia* may cause similar diseases, including *M. pararefringens* in oysters and mussels, *M. cochillia* in cockles, *M. octospora* in razor shells, and *M. refringens* in oysters, mussels, cockles and clams.

Host range

Marteilia sydneyi has an indirect life cycle. Mud-dwelling polychaetes are one known intermediate host, but there may be others.

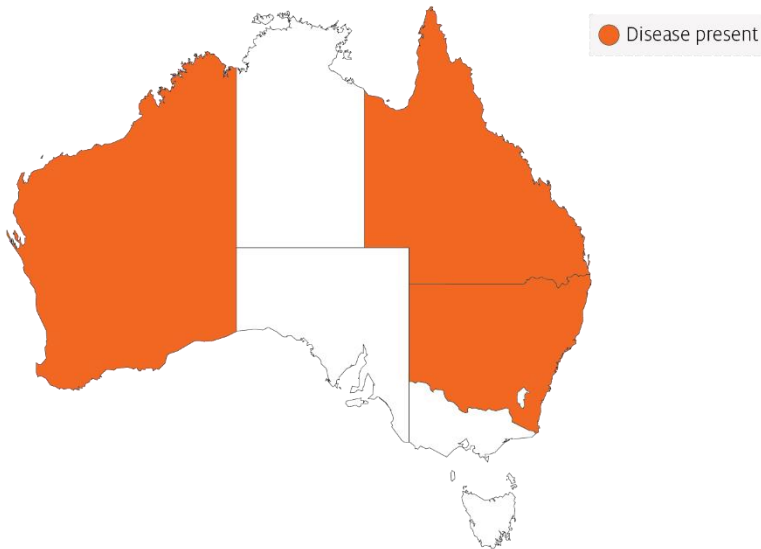
Table 49 Species known to be naturally susceptible to infection with *Marteilia sydneyi*

Common name	Scientific name
Rock oyster	<i>Saccostrea cucullata</i>
Sydney rock oyster	<i>Saccostrea glomerata</i>
Polychaete	<i>Nephtys australiensis</i>

Presence in Australia

Infection with *M. sydneyi* is responsible for losses in the Sydney rock oyster industry on the east coast of Australia. The parasite and disease are present in Queensland and New South Wales. A related species of *Marteilia* has been detected in apparently healthy Australian flat oysters (*Ostrea angasi*) in New South Wales. A *Marteilia* sp. (probably *M. sydneyi*) was officially reported in 1994, associated with disease in the coral rock oyster (*Saccostrea cucullata*) in Western Australia.

Map 33 Presence of *Marteilia sydneyi*, by jurisdiction



Epidemiology

- The presence of the *Marteilia sydneyi* in eastern Australian estuaries is not always accompanied by QX disease. Most of the estuaries that are free of QX disease have less anthropogenic disturbance in the catchment.
- Oysters may be subjected to infection for a period of as little as 2 weeks per year.
- Outbreaks of disease occur in summer and autumn. Warm temperatures favour parasite development, leading to greatest mortality at the end of summer.
- Onset of the disease is often associated with immunosuppression of oysters due to stressors such as flooding or low salinity, high water temperature and excessive sedimentation.
- Transmission is horizontal. The pathogen passes from the environment into the epithelium of the palps and gills, where it proliferates without forming spores. In advanced infections, spores are formed in the digestive gland epithelium.
- Oysters that carry low levels of *M. sydneyi* infections can shed the parasite and make a full recovery.
- The life cycle of *M. sydneyi* is indirect but not fully understood. Intermediate hosts are required to complete the life cycle. Benthic mud-dwelling polychaetes such as *Nephtys australiensis* are one of possibly several intermediate hosts.
- Increased virulence of *M. sydneyi* in degraded estuaries compared to historical times may be due to a combination of several factors. These include increased immunosuppression of the host due to declining water quality together with increased abundance of polychaete intermediate hosts that are favoured by sedimentation, eutrophication and other anthropogenic changes derived from catchment development.

Differential diagnosis

The list of [similar diseases](#) in the next section refers only to the diseases covered by this field guide. Gross pathological signs may also be representative of diseases not included in this guide. Do not rely on gross signs to provide a definitive diagnosis. Use them as a tool to help identify the listed diseases that most closely account for the observed signs.

Similar diseases

Infection with *Marteilia refringens*.

The clinical signs of infection with *M. sydneyi* are almost identical to those of infection with other *Ascetosporea*. These include high mortalities associated with colourless and translucent tissue, poor condition, pale digestive gland and a shrunken body. Any presumptive diagnosis requires further laboratory examination. Light microscopy can contribute diagnostic information, but further laboratory examination and molecular diagnostic techniques are required for a definitive diagnosis.

Sample collection

Only trained personnel should collect samples. Using only gross pathological signs to differentiate between diseases is not reliable, and some aquatic animal disease agents pose a risk to humans. If you are not appropriately trained, phone your state or territory hotline number and report your observations. If you have to collect samples, the agency taking your call will advise you on the appropriate course of action. Local or district fisheries or veterinary authorities may also advise on sampling.

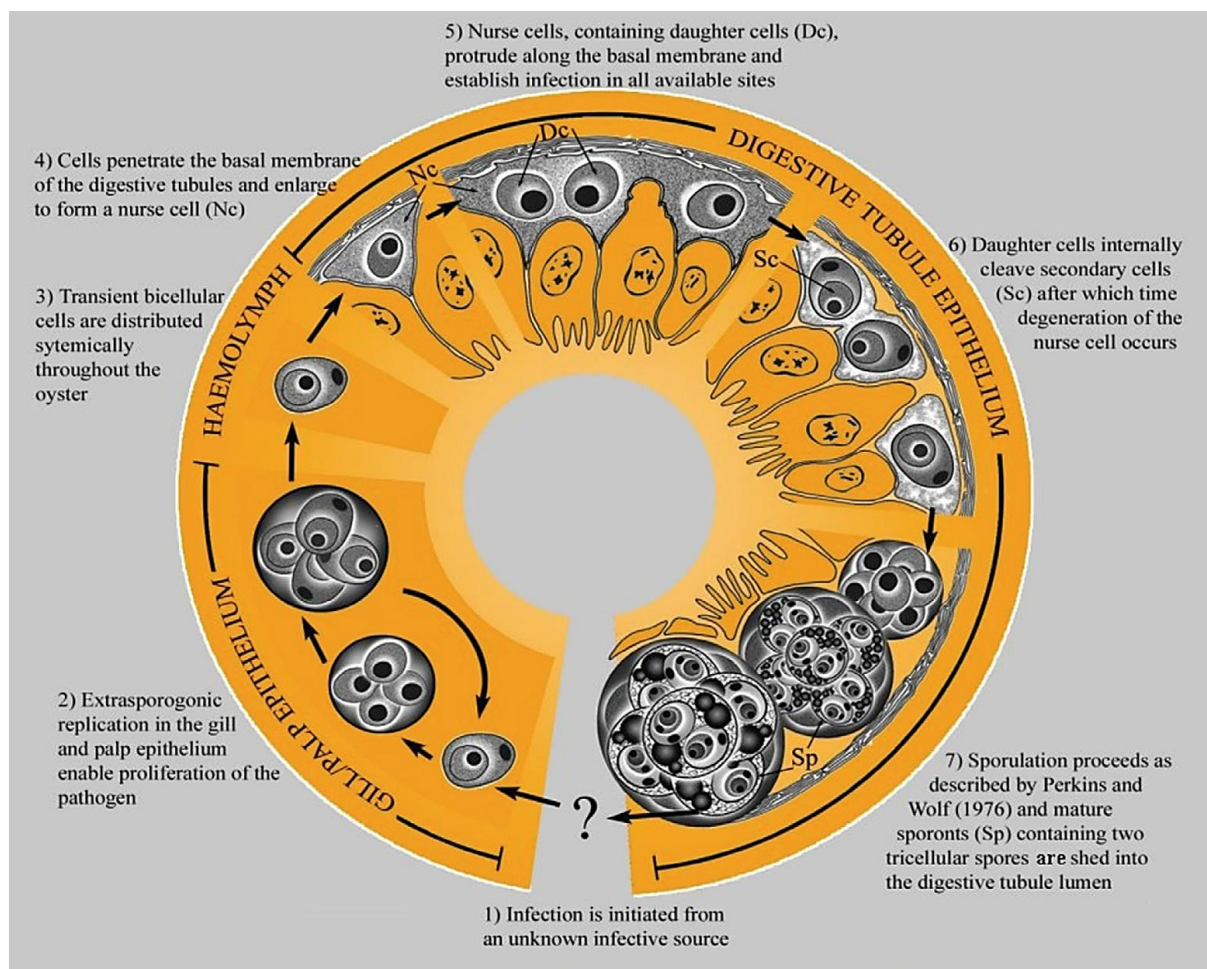
Emergency disease hotline

See something you think is this disease? Report it. Even if you're not sure.

Call the Emergency Animal Disease Watch Hotline on **1800 675 888**. They will refer you to the right state or territory agency.

Microscope images

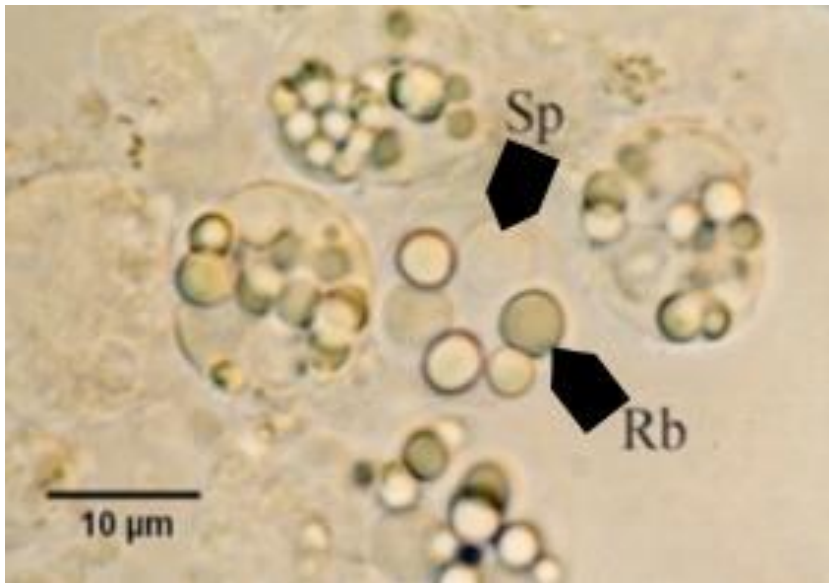
Figure 124 Hypothetical development of *Marteilia sydneyi* in Sydney rock oyster (*Saccostrea glomerata*)



Note: Migration of *M. sydneyi* infective stages, from gills and palps to digestive gland tubule epithelium where sporulation occurs.

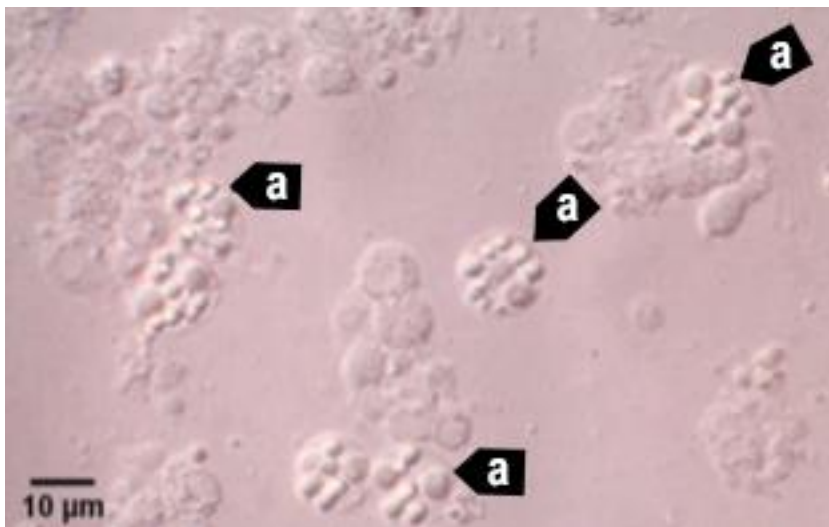
Source: S Ridgeway

Figure 125 Unstained wet smear of digestive gland of Sydney rock oyster (*Saccostrea glomerata*) with QX disease



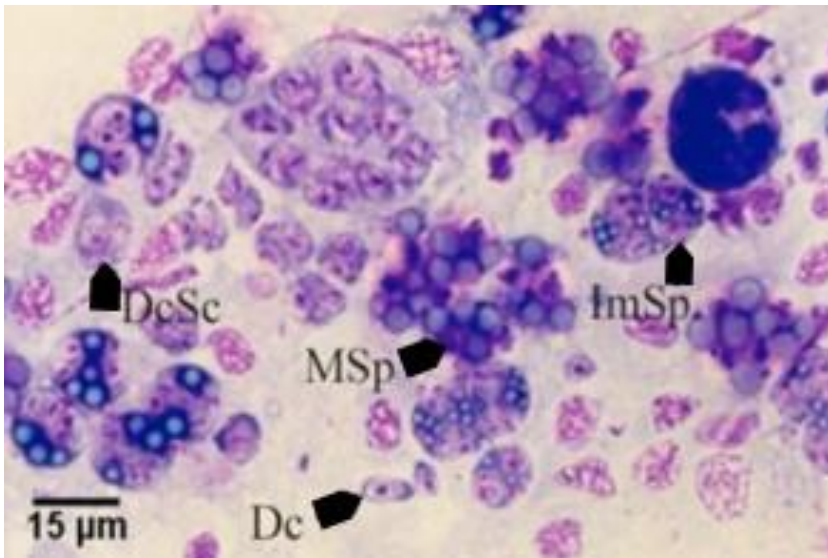
Note: *M. sydneyi* sporonts with refractile bodies (Rb) and spores (Sp). Scale bar = 10μm.
Source: S Ridgeway

Figure 126 Unstained wet smear of digestive gland of Sydney rock oyster (*Saccostrea glomerata*) showing *Marteilia sydneyi* sporonts viewed under interference contrast optics



Note: Many *M. sydneyi* sporonts (a) visible. Scale bar = 10μm.
Source: S Ridgeway

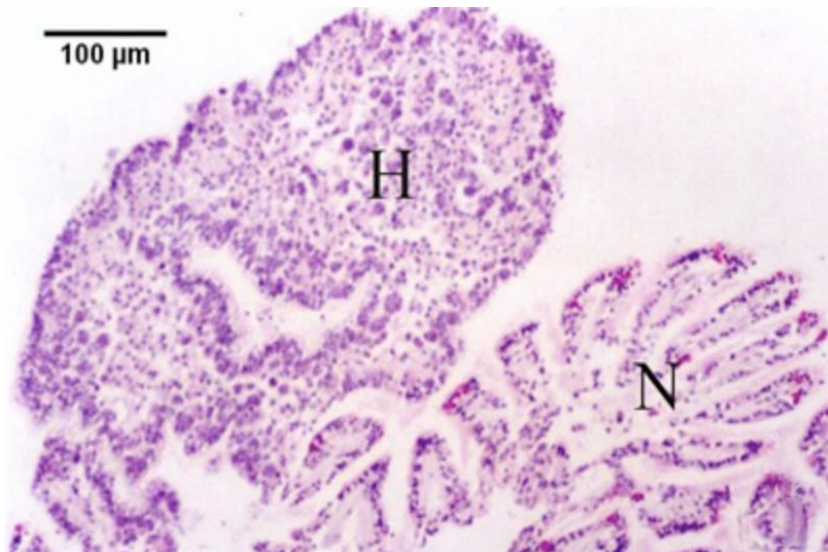
Figure 127 Hemacolor (Merck)-stained tissue imprint of digestive gland of Sydney rock oyster (*Saccostrea glomerata*) infected with *Marteilia sydneyi* in multiple life stages



Note: Various life cycle stages, including daughter cells (Dc), daughter cells containing secondary cells (DcSc), immature sporonts (ImSp) and mature sporonts (MSp). The various stages observed are often ruptured from their enclosing cells (the nurse cells or sporangiosori). Scale bar = 15µm.

Source: S Ridgeway

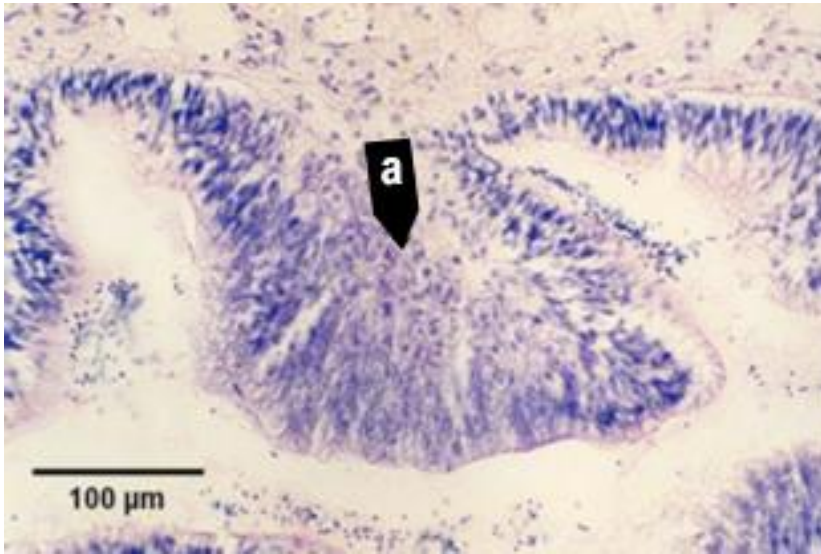
Figure 128 Histopathology of gills of Sydney rock oyster (*Saccostrea glomerata*) infected with *Marteilia sydneyi*



Note: Reaction of *S. glomerata* to the presence of numerous *M. sydneyi* extrasporogonic stages in the epithelium of the gills. Consisting of epithelial and connective tissue haemocytosis (H) and fusion of filaments. Contrasted with relatively normal-looking gill tissue (N). Scale bar = 100µm.

Source: S Ridgeway

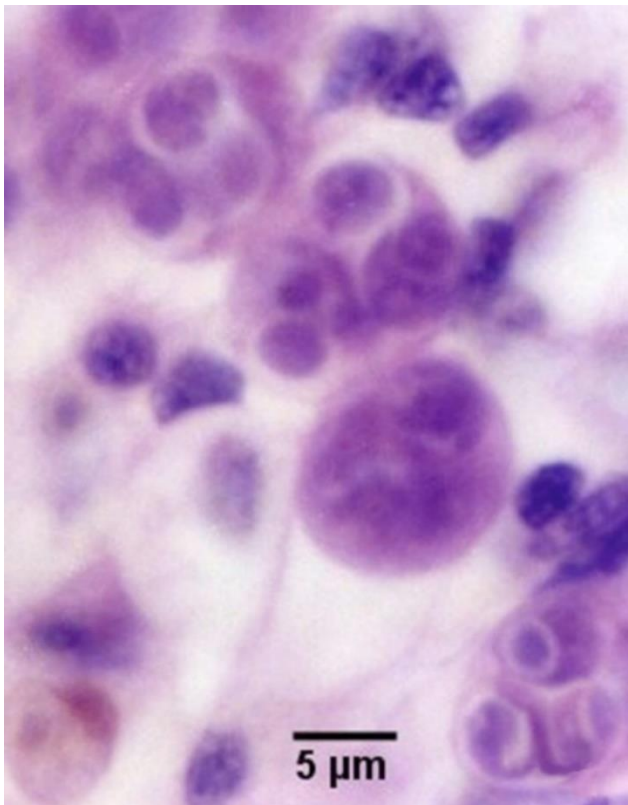
Figure 129 Histopathology of palp epithelium of Sydney rock oyster (*Saccostrea glomerata*) infected with *Marteilia sydneyi*



Note: Replicating stages of *M. sydneyi* in the palp epithelium causing hypertrophy of epithelial cells in the presence of proliferating parasites (a). Scale bar = 100μm.

Source: S Ridgeway

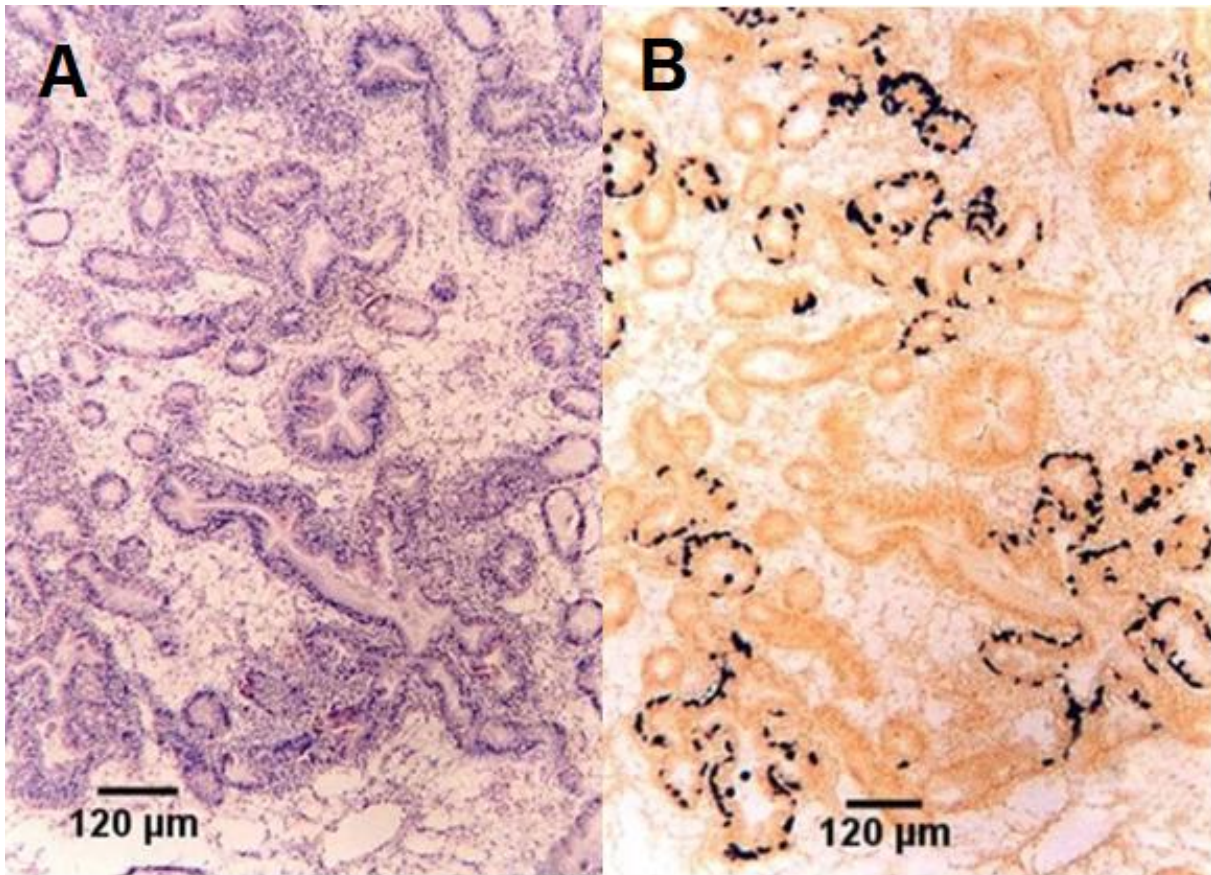
Figure 130 High power magnification of the epithelium of gills of Sydney rock oyster (*Saccostrea glomerata*)



Note: Extrasporogonic stages (see phase 2 in Figure 124). Scale bar = 5μm

Source: S Ridgeway

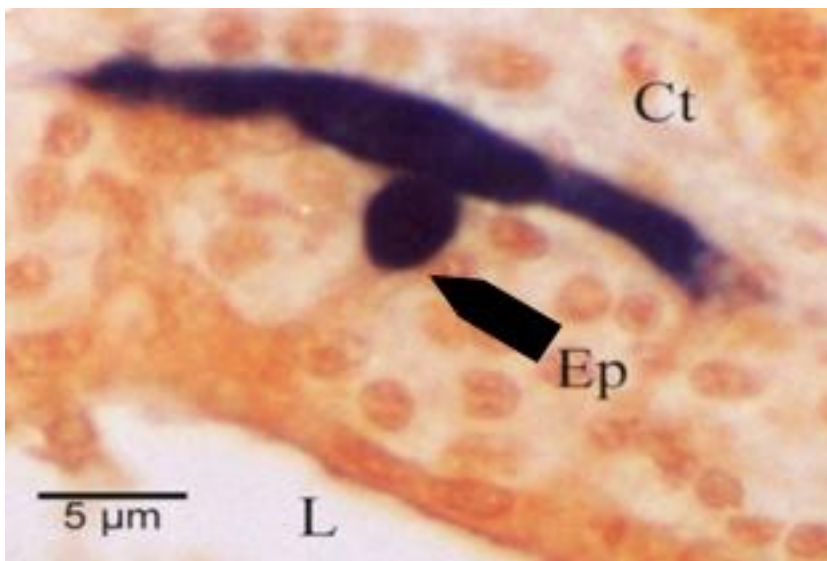
Figure 131 Serial sections of haemocytic infiltration of connective tissue surrounding infected digestive gland tubules



Note: Comparison of histopathological section (A) and in situ hybridisation section (B). Location of presporulating nurse cell stages in digestive gland tubule epithelia show stained black in B. Scale bar = 120µm

Source: S Ridgeway

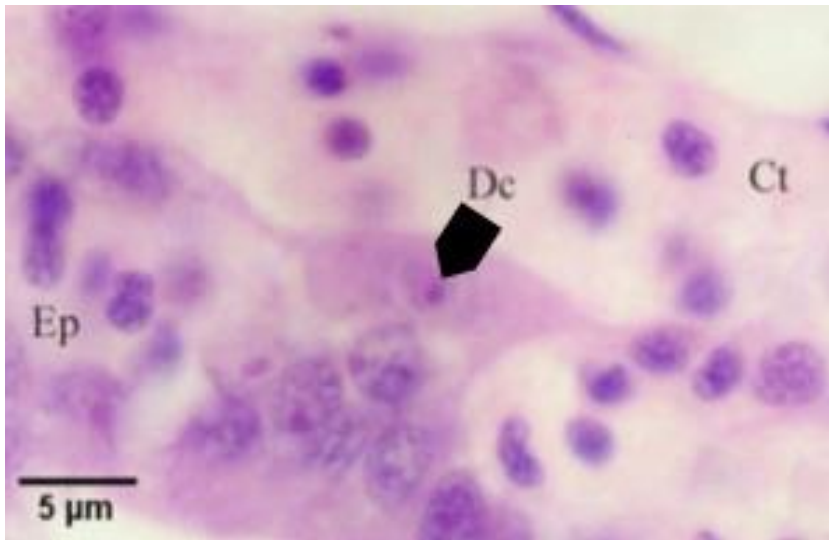
Figure 132 Nurse cell stained black by in situ hybridisation



Note: Stain shows extent of the pseudopodial extensions along basal membrane of digestive tubule epithelium (Ep). This feature is not evident with haematoxylin and eosin staining. Other labelled features are connective tissue (Ct) surrounding the tubule and lumen (L) of the tubule. Scale bar = 5µm.

Source: S Ridgeway

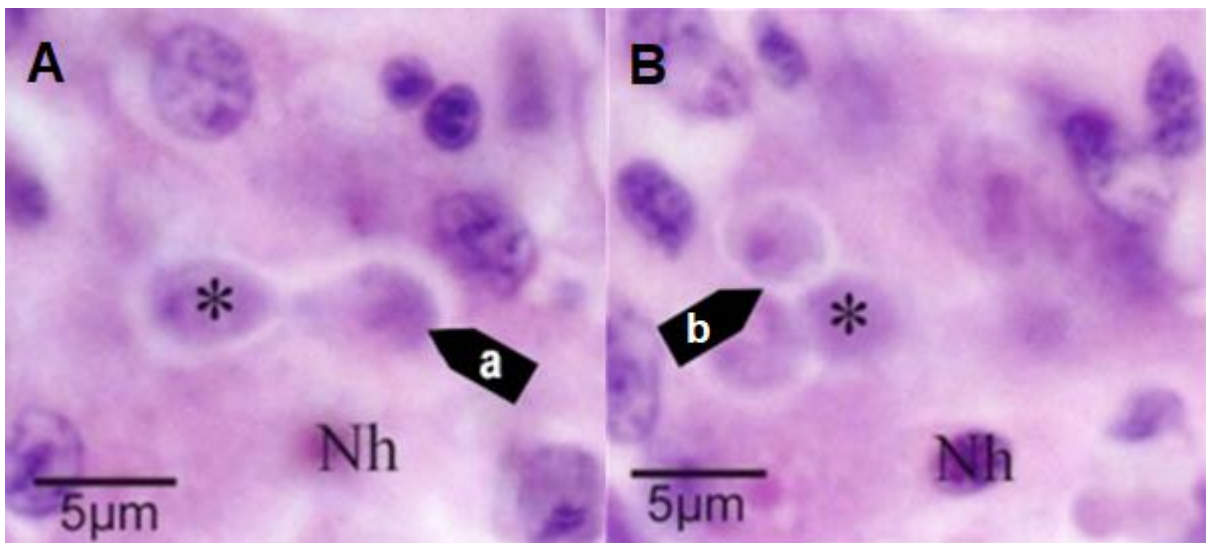
Figure 133 Histological section of digestive gland of Sydney rock oyster (*Saccostrea glomerata*) with *Marteilia sydneyi* nurse cell



Note: Nurse cell containing one daughter cell (Dc) along basal membrane of tubule between connective tissue (Ct) surrounding the tubules and tubule epithelium (Ep). Scale bar = 5μm.

Source: S Ridgeway

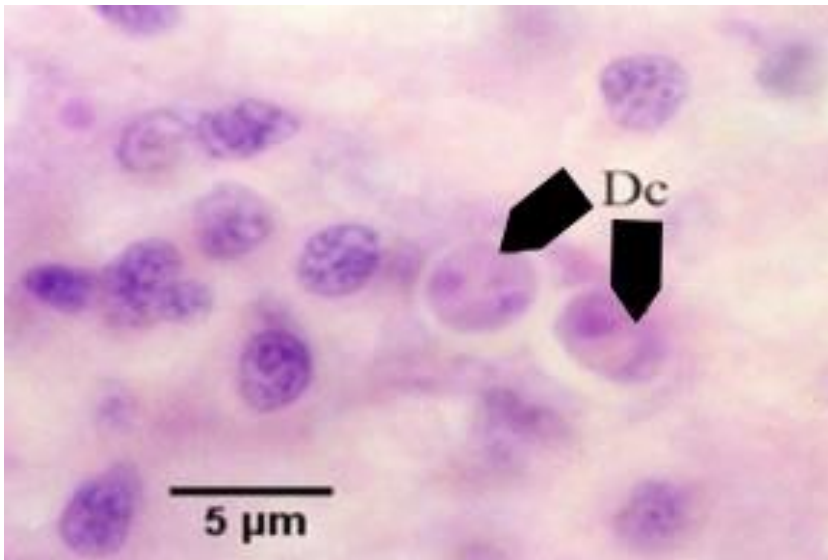
Figure 134 Two photos of same tissue section at different focal planes, demonstrating budding of daughter cell



Note: The new daughter cell (a) budding within the nurse cell is visible only in one focal plane (A). Another daughter cell (asterisk), and the host cell nucleus (Nh) are visible in each figure. Two additional daughter cells (b) within the nurse cell visible only in the second focal plane (B). Scale bar = 5μm.

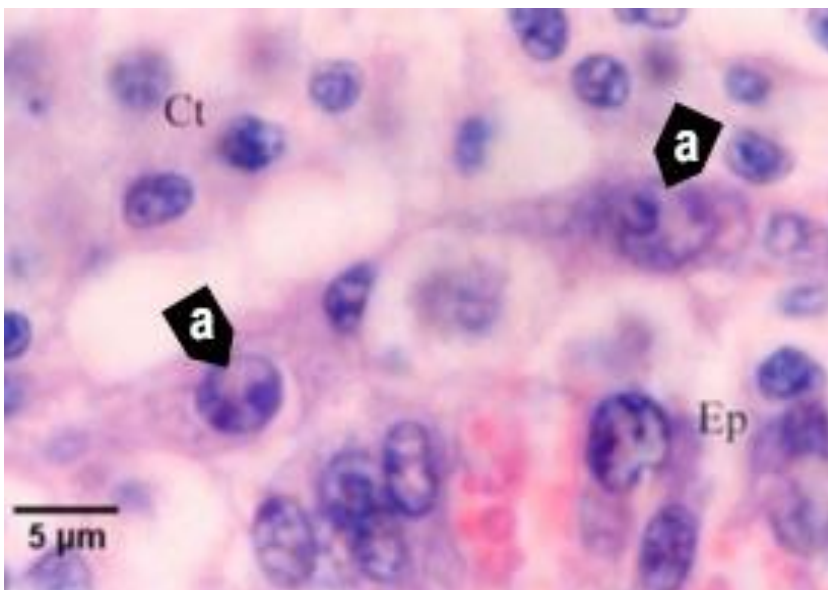
Source: S Ridgeway

Figure 135 Histological section of digestive gland of Sydney rock oyster (*Saccostrea glomerata*) with daughter cells of *Marteilia sydneyi*



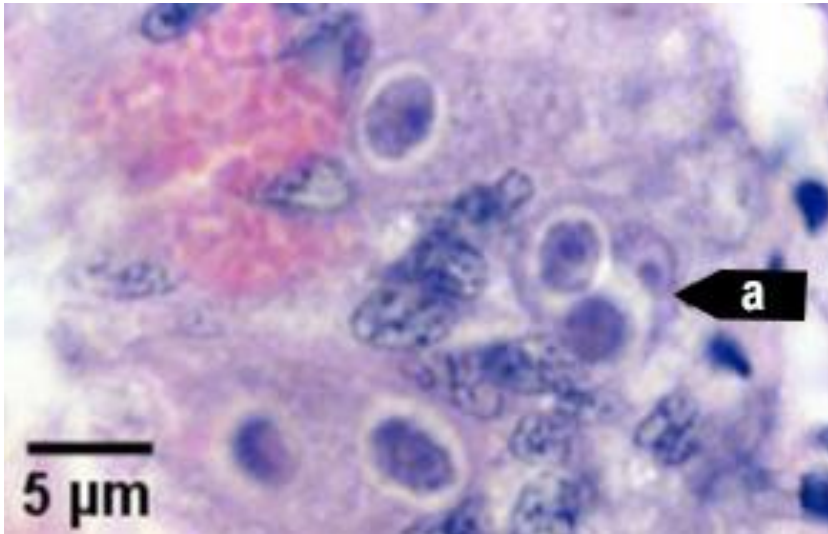
Note: Nurse cell of *M. sydneyi* containing 2 daughter cells (Dc) (see phase 5 in Figure 124). Scale bar = 5μm.
Source: S Ridgeway

Figure 136 Histological section of digestive gland of Sydney rock oyster (*Saccostrea glomerata*) with bicellular daughter cells of *Marteilia sydneyi*



Note: Nurse cells of *M. sydneyi* containing bicellular daughter cells (a) along the basal membrane between tubule epithelium (Ep) and connective tissue (Ct) that contains numerous infiltrating haemocytes (see phase 6 in Figure 124). Scale bar = 5μm
Source: S Ridgeway

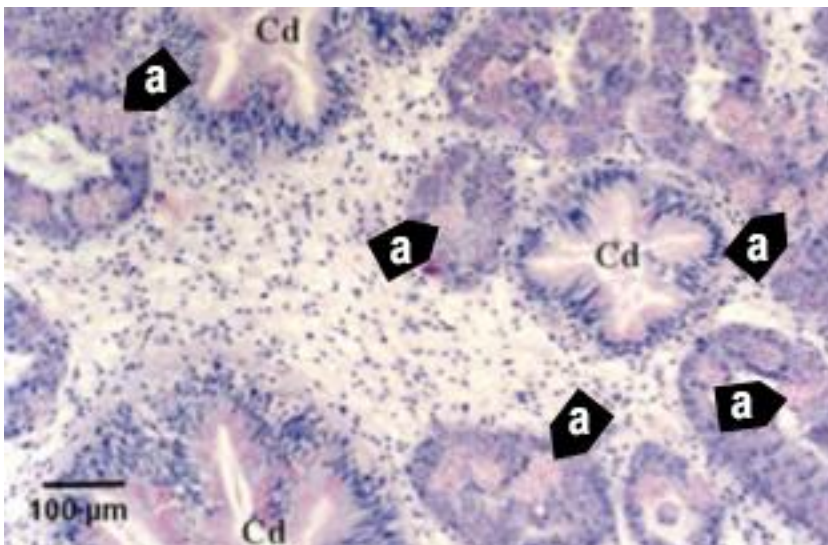
Figure 137 Histological section of digestive gland of Sydney rock oyster (*Saccostrea glomerata*) with primary and secondary cells of *Marteilia sydneyi*



Note: Primary cell (a) containing 2 secondary cells (sporont primordia) just before sporulation (see initiation of phase 7 in Figure 124). Scale bar = 5μm.

Source: S Ridgeway

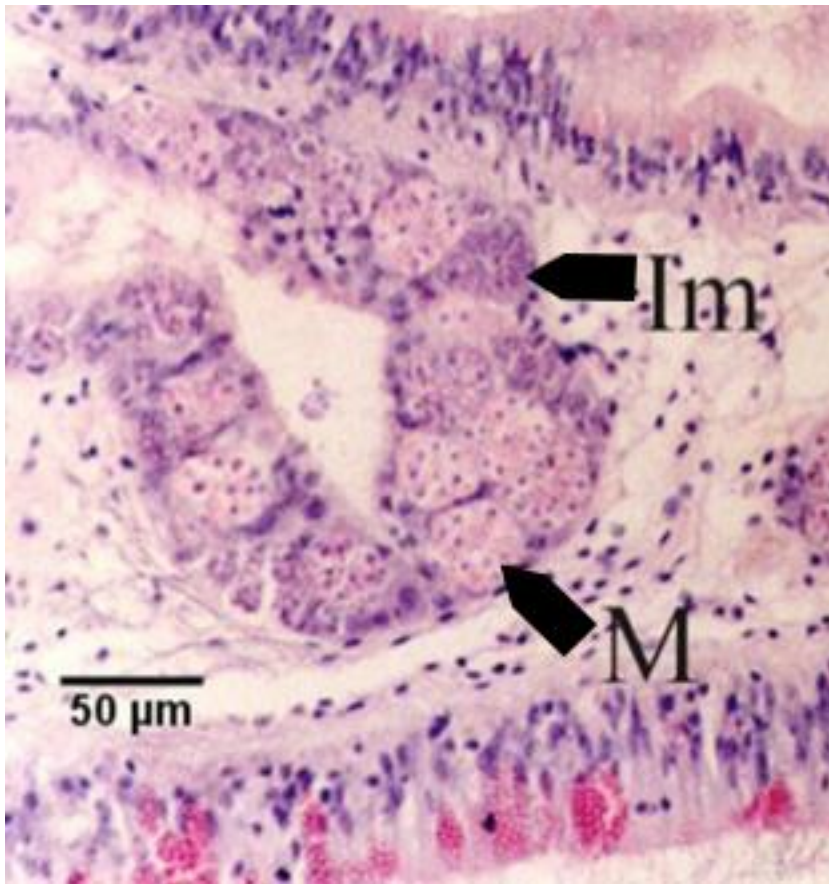
Figure 138 Histological section of digestive gland of Sydney rock oyster (*Saccostrea glomerata*) with *Marteilia sydneyi* sporulating stages



Note: Numerous sporulating stages (a) in the digestive gland tubules. Sporulation does not occur in the ciliated ducts (Cd) of the digestive gland. Scale bar = 100μm

Source: S Ridgeway

Figure 139 Histological section of digestive gland of Sydney rock oyster (*Saccostrea glomerata*) with *Marteilia sydneyi* sporonts



Note: Immature sporonts (Im) and mature sporonts (M) within sporangiosori in a digestive gland tubule. The epithelium of the tubule is almost completely replaced by *M. sydneyi*. Scale bar = 50µm.

Source: S Ridgeway

Further reading

CABI Invasive Species Compendium [Infection with 'Marteilia sydneyi'](#)

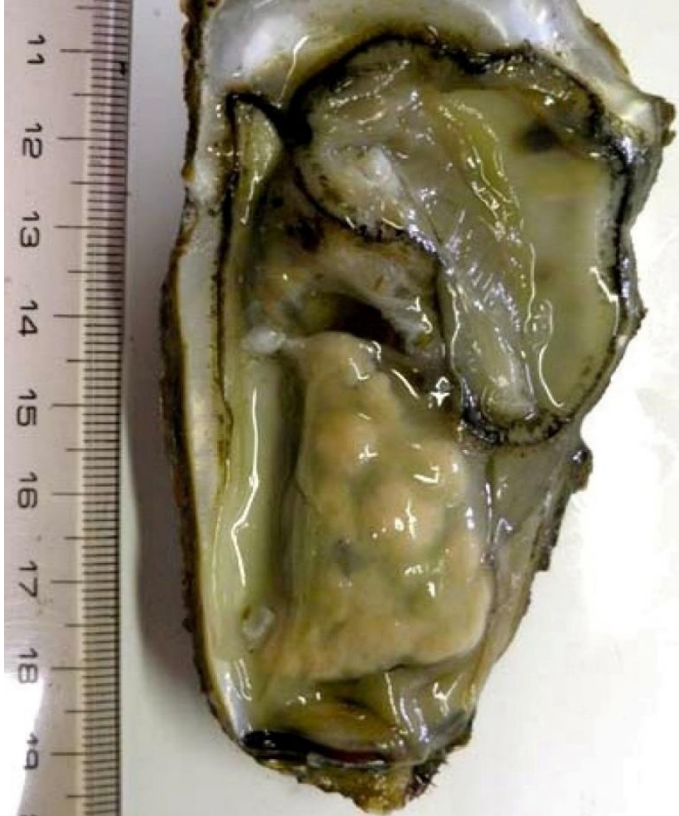CEFAS International Database on Aquatic Animal Diseases [Marteiliosis](#)

Infection with *Marteilioides chungmuensis*

Also known as marteilioidosis

Exotic disease

Figure 140 Pacific oyster (*Crassostrea gigas*) infected with *Marteilioides chungmuensis*



Note: Nodular yellowish lesions visible in the gonad.

Source: N Itoh

Signs of disease

Important: Animals with this disease may show one or more of these signs, but the pathogen may still be present in the absence of any signs.

Disease signs at the farm, tank or pond level are:

- spawning failure
- high mortalities.

Gross pathological signs are:

- visible distension of the mantle surface due to infected eggs retained within the follicle
- nodule-like structures on the gonad surface.

Microscopic pathological signs are:

- paramyxean parasites within oocytes.

Disease agent

Marteiloidosis is caused by infection with *Marteilioides chungmuensis*, a protozoan parasite (order i, class Ascetosporea) that infects the oocytes of oysters.

Host range

Table 50 Species known to be susceptible to infection with *Marteilioides chungmuensis*

Common name	Scientific name
Iwagaki oyster	<i>Crassostrea nippona</i>
Pacific oyster ^a	<i>Crassostrea gigas</i>

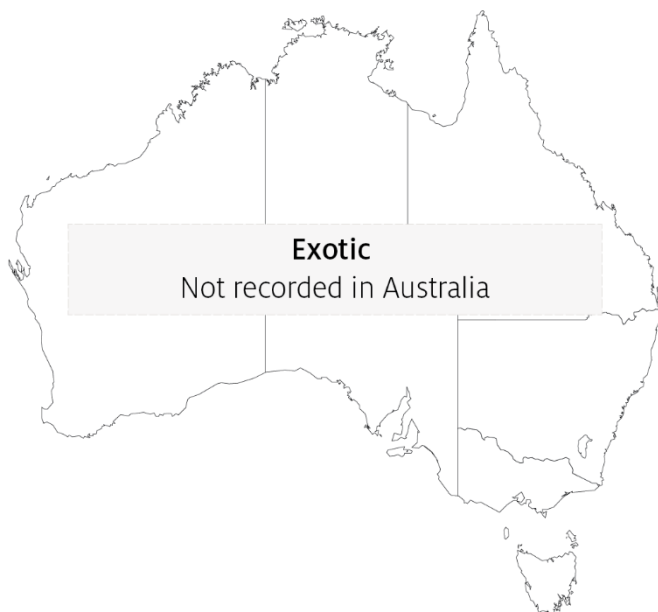^a Naturally susceptible. Note: Other species have been shown to be experimentally susceptible.

Presence in Australia

Exotic disease—not recorded in Australia.

Marteilioides chungmuensis has not been recorded in Australia and is considered exotic. Other species of *Marteilioides* have been reported in the ovary of *Saccostrea echinata* from the Northern Territory and Western Australia. The related *M. branchialis* causes focal lesions in the gill lamellae of Sydney rock oysters in northern New South Wales.

Map 34 Presence of *Marteilioides chungmuensis*, by jurisdiction



Epidemiology

- *Marteilioides chungmuensis* infects the cytoplasm of mature oocytes and can affect a substantial proportion of eggs.
- Prolonged spawning activity of infected oysters has been observed, resulting in nutritional wasting and mortality.
- Prevalence of infection increases during spawning in summer and decreases after spawning in winter.
- Infected oysters lose their marketability, due to their abnormal appearance.

- Mode of transmission is unknown. However, as for other paramyxeans, intermediate hosts may be involved in the life cycle of the parasite.

Differential diagnosis

The list of [similar diseases](#) in the next section refers only to the diseases covered by this field guide. Gross pathological signs may also be representative of diseases not included in this guide. Do not rely on gross signs to provide a definitive diagnosis. Use them as a tool to help identify the listed diseases that most closely account for the observed signs.

Similar diseases

No diseases listed in this field guide are similar to infection with *Marteilioides chungmuensis*.

Sample collection

Only trained personnel should collect samples. Using only gross pathological signs to differentiate between diseases is not reliable, and some aquatic animal disease agents pose a risk to humans. If you are not appropriately trained, phone your state or territory hotline number and report your observations. If you have to collect samples, the agency taking your call will advise you on the appropriate course of action. Local or district fisheries or veterinary authorities may also advise on sampling.

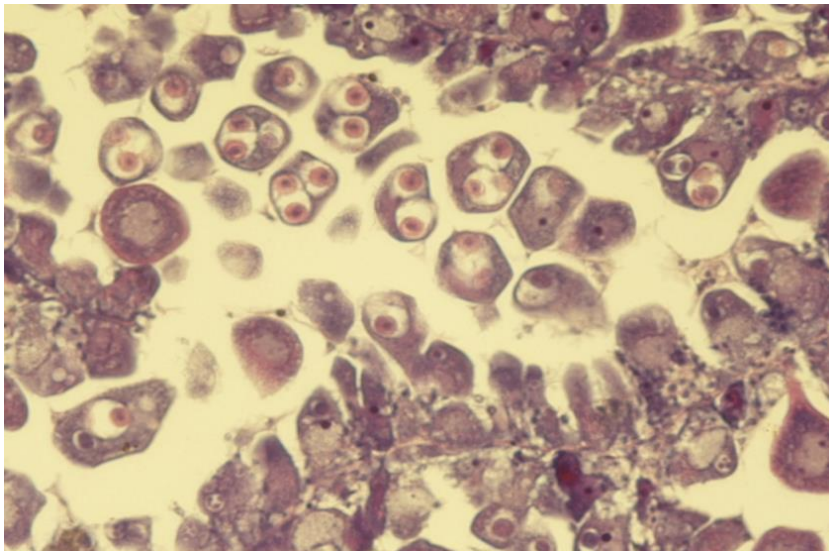
Emergency disease hotline

See something you think is this disease? Report it. Even if you're not sure.

Call the Emergency Animal Disease Watch Hotline on **1800 675 888**. They will refer you to the right state or territory agency.

Microscope images

Figure 141 Histological section of ovary of Pacific oyster (*Crassostrea gigas*)



Note: Intracellular (within oocytes) *Marteilioides chungmuensis* parasites.

Source: N Itoh

Further reading

European Union Reference Laboratory for Molluscs Diseases [‘Marteilioides chungmuensis’](#)

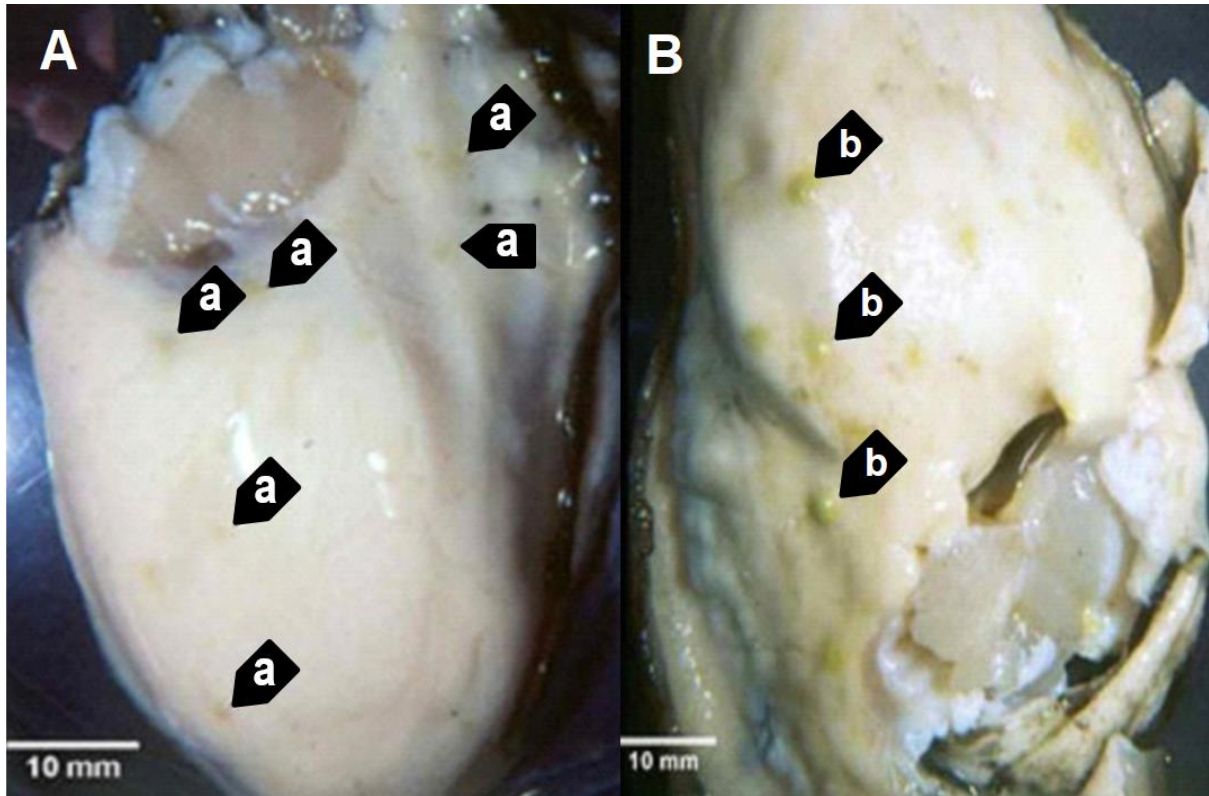
Fisheries and Oceans Canada [‘Marteilioides chungmuensis’ of oysters](#)

Infection with *Mikrocytos mackini*

Also known as Denman Island disease

Exotic disease

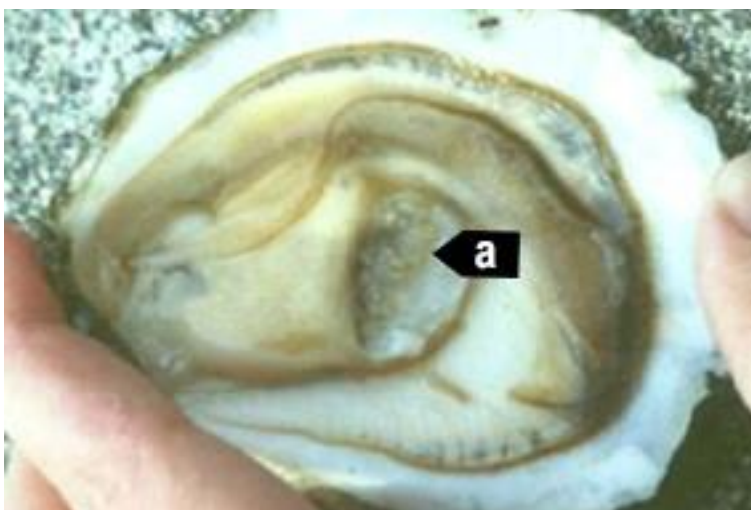Figure 142 Pacific oysters (*Crassostrea gigas*) removed from shell showing focal lesions characteristic of infection with *Mikrocytos mackini*



Note: Oyster (left) shows lesions (a) typical of early infections. Oyster (right) shows lesions (b) typical of advanced stages of the disease, when *M. mackini* typically can no longer be found in the lesions.

Source: S Bower

Figure 143 European flat oyster (*Ostrea edulis*) with lesions caused by infection with *Mikrocytos mackini*



Note: Numerous lesions in the adductor muscle (a) caused by *M. mackini* (experimental infection).

Source: S Bower

Signs of disease

Important: Animals with this disease may show one or more of these signs, but the pathogen may still be present in the absence of any signs.

Diseases caused by any of the microcell species are similar. In cases of light infection, few or no clinical or gross signs are present. Concurrent infections with more than one species of *Bonamia* may also occur. Definitive identification of *Bonamia* or *Mikrocytos* species requires histological laboratory examination and molecular diagnostic techniques.

Disease signs at the farm, tank or pond level are:

- dead or gaping oysters
- increased mortality.

Gross pathological signs are:

- focal yellow or green lesions up to 5mm in diameter within the body wall or on surfaces of the gonad, labial palps, gills or mantle
- brown scars on the shell adjacent to lesions on the mantle surface
- gaping oysters due to impaired adductor muscle contraction.

Microscopic pathological signs are:

- focal intracellular infection, mainly of vesicular connective tissue (leydig) cells, resulting in haemocyte infiltration and tissue necrosis
- intracellular and extracellular microcell protozoa, 2 to 3µm in diameter, in vesicular connective tissue cells immediately adjacent to lesions.

Disease agent

Denman Island disease is caused by infection with *Mikrocytos mackini*, an intracellular protozoan parasite that causes lethal infection of certain species of oysters. *M. mackini* is classified in the order Mikrocytida within the class Ascetosporea, and is not closely related to *Bonamia* spp.

Mikrocytids are a highly divergent group of protists that infect a range of aquatic invertebrates including bivalve molluscs, decapod crustaceans and annelids.

Host range

Table 51 Species known to be susceptible to infection with *Mikrocytos mackini*

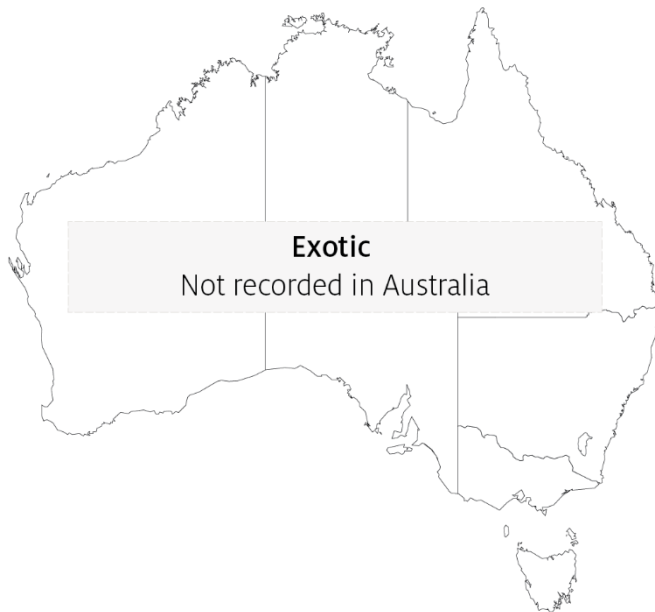Common name	Scientific name
American eastern oyster ^a	<i>Crassostrea virginica</i>
European flat oyster	<i>Ostrea edulis</i>
Olympia oyster ^a	<i>Ostrea lurida</i>
Pacific oyster ^a	<i>Crassostrea gigas</i>

^a Naturally susceptible. Note: Other species have been shown to be experimentally susceptible.

Presence in Australia

Exotic disease—not recorded in Australia.

Map 35 Presence of *Mikrocytos mackini*, by jurisdiction



Epidemiology

- Severe infections appear to be restricted to oysters over 2 years old.
- The disease is associated with low temperature and high salinity. Most mortalities occur during April to May (spring in the northern hemisphere). There is a 3 to 4 month pre-patent period when temperatures are less than 10°C.
- The Pacific oyster appears to be more resistant to the disease than other species challenged experimentally under laboratory and field conditions.

Differential diagnosis

The list of [similar diseases](#) in the next section refers only to the diseases covered by this field guide. Gross pathological signs may also be representative of diseases not included in this guide. Do not rely on gross signs to provide a definitive diagnosis. Use them as a tool to help identify the listed diseases that most closely account for the observed signs.

Similar diseases

Infection with *Bonamia ostreae*, infection with *Bonamia exitiosa* and infection with *Bonamia* spp.

There are few or no visual cues to the presence of this disease other than poor condition, shell gaping and increased mortality. Consequently, it is impossible to use gross signs alone to differentiate between infection by *M. mackini* and *Bonamia* species. Any presumptive diagnosis requires further laboratory examination.

Light microscopy can contribute diagnostic information, but further laboratory examination and molecular diagnostic techniques are required for a definitive diagnosis.

Sample collection

Only trained personnel should collect samples. Using only gross pathological signs to differentiate between diseases is not reliable, and some aquatic animal disease agents pose a risk to humans. If you are not appropriately trained, phone your state or territory hotline number and report your observations. If you have to collect samples, the agency taking your call will advise you on the appropriate course of action. Local or district fisheries or veterinary authorities may also advise on sampling.

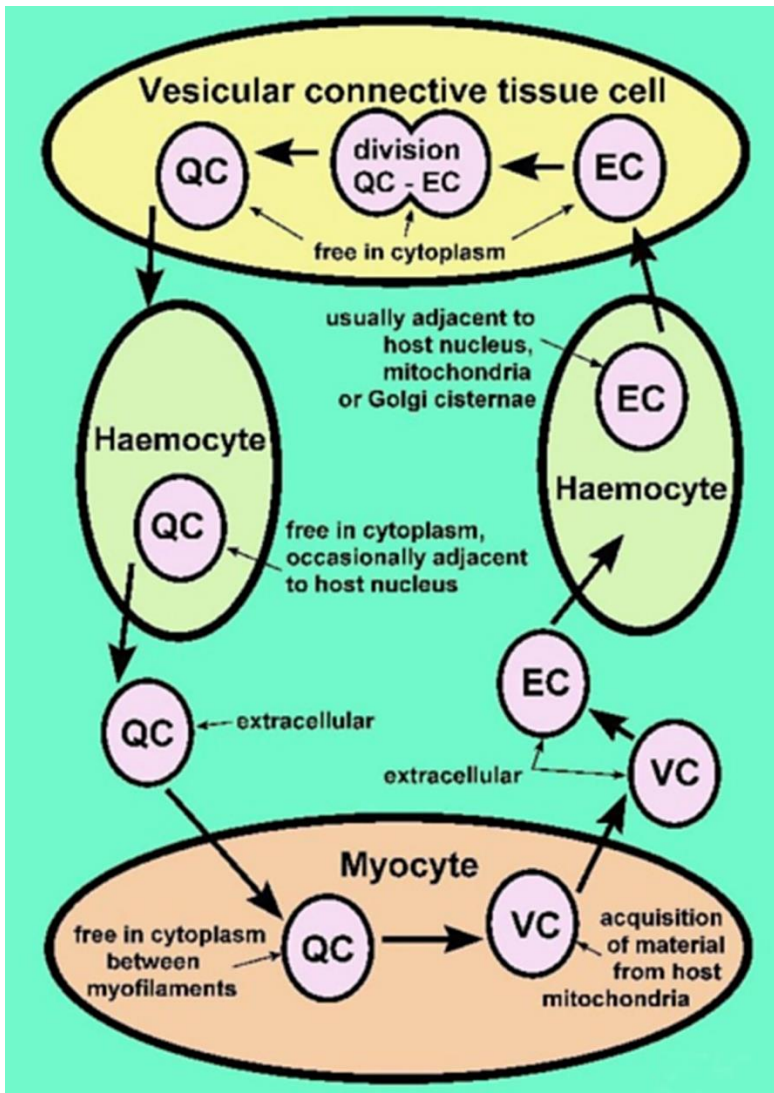
Emergency disease hotline

See something you think is this disease? Report it. Even if you're not sure.

Call the Emergency Animal Disease Watch Hotline on **1800 675 888**. They will refer you to the right state or territory agency.

Microscope images

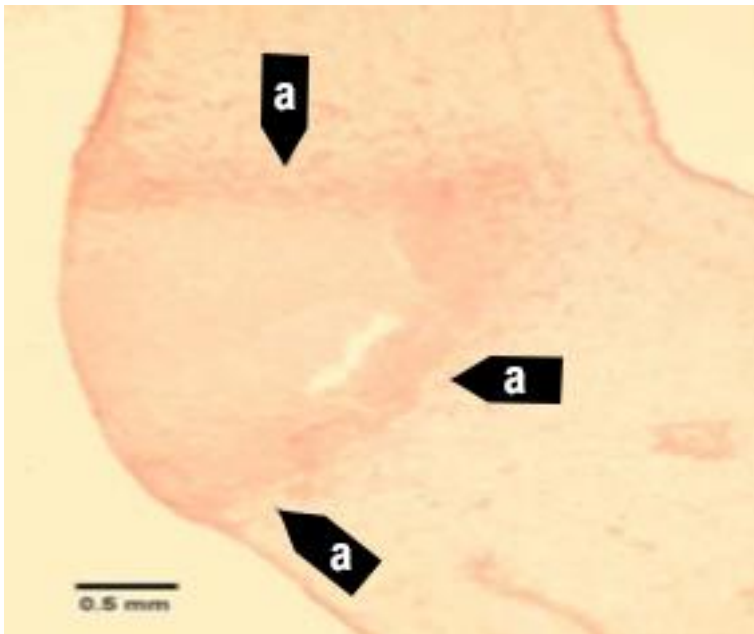
Figure 144 Proposed developmental cycle of *Mikrocytos mackini*



Note: Host cell type and host organelle affiliation for the three recognised morphological forms: quiescent cell (QC), vesicular cell (VC) and endosomal cell (EC).

Source: S Bower

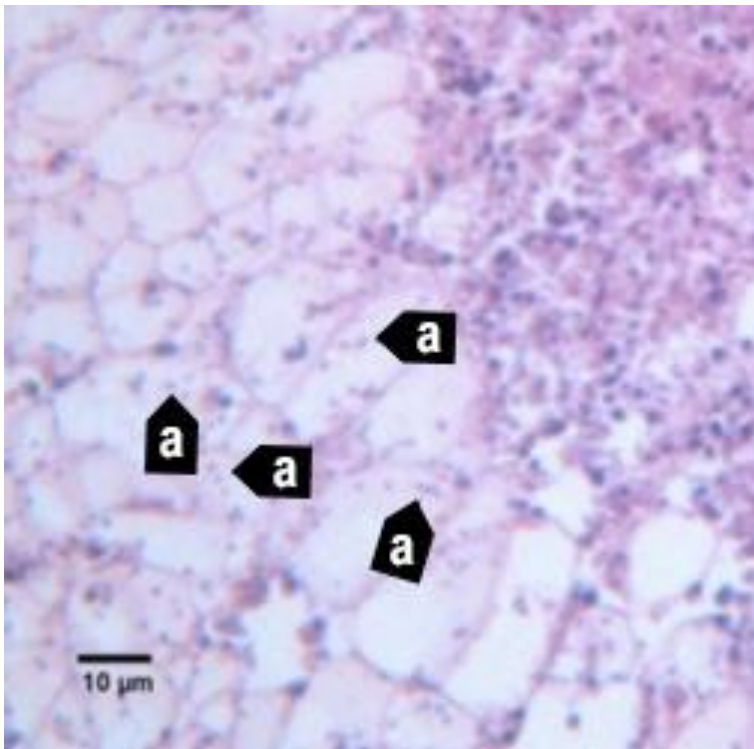
Figure 145 Section through lesion caused by *Mikrocytos mackini* in the mantle of Pacific oyster (*Crassostrea gigas*)



Note: The intracellular protozoan (not visible at this magnification) usually occurs in the intact vesicular connective tissue cells immediately surrounding the periphery of the lesion (a). Haematoxylin and eosin stain. Scale bar = 500µm.

Source: S Bower

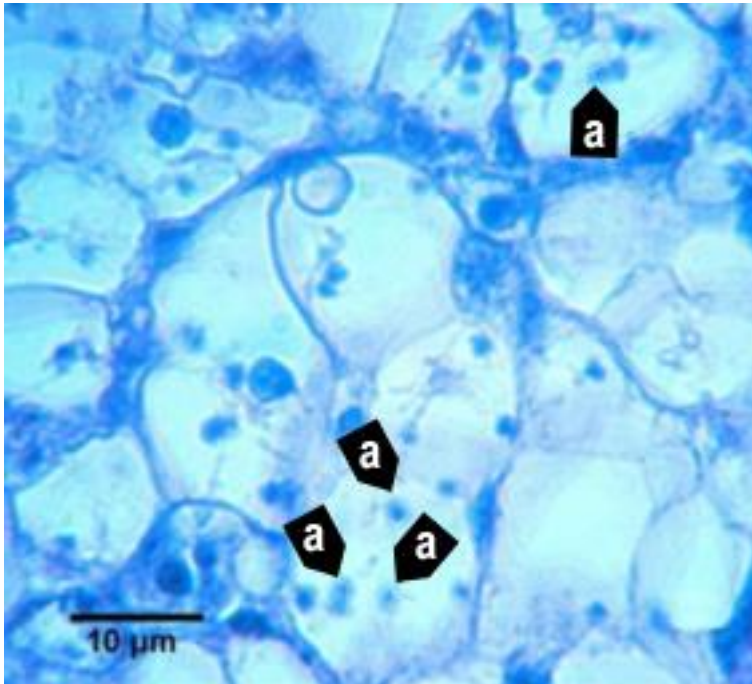
Figure 146 Section through lesion in the vesicular connective tissue of Pacific oyster (*Crassostrea gigas*)



Note: Many *Mikrocytos mackini* (a) within vesicular connective tissue (Leydig) cells next to a lesion characterised by an accumulation of haemocytes and necrotic cells. Haematoxylin and eosin stain. Scale bar = 10µm.

Source: S Bower

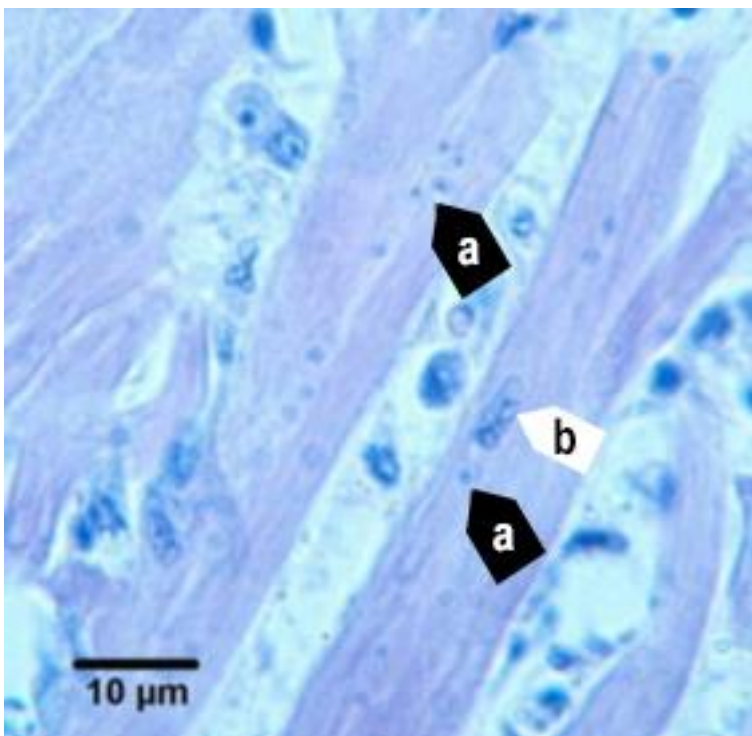
Figure 147 Oil immersion magnification of *Mikrocytos mackini* within the cytoplasm of vesicular connective tissue cells of Pacific oyster (*Crassostrea gigas*)



Note: Because of the small size of this parasite, it is very difficult to visualise and photograph in histological preparations. Haematoxylin and eosin stain. Scale bar = 10µm.

Source: S Bower

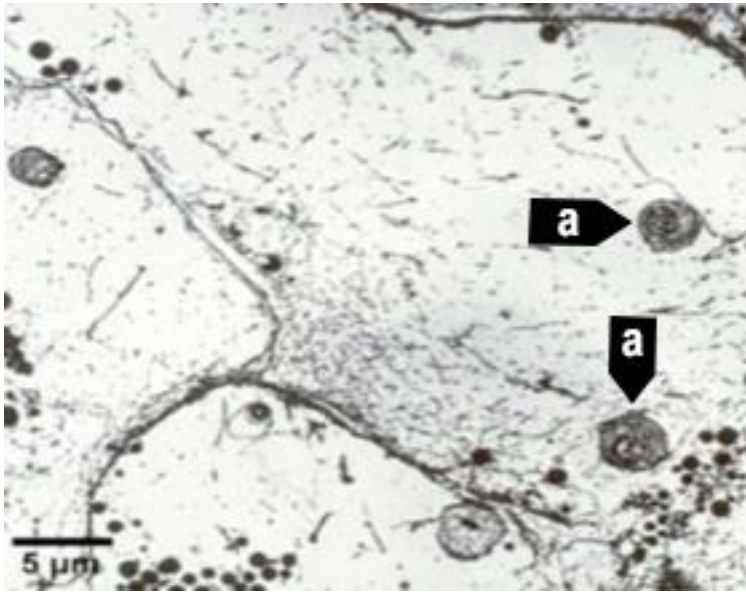
Figure 148 *Mikrocytos mackini* within fibres of adductor muscle of Pacific oyster (*Crassostrea gigas*)



Note: Several *M. mackini* microcells (a) are located close to the nucleus (b) of a muscle cell. Haematoxylin and eosin stain. Scale bar = 10µm.

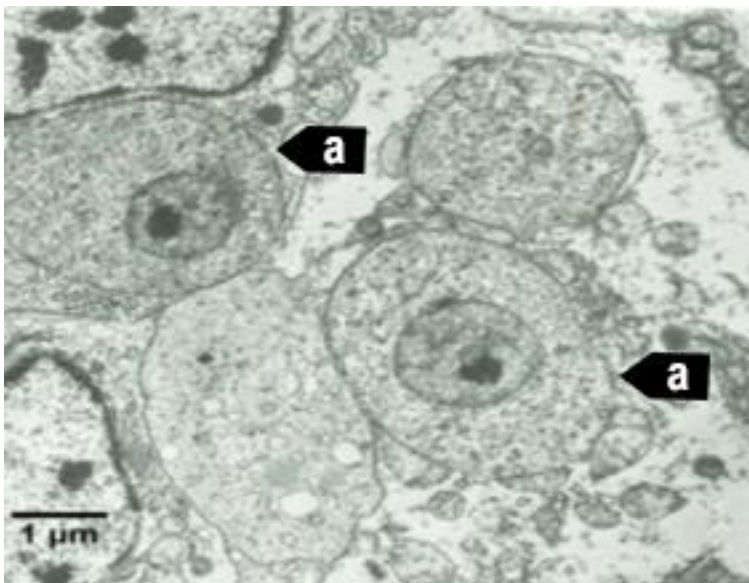
Source: S Bower

Figure 149 Electron micrograph of vesicular connective tissue cell from Pacific oyster (*Crassostrea gigas*)



Note: Two *M. mackini* (a) in the cytoplasm of the cell. Uranyl acetate and lead citrate stain. Scale bar = 5μm.
Source: S Bower

Figure 150 Electron micrograph of two *Mikrocystos mackini* microcells



Note: Two *M. mackini* microcells (a) each containing a nucleus with a pronounced nucleolus and lacking mitochondria. Uranyl acetate and lead citrate stain. Scale bar = 1μm.
Source: S Bower

Further reading

CABI Invasive Species Compendium [‘Mikrocystos mackini’](#)

CEFAS International Database on Aquatic Animal Diseases [Infection with ‘Mikrocystos mackini’](#)

European Union Reference Laboratory for Molluscs Diseases [‘Mikrocystos mackini’](#)

World Organisation for Animal Health [Manual of diagnostic tests for aquatic animals](#)

Infection with *Perkinsus marinus*

Also known as perkinsosis and dermo disease

Exotic disease

Figure 151 American oyster (*Crassostrea virginica*) showing gross signs of infection with *Perkinsus marinus*



Note: A healthy oyster (left). The infected oyster (right) is thin and watery, typical gross signs of infection with *P. marinus*.
Source: E Burreson

Signs of disease

Important: Animals with this disease may show one or more of these signs, but the pathogen may still be present in the absence of any signs.

Disease signs at the farm, tank or pond level are:

- gaping
- retarded growth
- poor condition or emaciation
- increased mortality.

Gross pathological signs are:

- shrinkage of mantle away from the outer edge of the shell
- occasional lesions in soft tissue
- pale digestive gland
- thin, watery tissue.

Microscopic pathological signs are:

- large, multifocal lesions in the gut epithelium or connective tissue of organs containing *P. marinus* cells
- haemocyte infiltration and phagocytosis of *P. marinus* cells
- destruction of the gut epithelium.

Disease agent

Perkinsosis (or dermo disease) is caused by infection with *Perkinsus marinus*, an alveolate protist in the family *Perkinsidae*. *P. marinus* has been placed nominally in the order Dinoflagellida, but its higher taxonomy is subject to scientific debate. Several other species of the genus *Perkinsus* infect molluscs such as oysters, mussels, clams and abalone worldwide.

Host range

Table 52 Species known to be susceptible to infection with *Perkinsus marinus*

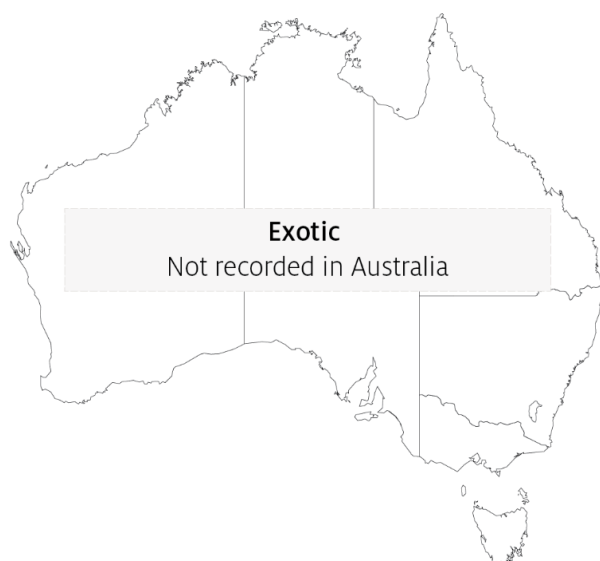Common name	Scientific name
American eastern oyster ^a	<i>Crassostrea virginica</i>
Baltic macoma	<i>Macoma balthica</i>
Blue mussel	<i>Mytilus edulis</i>
Cortez oyster ^a	<i>Crassostrea corteziensis</i>
Mangrove oyster ^a	<i>Crassostrea rhizophorae</i>
Pacific oyster ^a	<i>Crassostrea gigas</i>
Soft shelled clam	<i>Mya arenaria</i>
Suminoe oyster ^a	<i>Crassostrea ariakensis</i>

^a Naturally susceptible. Note: Other species have been shown to be experimentally susceptible.

Presence in Australia

Exotic disease—not recorded in Australia.

Map 36 Presence of *Perkinsus marinus*, by jurisdiction



Epidemiology

- Water temperatures above 20°C encourage proliferation of the parasite. This results in systemic disruption of connective tissue and epithelial cells and leads to high mortalities.
- Reduced salinity levels (below 9ppt) can prevent clinical disease resulting from *P. marinus* infection, even in warm water (above 20°C).
- Cumulative American oyster mortalities of up to 95% have been observed in the first summer following transfer of naïve stock to an area where the disease is known to be present.
- Transmission is horizontal.
- Infection levels increase during spawning and under the stress of oxygen depletion.
- Prevalence and intensity of infection are greatest in oysters more than 1 year old and at depths greater than 90cm.
- Exposure to pollutants will increase the prevalence of infection.

Differential diagnosis

The list of [similar diseases](#) in the next section refers only to the diseases covered by this field guide. Gross pathological signs may also be representative of diseases not included in this guide. Do not rely on gross signs to provide a definitive diagnosis. Use them as a tool to help identify the listed diseases that most closely account for the observed signs.

Similar diseases

Infection with *Perkinsus olseni*.

The clinical signs of infection with *P. marinus* are similar to those of infection with other species of *Perkinsus*. These include occasional pustules in soft tissue, pale digestive gland, poor condition, emaciation, shrinkage of mantle and retarded growth. It is therefore difficult to make a presumptive diagnosis based on gross signs alone. Any presumptive diagnosis requires further laboratory examination.

Sample collection

Only trained personnel should collect samples. Using only gross pathological signs to differentiate between diseases is not reliable, and some aquatic animal disease agents pose a risk to humans. If you are not appropriately trained, phone your state or territory hotline number and report your observations. If you have to collect samples, the agency taking your call will advise you on the appropriate course of action. Local or district fisheries or veterinary authorities may also advise on sampling.

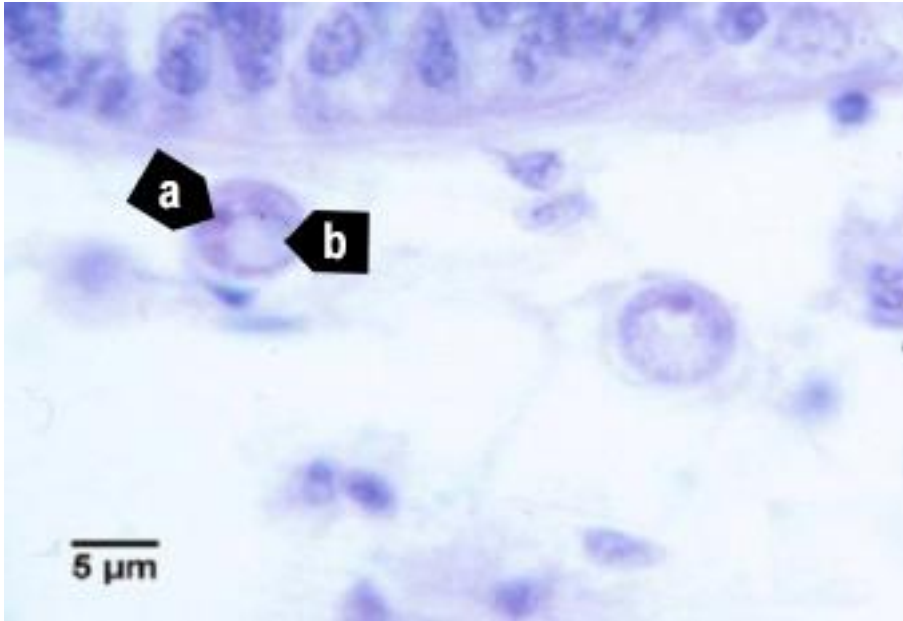
Emergency disease hotline

See something you think is this disease? Report it. Even if you're not sure.

Call the Emergency Animal Disease Watch Hotline on **1800 675 888**. They will refer you to the right state or territory agency.

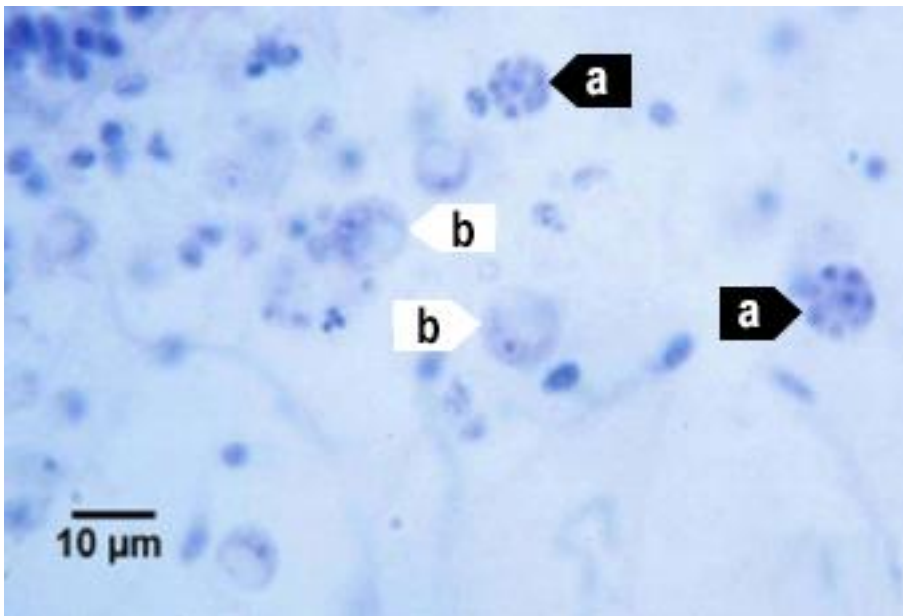
Microscope images

Figure 152 Histopathology of American oyster (*Crassostrea virginica*) infected with *Perkinsus marinus*



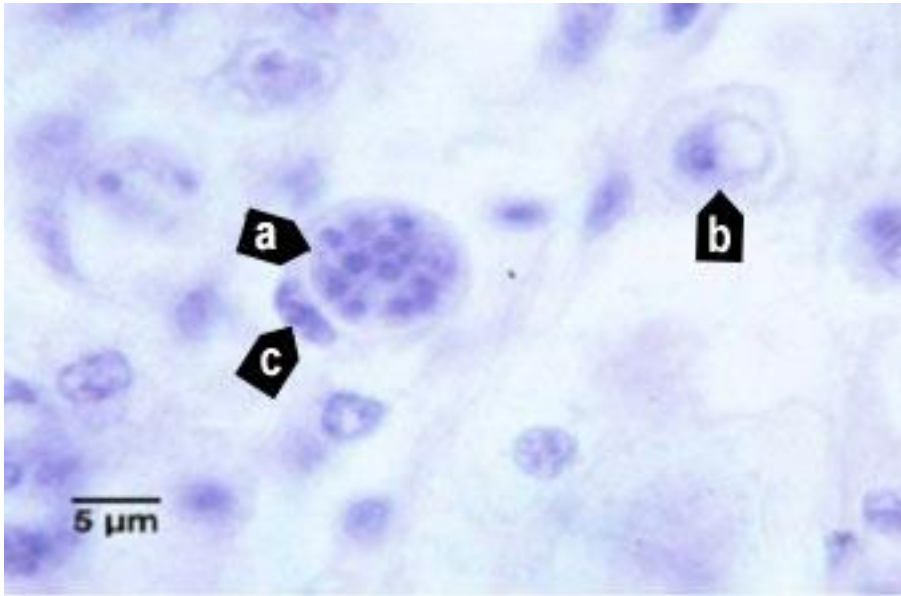
Note: Trophozoite of *P. marinus* with nucleus (a) and distinctive eccentric vacuole (b). Scale bar = 5µm.
Source: E Burreson

Figure 153 Histopathology of American oyster (*Crassostrea virginica*) infected with *Perkinsus marinus*



Note: *P. marinus* 16-cell tomont (a) stages containing immature trophozoites. Maturing trophozoites (b) are also visible.
Scale bar = 10µm.
Source: E Burreson

Figure 154 Histopathology of American oyster (*Crassostrea virginica*) infected with *Perkinsus marinus*



Note: A 16-cell tomont (a) of *P. marinus* containing developing trophozoites. This tomont is contained within a haemocyte (c indicates the nucleus of the phagocytic cell). A maturing trophozoite (b) is nearby. Scale bar = 5 μ m.

Source: E Burreson

Further reading

CABI Invasive Species Compendium [Infection with 'Perkinsus marinus'](#)

CEFAS International Database on Aquatic Animal Diseases [Infection with 'Perkinsus marinus'](#)

World Organisation for Animal Health [Manual of diagnostic tests for aquatic animals](#)

Infection with *Perkinsus olseni*

Also known as perkinsosis and *Perkinsus* disease

Figure 155 Cross-section of foot of greenlip abalone (*Haliotis laevis*) infected with *Perkinsus olseni*



Note: Yellow and smaller brown pustular lesions within the body tissue infected with *P. olseni*.

Source: N Moody, CSIRO Australian Animal Health Laboratory

Signs of disease

Important: Animals with this disease may show one or more of these signs, but the pathogen may still be present in the absence of any signs.

Disease signs at the farm, tank or pond level are:

- morbidity observed in cultured greenlip (*Haliotis laevis*) and blacklip (*H. rubra*) abalone
- gaping in bivalve species
- increased mortality.

Gross pathological signs are:

- spherical brown abscesses up to 8mm in diameter containing a caseous creamy-brown or yellow deposit in the foot and mantle of blacklip and greenlip abalone (affecting marketability)
- thin, watery tissue with a pale digestive gland
- nodules in the mantle or gills.

Microscopic pathological signs are:

- large focal or multifocal necrotic lesions in connective tissue. These contain haemocyte aggregations around individuals or groups of crescent- or signet-ring-shaped *Perkinsus* cells with eccentric vacuoles.

Disease agent

Perkinsosis is caused by infection with *Perkinsus* spp., alveolate protists in the family *Perkinsidae*. *P. olseni* has been placed nominally in the order Dinoflagellida, but its higher taxonomy is subject to scientific debate. Several species of the genus *Perkinsus* infect molluscs such as oysters, mussels, clams and abalone worldwide.

Perkinsus olseni is the main species known to cause this disease in the Asia–Pacific region and is responsible for perkinsosis in abalone, clams and pearl oysters in Australia. *P. atlanticus* is a junior synonym of *P. olseni*. Another species, *P. chesapeaki*, has been detected in wild mud arks (*Anadara trapezia*) in Moreton Bay, Queensland.

Host range

P. olseni appears to have low host specificity and can infect a wide range of bivalve and gastropod molluscs.

Table 53 Species known to be susceptible to infection with *Perkinsus olseni*

Common name	Scientific name
Akoya pearl oyster ^a	<i>Pinctada martensii</i>
Asian littleneck clam ^a	<i>Venerupis philippinarum</i>
Blacklip abalone ^a	<i>Haliotis rubra</i>
Blacklip pearl oyster ^a	<i>Pinctada margaritifera</i>
Crocus clam ^a	<i>Tridacna crocea</i>
Elongated giant clam or rugose giant clam ^a	<i>Tridacna maxima</i>
European aurora venus clam ^a	<i>Venerupis aurea</i>
Giant clam ^a	<i>Tridacna gigas</i>
Greenlip abalone ^a	<i>Haliotis laevis</i>
Green-lipped mussel ^a	<i>Perna canaliculus</i>
Grooved carpet shell or venerid clam ^a	<i>Ruditapes decussatus</i>
Japanese pearl oyster ^a	<i>Pinctada fucata</i>
Kumamoto oyster	<i>Crassostrea sikamea</i>
Manila clam ^a	<i>Ruditapes (Venerupis) philippinarum</i>
New Zealand ark shell ^a	<i>Barbatia novaezelandiae</i>
New Zealand cockle ^a	<i>Austrovenus stutchburyi</i>
New Zealand paua ^a	<i>Haliotis iris</i>
New Zealand pipi ^a	<i>Paphies australis</i>
New Zealand scallop ^a	<i>Pecten novaezelandiae</i>
Pacific oyster ^a	<i>Crassostrea gigas</i>
Pearl oyster ^a	<i>Pinctada sugillata</i>
Pullet carpet shell ^a	<i>Venerupis corrugata</i>
Sand cockle	<i>Katylsia rhytiphora</i>
Silverlip pearl oyster ^a	<i>Pinctada maxima</i>
Southern mud oyster or Australian flat oyster ^a	<i>Ostrea angasi</i>

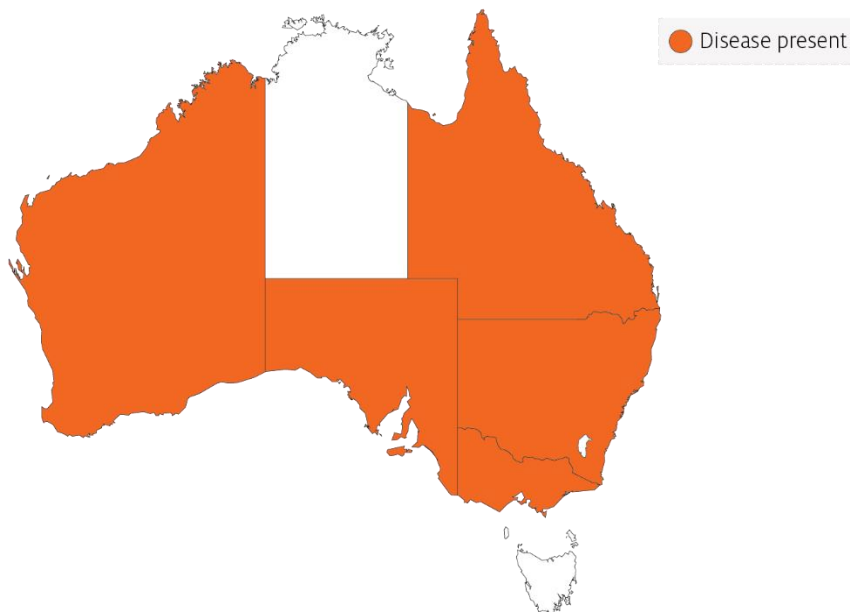
Common name	Scientific name
Staircase abalone ^a	<i>Haliotis scalaris</i>
Suminoe oyster ^a	<i>Crassostrea ariakensis</i>
Sydney cockle or mud ark ^a	<i>Anadara trapezia</i>
Venerid clam ^a	<i>Ruditapes decussatus</i>
Venerid commercial clam ^a	<i>Pitar prostrata</i>
Venus clam	<i>Protothaca jedoensis</i>
Wedge shell	<i>Macomona liliana</i>
Whirling abalone ^a	<i>Haliotis cyclobates</i>

^a Naturally susceptible. Note: Other species have been shown to be experimentally susceptible.

Presence in Australia

Perkinsus olseni has been reported in Queensland, New South Wales, South Australia and Western Australia; and in Australian flat oysters from Victoria. *P. olseni* was originally described from wild abalone in South Australia, but has since been detected in a wide variety of molluscs, including clams and pearl oysters.

Map 37 Presence of *Perkinsus olseni*, by jurisdiction



Epidemiology

- *Perkinsus olseni* has been associated with mass mortality of *Haliotis* spp. (blacklip and greenlip abalone) in the Gulf of St Vincent, South Australia, and coastal New South Wales (mostly blacklip abalone).
- Horizontal transmission occurs directly from host to host. Some environmental conditions (temperature and salinity) can promote a lifelong carrier state. Higher water temperatures (greater than 20°C) can cause disease and mortalities in temperate species such as abalone.
- Infection intensity increases with the age of the host.

- Prezoosporangia that escape from necrotic pustules or decaying dead abalone undergo further development to zoosporangia in seawater.
- Within 9 days at 20°C and 3 days at 28°C, hundreds of motile, biflagellated zoospores (about 3µm by 5µm) exit from the zoosporangium. The zoospores are infective to abalone and other molluscs.
- *P. olsenii* can survive in salt water for several weeks at –20°C. However, the parasite cannot survive below 15ppt salinity.

Differential diagnosis

The list of [similar diseases](#) in the next section refers only to the diseases covered by this field guide. Gross pathological signs may also be representative of diseases not included in this guide. Do not rely on gross signs to provide a definitive diagnosis. Use them as a tool to help identify the listed diseases that most closely account for the observed signs.

Similar diseases

Infection with *Perkinsus marinus*.

The clinical signs of infection with *P. olsenii* are similar to those of infection with other species of *Perkinsus*. These include occasional pustules in soft tissue, pale digestive gland, poor condition, emaciation, shrinkage of mantle and retarded growth. It is therefore difficult to make a presumptive diagnosis based on gross signs alone. Any presumptive diagnosis requires further laboratory examination.

Sample collection

Only trained personnel should collect samples. Using only gross pathological signs to differentiate between diseases is not reliable, and some aquatic animal disease agents pose a risk to humans. If you are not appropriately trained, phone your state or territory hotline number and report your observations. If you have to collect samples, the agency taking your call will advise you on the appropriate course of action. Local or district fisheries or veterinary authorities may also advise on sampling.

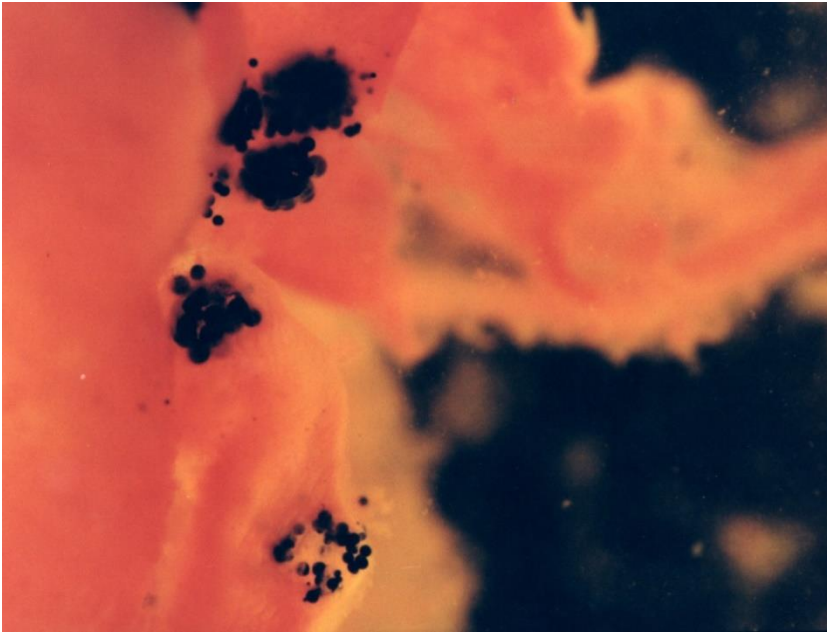
Emergency disease hotline

See something you think is this disease? Report it. Even if you're not sure.

Call the Emergency Animal Disease Watch Hotline on **1800 675 888**. They will refer you to the right state or territory agency.

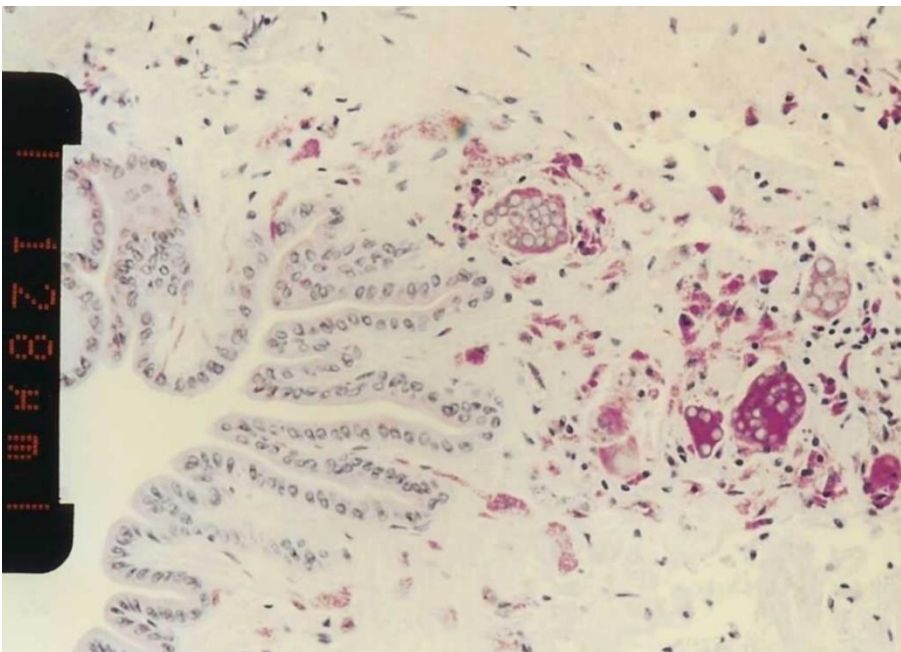
Microscope images

Figure 156 Tissue of New Zealand cockle (*Austrovenus stutchburyi*) infected with *Perkinsus olseni*



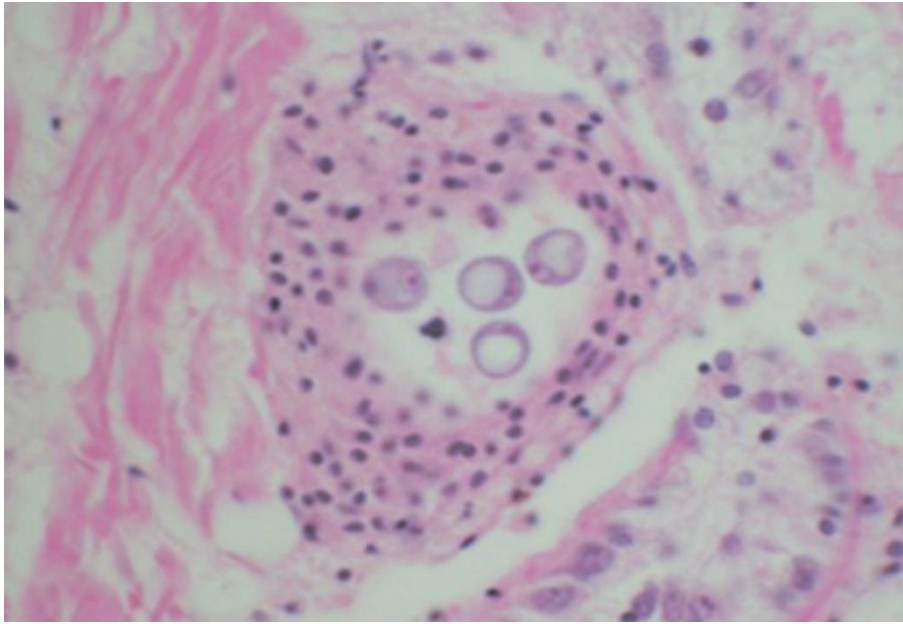
Note: Greatly enlarged individual trophozoites (also called hypnospores) of *P. olseni*. Sample was stained black by Lugol's iodine after infected tissue was incubated in Ray's fluid thioglycollate medium. Stained tissue is visible with the naked eye.
Source: B Diggles

Figure 157 Histopathology of New Zealand cockle (*Austrovenus stutchburyi*) infected with *Perkinsus olseni*



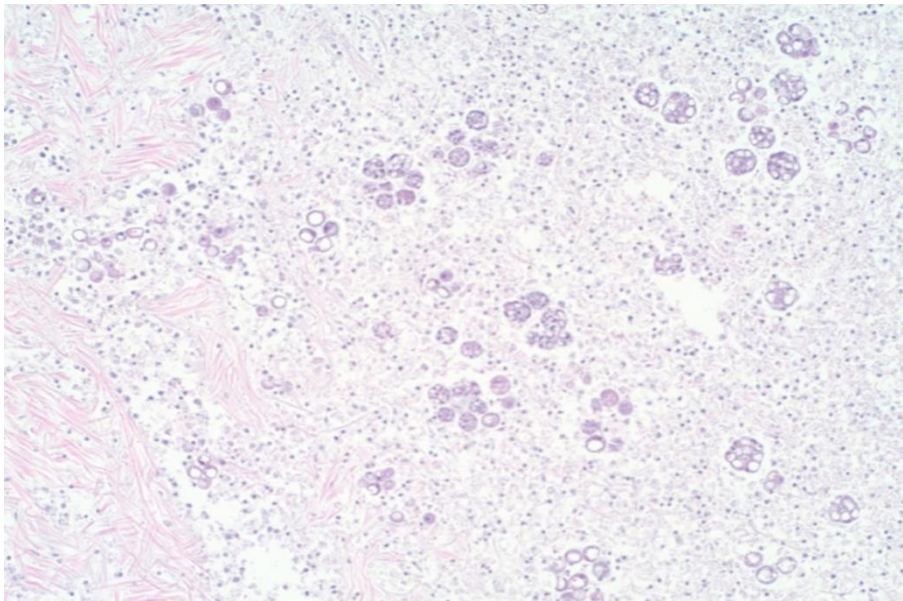
Note: Clusters of developing *P. olseni* trophozoites surrounded by a strongly eosinophilic periodic acid-Schiff positive amorphous matrix and a host response. Scale bar = 128 μ m.
Source: B Diggles

Figure 158 Histopathology of clam (*Ruditapes* sp.) infected with *Perkinsus olseni*



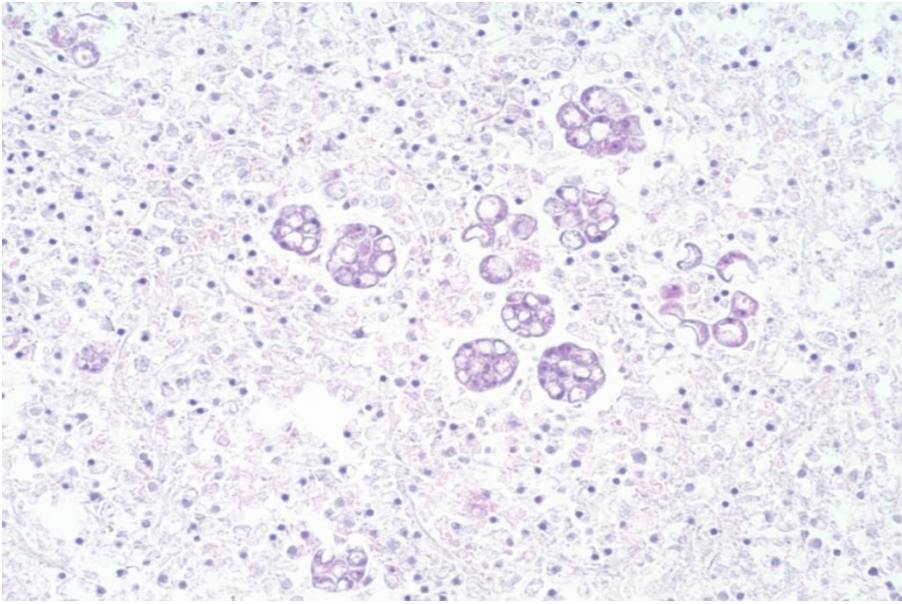
Note: A cluster of signet-ring-shaped *P. olseni* trophozoites surrounded by an encapsulating host response.
Source: E Burreson

Figure 159 Pedal tissue of greenlip abalone (*Haliotis laevis*) infected with *Perkinsus olseni*



Note: The lesion contains multilocular *P. olseni* clusters among haemocytes and floccular debris. Haematoxylin and eosin stain. 100x magnification.
Source: S Bastianello

Figure 160 Pedal tissue of greenlip abalone (*Haliotis laevigata*) infected with *Perkinsus olseni*



Note: Higher magnification view of Figure 100. Multilocular *P. olseni* clusters, and more mature signet-ring-shaped organisms among haemocytes and floccular debris. Haematoxylin and eosin stain. 200x magnification.

Source: S Bastianello

Further reading

CABI Invasive Species Compendium [Infection with 'Perkinsus olseni'](#)

CEFAS International Database on Aquatic Animal Diseases [Infection with 'Perkinsus olseni'](#)

World Organisation for Animal Health [Manual of diagnostic tests for aquatic animals](#)

4. Diseases of crustaceans

Viral diseases of crustaceans

Infection with gill-associated virus (GAV)

Also known as mid-crop mortality syndrome and infection with yellowhead virus genotype 2 (YHV2)

Figure 161 Black tiger prawn (*Penaeus monodon*) infected with GAV



Note: Red colouration of prawn appendages and tail.

Source: D Callinan

Signs of disease

Important: Animals with this disease may show one or more of these signs, but the pathogen may still be present in the absence of any signs.

- Disease signs at the farm, tank or pond level are:
- high mortality (up to 80%)
- moribund prawns aggregating near the surface at pond edges
- initial increase in feeding at an abnormally high rate, followed by a sudden decline.
- Gross pathological signs are:
- reddening of body and appendages
- biofouling with exoparasites
- emaciation
- pink to yellow colouration of the gills.
- Microscopic pathological signs are:
- lymphoid organ necrosis (hypertrophied nuclei, marginated chromatin and vacuolation).

Disease agent

GAV is also known as YHV2, which is genotype 2 of at least 10 genotypes in the yellowhead complex of viruses. GAV is the type species of the genus *Okavirus*, in the family *Roniviridae* and order Nidovirales.

Comparison of DNA sequences indicates that GAV and yellowhead virus genotype 1 (YHV1) are closely related but have distinctly different genotypes, sharing 85% of their genetic material. Natural genetic recombination between GAV and other genotypes in the yellowhead complex has been reported outside Australia.

Other known genotypes in the complex (genotypes 3 to 10) occur in *Penaeus monodon* in East Africa, Asia and Australia. Most are rarely or never associated with disease.

Host range

Table 54 Species known to be susceptible to infection with GAV

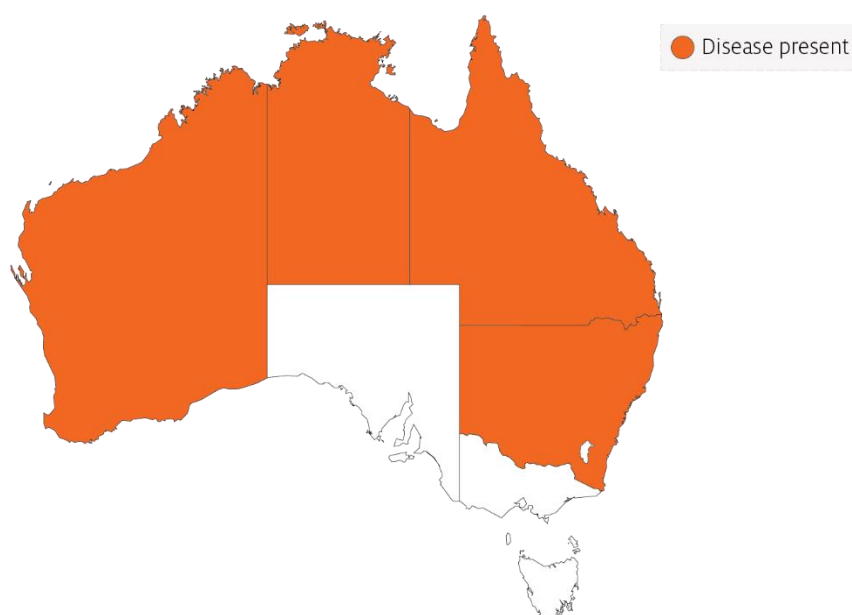
Common name	Scientific name
Black tiger prawn ^a	<i>Penaeus monodon</i>
Brown tiger prawn	<i>Penaeus esculentus</i>
Gulf banana prawn	<i>Penaeus (Fenneropenaeus) merguensis</i>
Kuruma prawn	<i>Penaeus (Marsupenaeus) japonicus</i>

^a Naturally susceptible. Note: Other species have been shown to be experimentally susceptible.

Presence in Australia

GAV has been officially reported from New South Wales, Queensland, the Northern Territory and Western Australia. Other genotypes within the yellowhead complex are known to occur in Australia, including YHV6 and YHV7.

Map 38 Presence of GAV, by jurisdiction



Epidemiology

The epidemiology of GAV is thought to be very similar to that of yellowhead virus:

- Transmission can be horizontal, directly from the water column and through ingestion of infected material.
- Vertical transmission can occur via surface contamination or infection of tissue surrounding the fertilised egg.
- Viral multiplication and disease appear to be induced by environmental stress.
- Mortality usually occurs among early to late juvenile stages in rearing ponds.
- Experimental infections with GAV indicate that larger (approximately 20g) Kuruma prawns are less susceptible to disease than smaller (approximately 6 to 13g) prawns of the same species.
- GAV has been associated with mortalities of up to 80% in black tiger prawn ponds in Australia.

GAV genotypes YHV2 and YHV7 occur commonly as a chronic infection in healthy broodstock and farmed black tiger prawns in eastern Australia. YHV2 has also been associated with acute infections and disease outbreaks in ponds, causing high mortality. However, it produces gross signs and patterns of tissue tropism that differ from those for yellowhead virus genotype 1.

Differential diagnosis

The list of [similar diseases](#) in the next section refers only to the diseases covered by this field guide. Gross pathological signs may also be representative of diseases not included in this guide. Do not rely on gross signs to provide a definitive diagnosis. Use them as a tool to help identify the listed diseases that most closely account for the observed signs.

Similar diseases

Infection with yellowhead virus genotype 1 (YHV1).

GAV and YHV1 are closely related viruses, so molecular testing is required to discriminate between the two disease agents and between other YHV genotypes that are endemic to Australia (YHV6 and YHV7).

Sample collection

Only trained personnel should collect samples. Using only gross pathological signs to differentiate between diseases is not reliable, and some aquatic animal disease agents pose a risk to humans. If you are not appropriately trained, phone your state or territory hotline number and report your observations. If you have to collect samples, the agency taking your call will advise you on the appropriate course of action. Local or district fisheries or veterinary authorities may also advise on sampling.

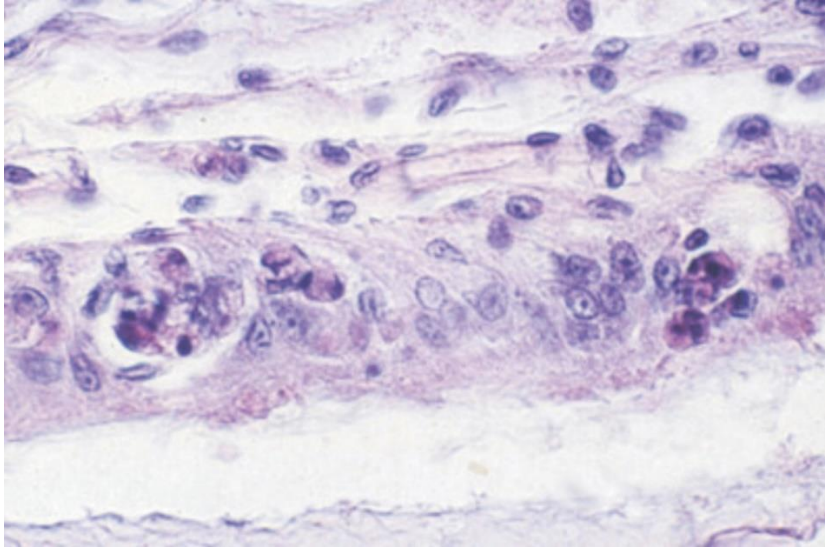
Emergency disease hotline

See something you think is this disease? Report it. Even if you're not sure.

Call the Emergency Animal Disease Watch Hotline on **1800 675 888**. They will refer you to the right state or territory agency.

Microscope images

Figure 162 Histopathology of lymphoid organ of black tiger prawn (*Penaeus monodon*) infected with GAV



Note: Lymphoid necrosis includes signs such as hypertrophied nuclei, marginated chromatin and vacuolation.
Source: L Owens

Further reading

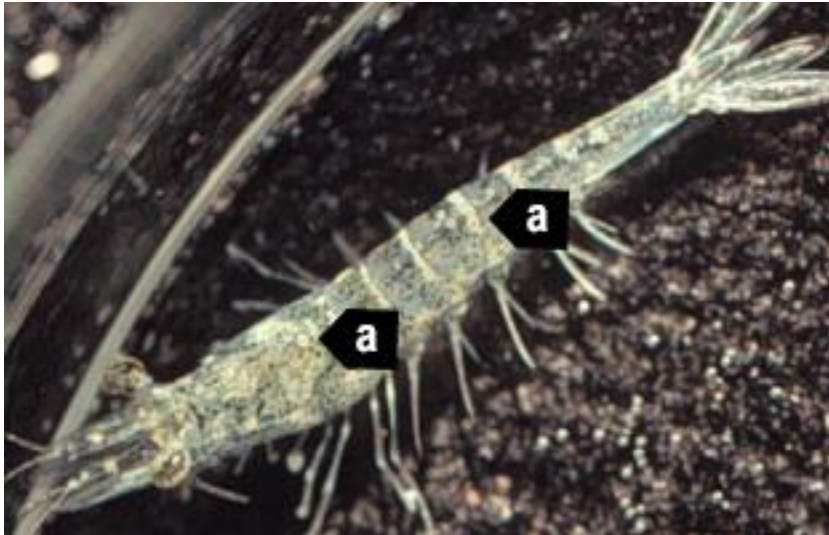
CABI Invasive Species Compendium [Gill-associated virus](#)

World Organisation for Animal Health [Manual of diagnostic tests for aquatic animals](#)

Infection with infectious hypodermal and haematopoietic necrosis virus (IHHNV)

Also known as infectious hypodermal and haematopoietic necrosis (IHHN), infection with *Penaeus stylirostris* densovirus (PstDNV) and runt deformity syndrome (RDS)

Figure 163 Infection with IHHNV in juvenile Pacific blue shrimp (*Penaeus (Litopenaeus) stylirostris*)



Note: White to buff lesions under carapace (a).

Source: DV Lightner

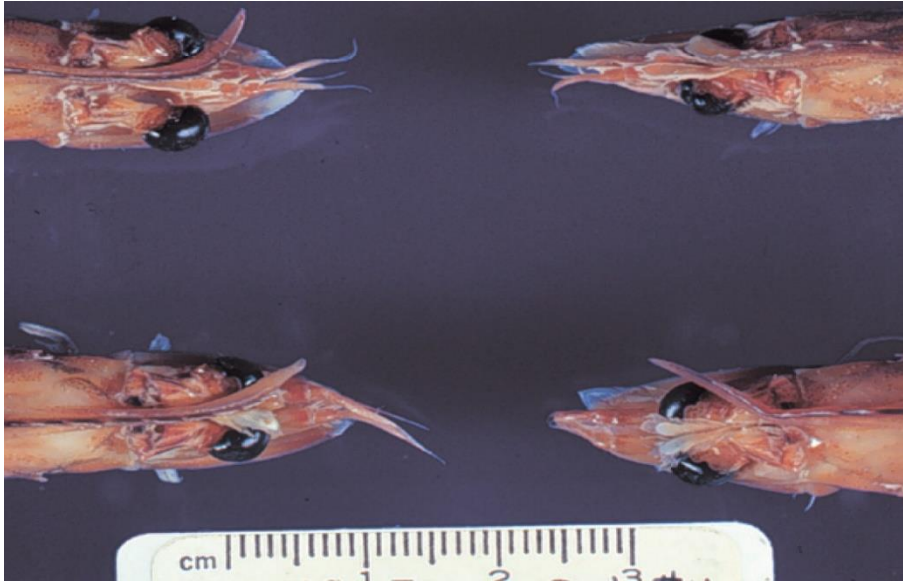
Figure 164 Runt deformity syndrome due to infection with IHHNV in juvenile black tiger prawn (*Penaeus monodon*)



Note: Deformity of the sixth abdominal segment.

Source: B Diggles

Figure 165 Runt deformity syndrome in juvenile Pacific blue shrimp (*Penaeus (Litopenaeus) stylirostris*) infected with IHNV



Note: Classic rostrum deformation.

Source: DV Lightner

Signs of disease

Important: Animals with this disease may show one or more of these signs, but the pathogen may still be present in the absence of any signs.

Disease signs at the farm, tank or pond level are:

- reduced food consumption
- cannibalism
- repeatedly floating slowly to the water surface, rolling over and then sinking to the bottom
- morbidity or mortality
- poor hatching success of eggs
- poor survival of larvae and postlarvae.

Gross pathological signs are:

- opaque abdominal musculature
- white to buff lesions under the carapace.

In Pacific blue shrimp, Pacific white shrimp and black tiger prawns, additional gross pathological signs are:

- blue appearance of moribund prawns
- runt deformity syndrome, the effects of which include
 - reduced and irregular growth in juveniles and subadults
 - deformed rostrums growing to one side
 - deformed sixth abdominal segment.

In Pacific blue shrimp, further gross pathological signs are:

- cuticular roughness
- cuticular deformities
- white to buff mottling of the shell, especially at the junction of abdominal shell plates.

Microscopic pathological signs are:

- eosinophilic to pale basophilic intranuclear inclusion bodies (Cowdry type A inclusions) within tissues of ectodermal and mesodermal origin. These inclusion bodies may be easily confused with developing intranuclear inclusion bodies caused by white spot disease.

Disease agent

IHHNV causes runt deformity syndrome (RDS). IHHNV is a densovirus belonging to the family *Parvoviridae* (subfamily Densovirinae, genus *Brevidensovirus*). At least 3 distinct genotypes of IHHNV have been identified, but only 2 are known to be infectious to either Pacific white shrimp (*Penaeus (Litopenaeus) vannamei*) or black tiger prawns (*Penaeus monodon*). Homologues of portions of the IHHNV genome have been reported from the genomes of host prawns.

Host range

Table 55 Species known to be susceptible to IHHNV

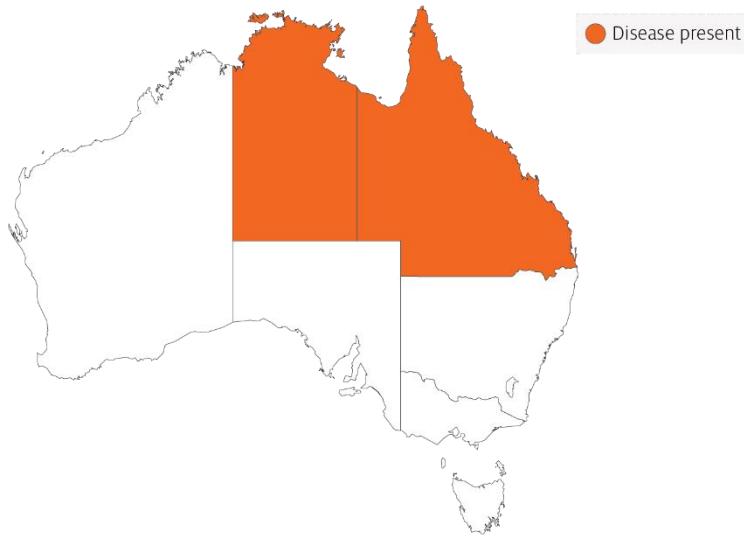
Common name	Scientific name
Argentine stiletto shrimp	<i>Artemesia longinaris</i>
Black tiger prawn ^a	<i>Penaeus monodon</i>
Brush clawed shore crab	<i>Hemigrapsus penicillatus</i>
Chinese white shrimp ^a	<i>Penaeus (Fenneropenaeus) chinensis</i>
Cuata swimcrab	<i>Callinectes arcuatus</i>
Giant freshwater prawn ^a	<i>Macrobrachium rosenbergii</i>
Green tiger prawn or grooved tiger prawn ^a	<i>Penaeus semisulcatus</i>
Gulf banana prawn	<i>Penaeus (Fenneropenaeus) merguensis</i>
Indian banana prawn	<i>Penaeus (Fenneropenaeus) indicus</i>
Kuruma prawn ^a	<i>Penaeus (Marsupenaeus) japonicus</i>
Louisiana swamp crayfish ^a	<i>Procambarus clarkii</i>
Northern brown shrimp	<i>Penaeus (Farfantepenaeus) aztecus</i>
Northern pink shrimp	<i>Penaeus (Farfantepenaeus) duorarum</i>
Northern white shrimp	<i>Penaeus (Litopenaeus) setiferus</i>
Pacific blue shrimp ^a	<i>Penaeus (Litopenaeus) stylirostris</i>
Pacific white shrimp ^a	<i>Penaeus (Litopenaeus) vannamei</i>
Southern white shrimp ^a	<i>Penaeus (Litopenaeus) schmitti</i>
Western white shrimp ^a	<i>Penaeus (Litopenaeus) occidentalis</i>
Yellow-leg shrimp ^a	<i>Penaeus (Farfantepenaeus) californiensis</i>

^a Naturally susceptible.

Presence in Australia

IHHNV has been officially reported in black tiger prawns from the Northern Territory and Queensland.

Map 39 Presence of IHHNV, by jurisdiction



Epidemiology

- Gross signs of disease in an infected animal become evident from about 35 days into postlarval development.
- IHHNV-resistant prawns and early life stages are carriers, and may transfer the virus to more susceptible species and life stages.
- The typical gross signs of runt deformity syndrome may be observed in juveniles and subadults.
- Mortality events seldom occur in infected adult prawns.
- IHHNV suppresses the prawn's immune system, allowing infection by other disease agents.
- Infected tissue remains infectious after 5 years of storage at -20°C , after 10 years at -80°C , and after storage in 50% glycerine.
- IHHNV infection can result in cumulative mortalities as high as 90% in postlarvae and juveniles.
- Transmission of IHHNV can be via horizontal or vertical routes. Horizontal transmission has been demonstrated by cannibalism or through contaminated water. Vertical transmission has been demonstrated via infected eggs.

Differential diagnosis

The list of [similar diseases](#) in the next section refers only to the diseases covered by this field guide. Gross pathological signs may also be representative of diseases not included in this guide. Do not rely on gross signs to provide a definitive diagnosis. Use them as a tool to help identify the listed diseases that most closely account for the observed signs.

Similar diseases

Infection with white spot syndrome virus (WSSV).

Sample collection

Only trained personnel should collect samples. Using only gross pathological signs to differentiate between diseases is not reliable, and some aquatic animal disease agents pose a risk to humans. If you are not appropriately trained, phone your state or territory hotline number and report your observations. If you have to collect samples, the agency taking your call will advise you on the appropriate course of action. Local or district fisheries or veterinary authorities may also advise on sampling.

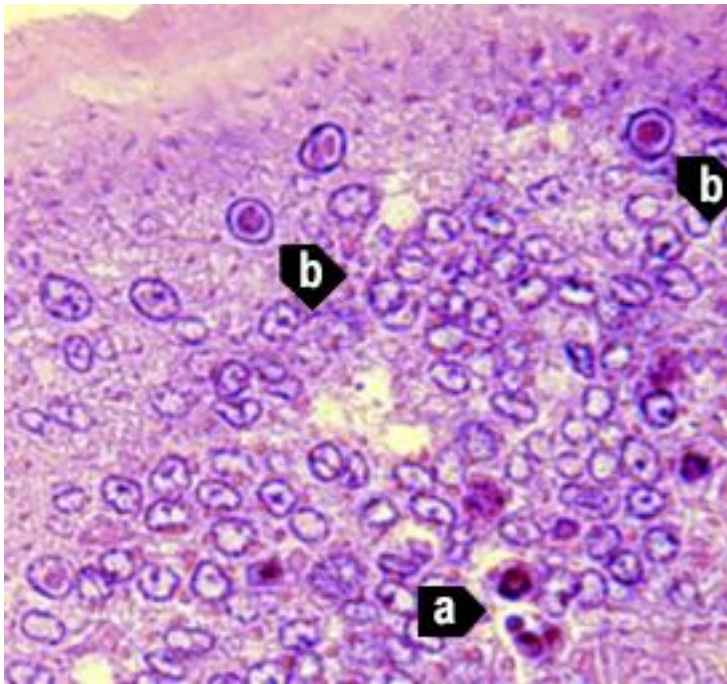
Emergency disease hotline

See something you think is this disease? Report it. Even if you're not sure.

Call the Emergency Animal Disease Watch Hotline on **1800 675 888**. They will refer you to the right state or territory agency.

Microscope images

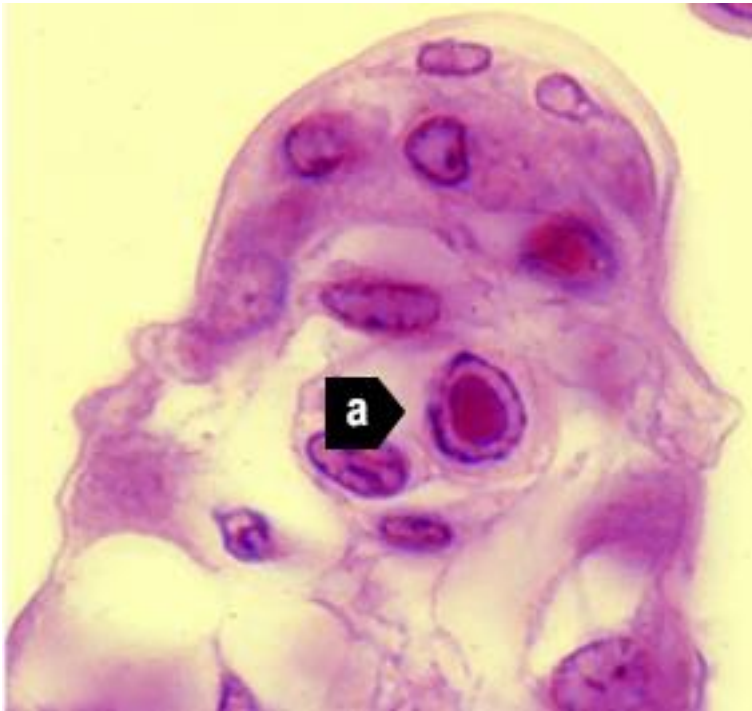
Figure 166 Cuticular epithelium and subcuticular connective tissue near heart of juvenile Pacific blue shrimp (*Penaeus (Litopenaeus) stylirostris*) with severe acute IHHN



Note: Section stained with haematoxylin and eosin. Numerous necrotic cells with pyknotic nuclei (a) or with pathognomonic eosinophilic intranuclear inclusion bodies (Cowdry type A) (b).

Source: DV Lightner

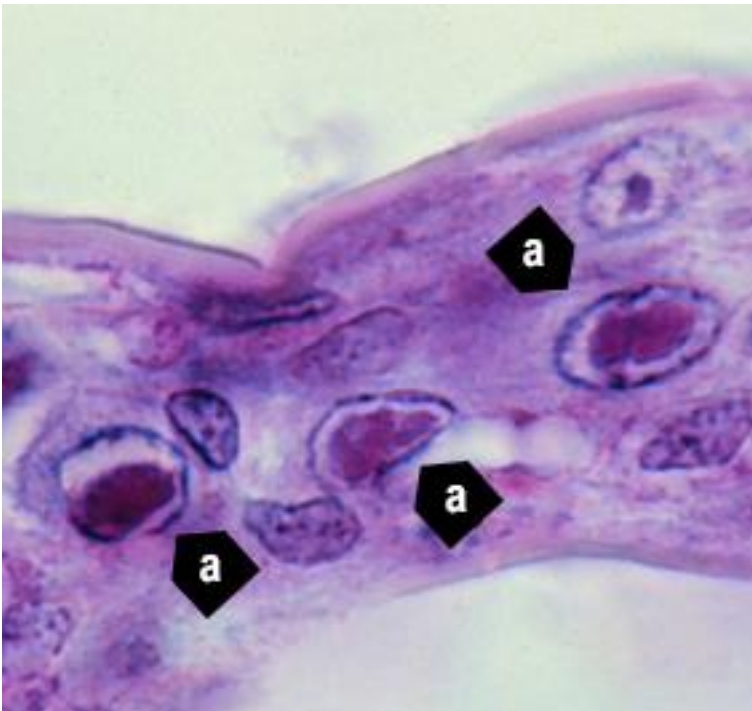
Figure 167 Gills of juvenile Pacific blue shrimp (*Penaeus (Litopenaeus) stylirostris*) with severe acute IHHN



Note: Numerous necrotic cells (a) with pathognomonic eosinophilic intranuclear inclusion bodies (Cowdry type A) that are pathognomonic for IHHNV infection. 1800x magnification.

Source: DV Lightner

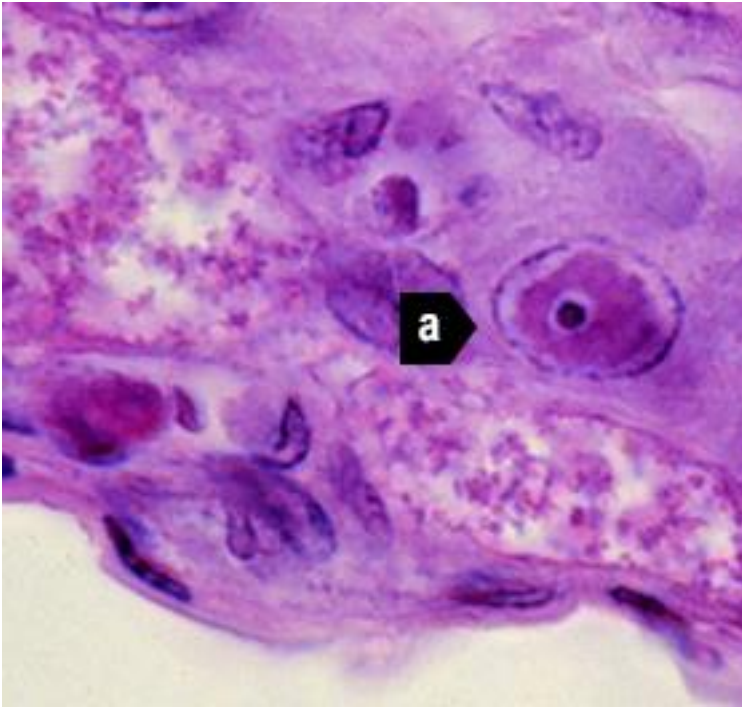
Figure 168 Gill lamella with diagnostic IHHNV Cowdry type A inclusions



Note: Light micrograph shows 3 adjacent cells with diagnostic IHHNV Cowdry type A inclusions (a) in hypertrophied nuclei. 1800x magnification.

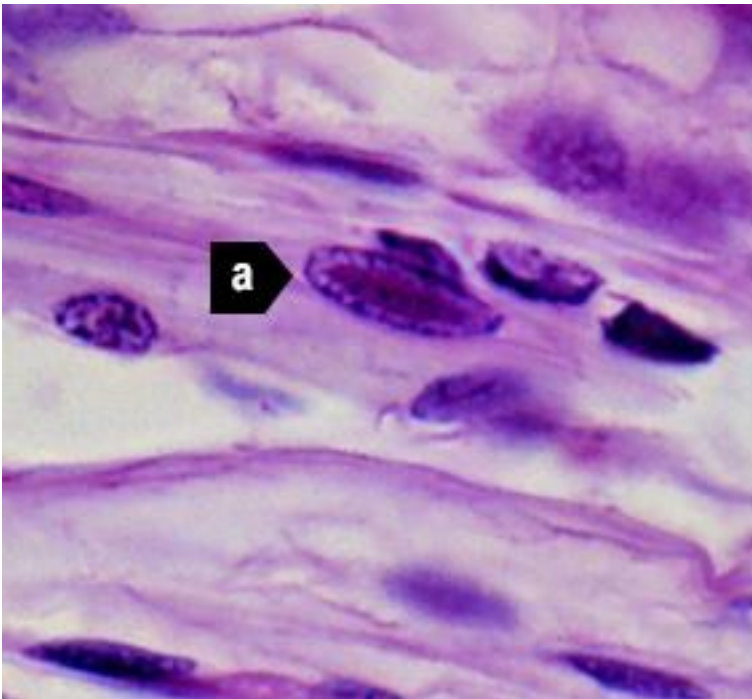
Source: DV Lightner

Figure 169 IHNV Cowdry type A inclusion in nucleus of gill epithelial cell



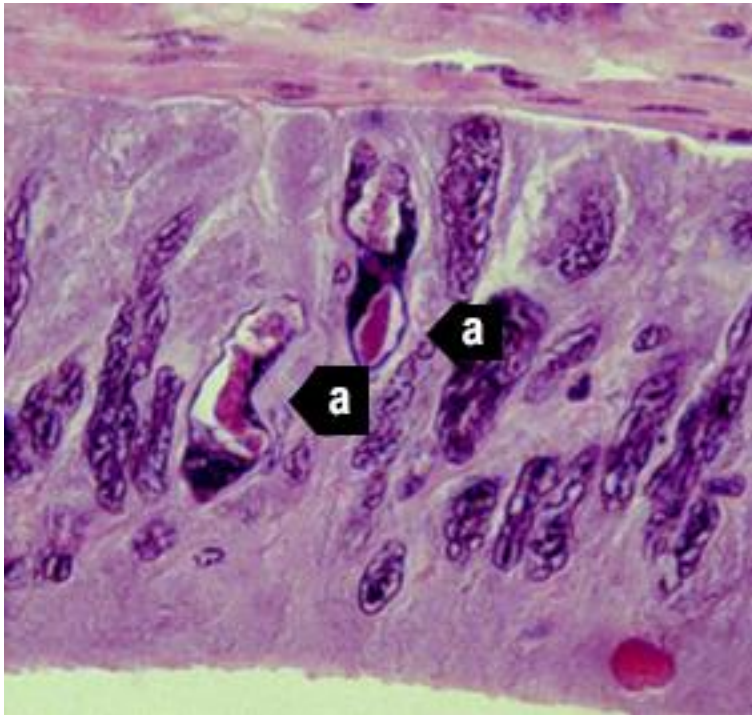
Note: Light micrograph shows a chromatin process within the inclusion body (a). 1800x magnification.
Source: DV Lightner

Figure 170 Midsagittal section of ventral nerve cord of juvenile Pacific white shrimp (*Penaeus (Litopenaeus) vannamei*) with IHNV



Note: Cowdry type A inclusions take the shape of the host cell nucleus (a). In the nerve cord, they are often elliptical and appear slightly different from Cowdry type A inclusions in other tissue. 1800x magnification.
Source: DV Lightner

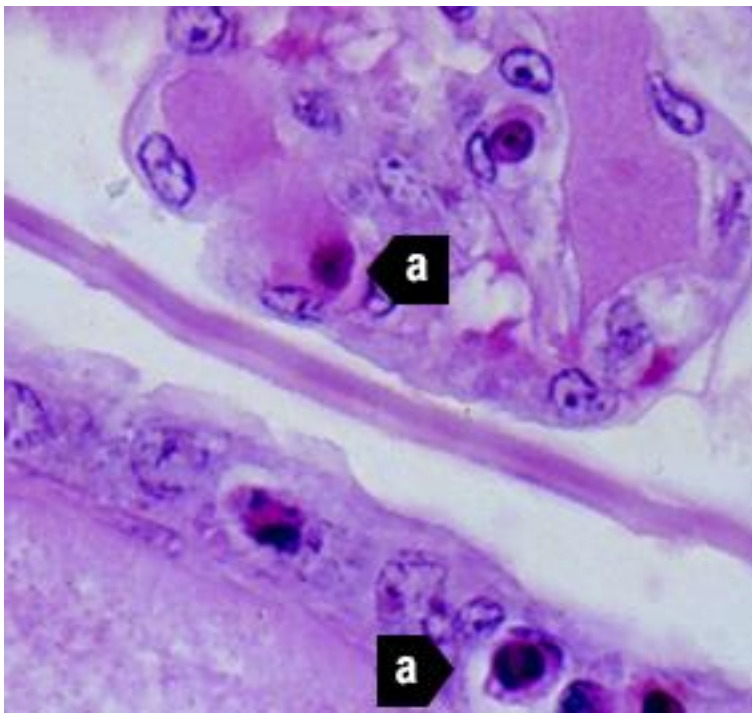
Figure 171 Photomicrograph of vas deferens of adult Pacific white shrimp (*Penaeus (Litopenaeus) vannamei*) with IHHN



Note: Cowdry type A inclusions in the vas deferens may be unusually shaped (a) because they take on the shape of the nuclei of the tissue. 700x magnification.

Source: DV Lightner

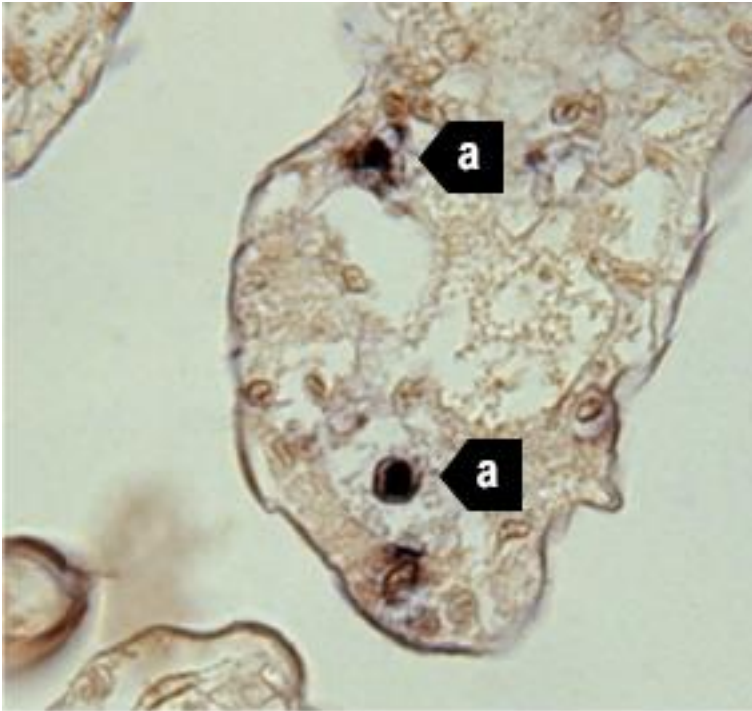
Figure 172 Gills of juvenile Pacific blue shrimp (*Penaeus (Litopenaeus) stylirostris*) with IHHN



Note Section stained with haematoxylin and eosin. Although necrotic cells with pyknotic nuclei are numerous (a), no diagnostic Cowdry type A inclusions are apparent 700x magnification.

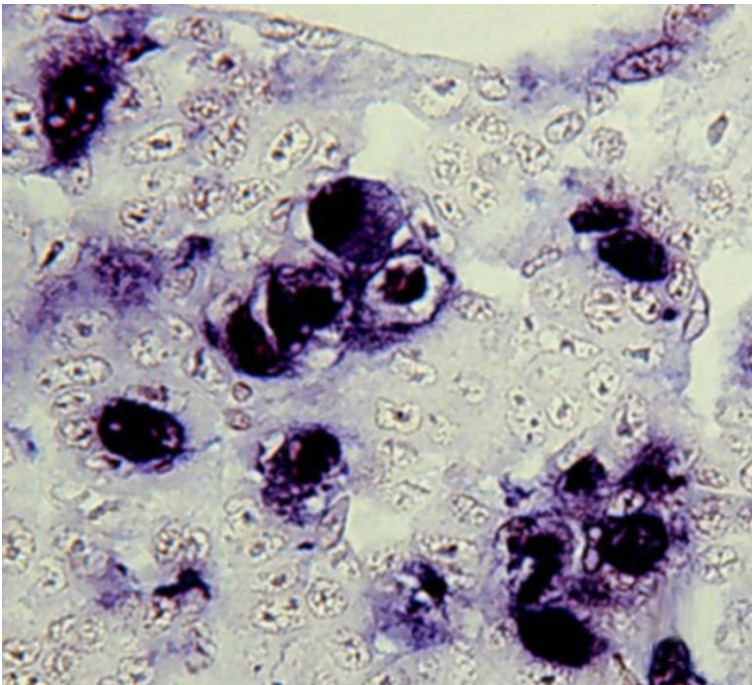
Source: DV Lightner

Figure 173 Gills of juvenile Pacific blue shrimp (*Penaeus (Litopenaeus) stylirostris*) with IHNV



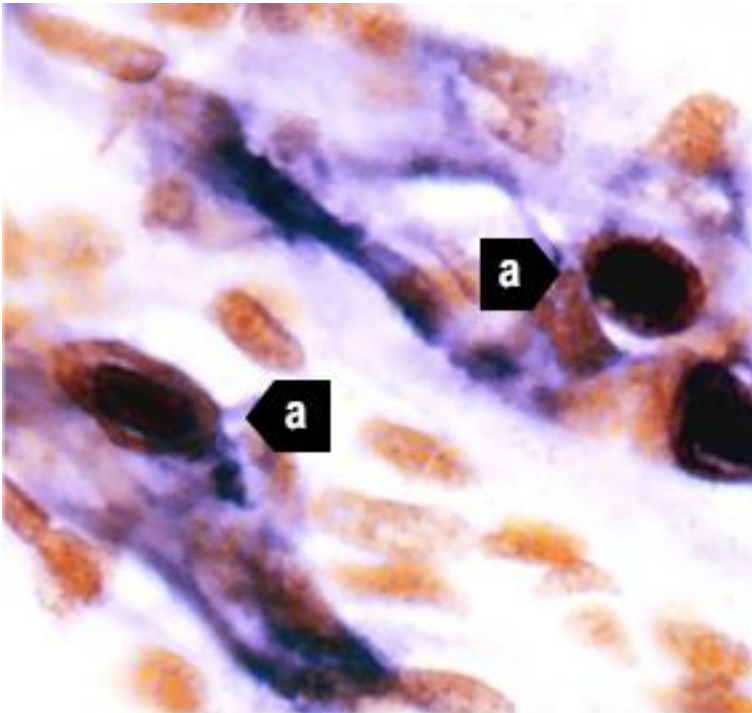
Note: In situ hybridisation section. Several IHNV-infected cell nuclei have reacted with the digoxigenin labelled probe (a), although no diagnostic Cowdry type A inclusions are apparent. 700x magnification.
Source: DV Lightner

Figure 174 Haematopoietic tissue from juvenile Pacific blue shrimp (*Penaeus (Litopenaeus) stylirostris*) with IHNV



Note: In situ hybridisation section. Digoxigenin (DIG)-labelled probe shows abundant DIG-positive cells where cellular debris or haemolymph have a high content of IHNV. 700x magnification.
Source: DV Lightner

Figure 175 Midsagittal section of juvenile white shrimp (*Penaeus (Litopenaeus) vannamei*) with IHHN



Note: The digoxigenin-labelled probe has reacted with several Cowdry type A inclusions (a) and with cellular debris or haemolymph with a high content of IHNV. 600x magnification.

Source: DV Lightner

Further reading

CABI Invasive Species Compendium [Infectious hypodermal and haematopoietic necrosis](#)

CEFAS International Database on Aquatic Animal Diseases [Infectious hypodermal and haematopoietic necrosis](#)

World Organisation for Animal Health [Manual of diagnostic tests for aquatic animals](#)

Infection with infectious myonecrosis virus (IMNV)

Also known as infectious myonecrosis

Exotic disease

Figure 176 Gross signs of infectious myonecrosis in naturally infected farmed Pacific white shrimp (*Penaeus (Litopenaeus) vannamei*)



Note: Various degrees of skeletal muscle necrosis, visible as an opaque, whitish discoloration of the abdomen.

Source: DV Lightner

Figure 177 Gross signs of infectious myonecrosis in naturally infected farmed Pacific white shrimp (*Penaeus (Litopenaeus) vannamei*)



Note: Reddened tail, and skeletal muscle necrosis visible as an opaque, whitish discoloration of the abdominal segments.

Source: DV Lightner

Signs of disease

Important: Animals with this disease may show one or more of these signs, but the pathogen may still be present in the absence of any signs.

Disease signs at the farm, tank or pond level are:

- lethargy
- large numbers of moribund animals and significant mortalities (up to 70%), during or following stressful events
- The acute form of the disease produces gross signs and elevated mortalities, but disease progresses to a chronic phase with persistent low-level mortalities.

Gross pathological signs are:

- focal to extensive white necrotic areas in the striated muscle commonly observed in distal abdominal segments
- necrotic and reddened tail fan
- lymphoid organs increased to 3 to 4 times normal size
- moribund prawns with a full stomach because affected individuals may continue to feed until death.

Microscopic pathological signs are:

- coagulative necrosis of skeletal muscle by haemocytic infiltration and fibrosis.

Disease agent

Infectious myonecrosis is caused by infection with infectious myonecrosis virus (IMNV), a putative totivirus. Phylogenetic analysis based on its RNA-dependent RNA polymerase gene coding sequence groups IMNV most closely with *Giardia lamblia* virus, a member of the family Totiviridae.

Host range

Table 56 Species known to be susceptible to IMNV

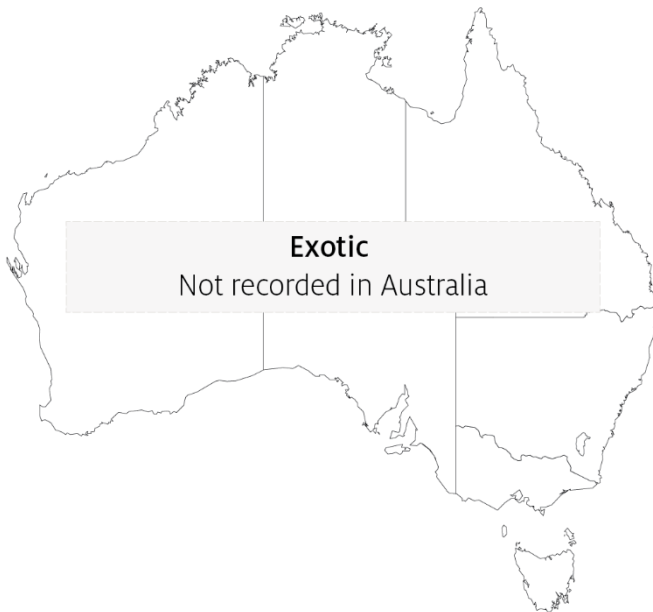Common name	Scientific name
Black tiger prawn	<i>Penaeus monodon</i>
Brown tiger prawn	<i>Penaeus esculentus</i>
Gulf banana prawn	<i>Penaeus (Fenneropenaeus) merguensis</i>
Pacific blue shrimp	<i>Penaeus (Litopenaeus) stylirostris</i>
Pacific white shrimp ^a	<i>Penaeus (Litopenaeus) vannamei</i>
Southern brown shrimp	<i>Penaeus (Farfantepenaeus) subtilis</i>

^a Naturally susceptible.

Presence in Australia

Exotic disease—not recorded in Australia.

Map 40 Presence of IMNV, by jurisdiction



Epidemiology

- IMNV was originally identified in northeastern Brazil in cultured *Penaeus (Litopenaeus) vannamei*. The virus has since been reported in South-East Asia, including Indonesia, India and Sri Lanka.
- Clinical signs may have sudden onset following stressful events (such as capture by net, reduced feeding or sudden changes in temperature or salinity).
- Affected life stages include juveniles and subadults. Significant mortalities occur in juvenile and subadult pond-reared populations.
- Horizontal transmission has been demonstrated via cannibalism. Vertical transmission (direct passage from parents to offspring via eggs or sperm) is likely but not confirmed.

Differential diagnosis

The list of [similar diseases](#) in the next section refers only to the diseases covered by this field guide. Gross pathological signs may also be representative of diseases not included in this guide. Do not rely on gross signs to provide a definitive diagnosis. Use them as a tool to help identify the listed diseases that most closely account for the observed signs.

The clinical signs described and shown here may also be symptomatic of other bacterial or viral infections or poor water quality. Further laboratory examination is needed for a definitive diagnosis.

Similar diseases

Infection with *Macrobrachium rosenbergii* nodavirus (MrNV) and infection with shrimp haemocyte iridescent virus (SHIV).

Sample collection

Only trained personnel should collect samples. Using only gross pathological signs to differentiate between diseases is not reliable, and some aquatic animal disease agents pose a risk to humans. If you are not appropriately trained, phone your state or territory hotline number and report your observations. If you have to collect samples, the agency taking your call will advise you on the appropriate course of action. Local or district fisheries or veterinary authorities may also advise on sampling.

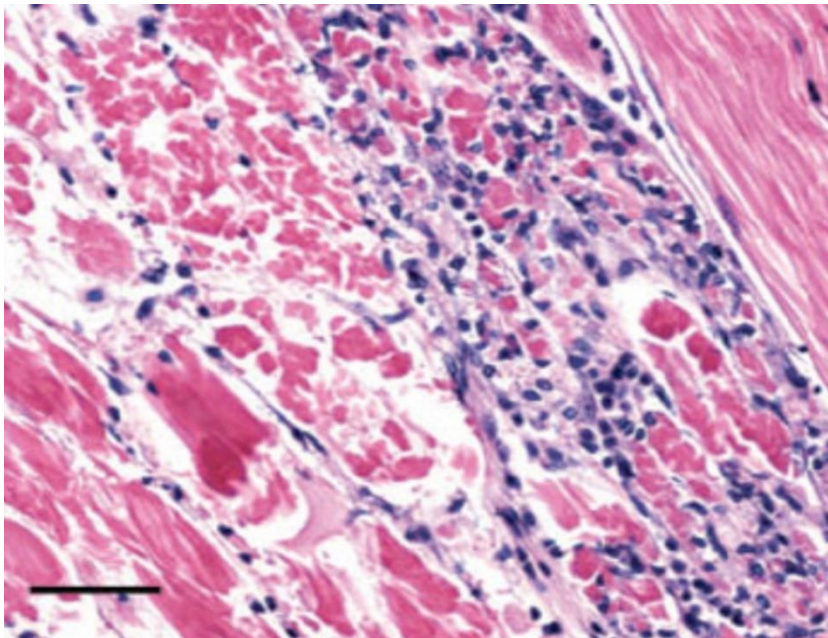
Emergency disease hotline

See something you think is this disease? Report it. Even if you're not sure.

Call the Emergency Animal Disease Watch Hotline on **1800 675 888**. They will refer you to the right state or territory agency.

Microscope images

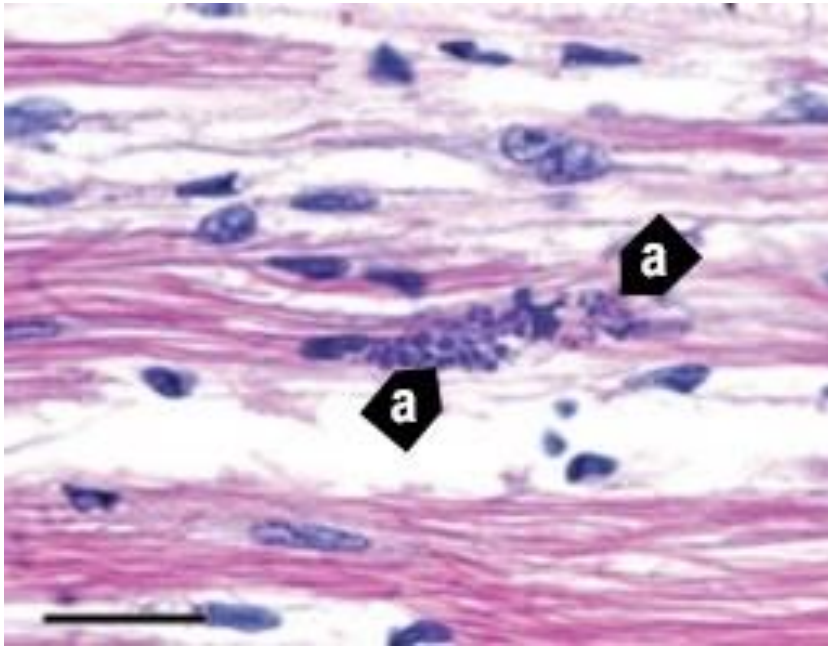
Figure 178 Skeletal muscle of Pacific white shrimp (*Penaeus (Litopenaeus) vannamei*) infected with IMNV



Note: Coagulative necrosis of skeletal muscle accompanied by haemocytic infiltration and fibrosis. Normal skeletal muscle can be observed in the upper right corner. Haematoxylin and eosin stain Scale bar = 50µm.

Source: DV Lightner

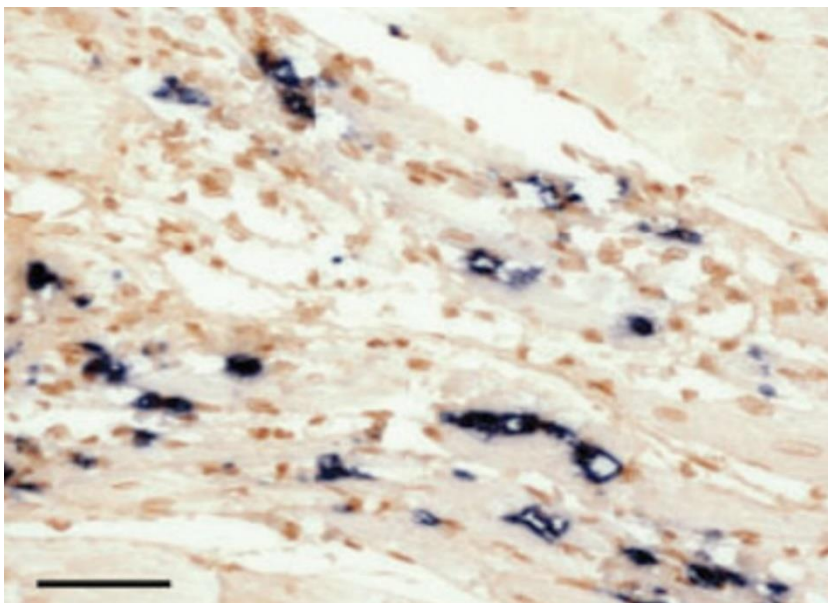
Figure 179 Muscle cells of Pacific white shrimp (*Penaeus (Litopenaeus) vannamei*) infected with IMNV



Note: Perinuclear pale basophilic to dark basophilic inclusion bodies in a group of muscle cells (a). Haematoxylin and eosin stain. Scale bar = 20µm.

Source: DV Lightner

Figure 180 In situ hybridisation of skeletal muscle tissue using a digoxigenin-labelled IMNV probe



Note: Black precipitate is present in areas where probe has hybridised with target virus. Bismarck brown counterstain. Scale bar = 50µm.

Source: DV Lightner

Further reading

CABI Invasive Species Compendium [Infectious myonecrosis](#)

CEFAS International Database on Aquatic Animal Diseases [Infectious myonecrosis](#)

World Organisation for Animal Health [Manual of diagnostic tests for aquatic animals](#)

Infection with *Macrobrachium rosenbergii* nodavirus (MrNV)

Also known as white tail disease and white muscle disease

Figure 181 White tail disease in giant freshwater prawn (*Macrobrachium rosenbergii*) postlarvae infected with MrNV



Note: Compare opaque musculature of affected prawns with the more transparent healthy prawns.

Source: AS Sahul Hameed

Signs of disease

Important: Animals with this disease may show one or more of these signs, but the pathogen may still be present in the absence of any signs.

Disease signs at the farm, tank or pond level are:

- whitish postlarvae
- lethargy
- mortality occurring 2 to 3 days after infection of the first postlarva in larval rearing tanks
- mortality of up to 95% within 5 days after the appearance of the first gross signs.

Gross pathological signs are:

- particularly milky and opaque abdomen (tail), starting at the tail extremity (telson region) and gradually progressing towards the head
- appearance in the tanks of abnormal floating moults that resemble mica flakes
- degeneration of telson and uropods (in severe cases)
- white colouration of abdominal muscle.

Microscopic pathological signs are:

- acute Zenker's necrosis of striated muscles, characterised by severe hyaline degeneration, necrosis and muscular lysis
- pathognomonic basophilic intracytoplasmic inclusion bodies in infected muscle tissues.

Disease agent

Also known as white tail disease or white muscle disease, this disease is caused by infection with *Macrobrachium rosenbergii* nodavirus (MrNV) and extra small virus (XSV). MrNV is a member of the family *Nodaviridae*. MrNV and XSV are both associated with the disease, but their respective roles are uncertain. These viruses are known to occur in fresh and brackish water.

Host range

MrNV causes disease mainly in giant freshwater prawns (*Macrobrachium rosenbergii*). However, several species of penaeids and red claw crayfish may be asymptomatic carriers of the virus, and *Artemia* and various species of aquatic insects are known vectors that can carry MrNV.

Table 57 Species known to be susceptible to infection with MrNV

Common name	Scientific name
Black tiger prawn	<i>Penaeus monodon</i>
Giant freshwater prawn ^a	<i>Macrobrachium rosenbergii</i>
Indian banana prawn	<i>Penaeus (Fenneropenaeus) indicus</i>
Kuruma prawn	<i>Penaeus (Marsupenaeus) japonicus</i>
Pacific white shrimp	<i>Penaeus (Litopenaeus) vannamei</i>
Penaeids	Various genera and species
Red claw crayfish	<i>Cherax quadricarinatus</i>

^a Naturally susceptible. Note: Other species are known carriers or potential carriers of the virus.

Table 58 Non-decapod crustacean carriers

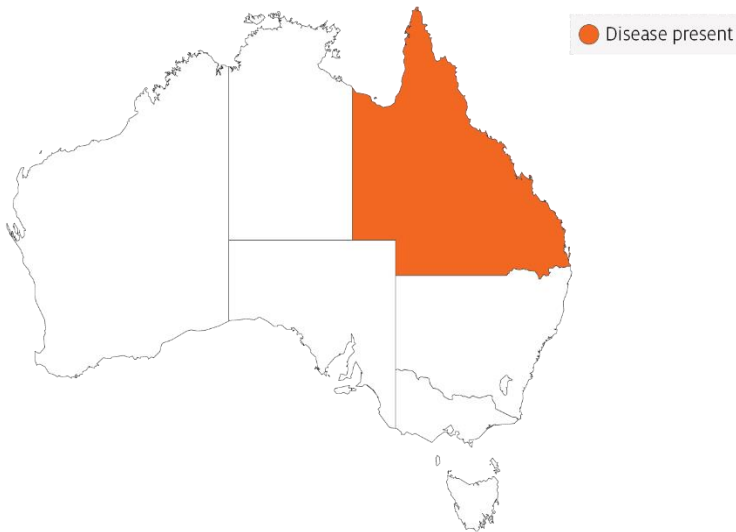Common name	Scientific name
Aquatic insects ^a	Various genera and species
Brine shrimp	<i>Artemia salina</i>

^a Naturally susceptible. Note: Other species have been shown to be experimentally susceptible.

Presence in Australia

White tail disease has been officially reported in giant freshwater prawns in north Queensland.

Map 41 Presence of MrNV, by jurisdiction



Epidemiology

- Very few postlarvae showing the clinical signs of white tail disease survive. Those that survive seem to grow normally in grow-out ponds.
- Outbreaks most commonly occur in larvae, postlarvae and early juveniles. Adult life stages are resistant and act as carriers.
- Transmission is both vertical (direct passage from parents to offspring via eggs) and horizontal (from virus present in the water surrounding susceptible prawns or direct contact with an infected prawn).
- Mortality rates are variable and reach up to 95%.
- Some penaeid shrimp, crayfish, *Artemia* and aquatic insects are vectors of white tail disease.

Differential diagnosis

The list of [similar diseases](#) in the next section refers only to the diseases covered by this field guide. Gross pathological signs may also be representative of diseases not included in this guide. Do not rely on gross signs to provide a definitive diagnosis. Use them as a tool to help identify the listed diseases that most closely account for the observed signs.

The clinical signs described and shown here may also be symptomatic of other bacterial or viral infections, or poor water quality. Further laboratory examination is needed for a definitive diagnosis.

Similar diseases

Infection with infectious myonecrosis virus (IMNV) and infection with shrimp haemocyte iridescent virus (SHIV).

Sample collection

Only trained personnel should collect samples. Using only gross pathological signs to differentiate between diseases is not reliable, and some aquatic animal disease agents pose a risk to humans. If you are not appropriately trained, phone your state or territory hotline number and report your observations. If you have to collect samples, the agency taking your call will advise you on the appropriate course of action. Local or district fisheries or veterinary authorities may also advise on sampling.

Emergency disease hotline

See something you think is this disease? Report it. Even if you're not sure.

Call the Emergency Animal Disease Watch Hotline on **1800 675 888**. They will refer you to the right state or territory agency.

Further reading

CABI Invasive Species Compendium [White tail disease](#)

CEFAS International Database on Aquatic Animal Diseases [White tail disease](#)

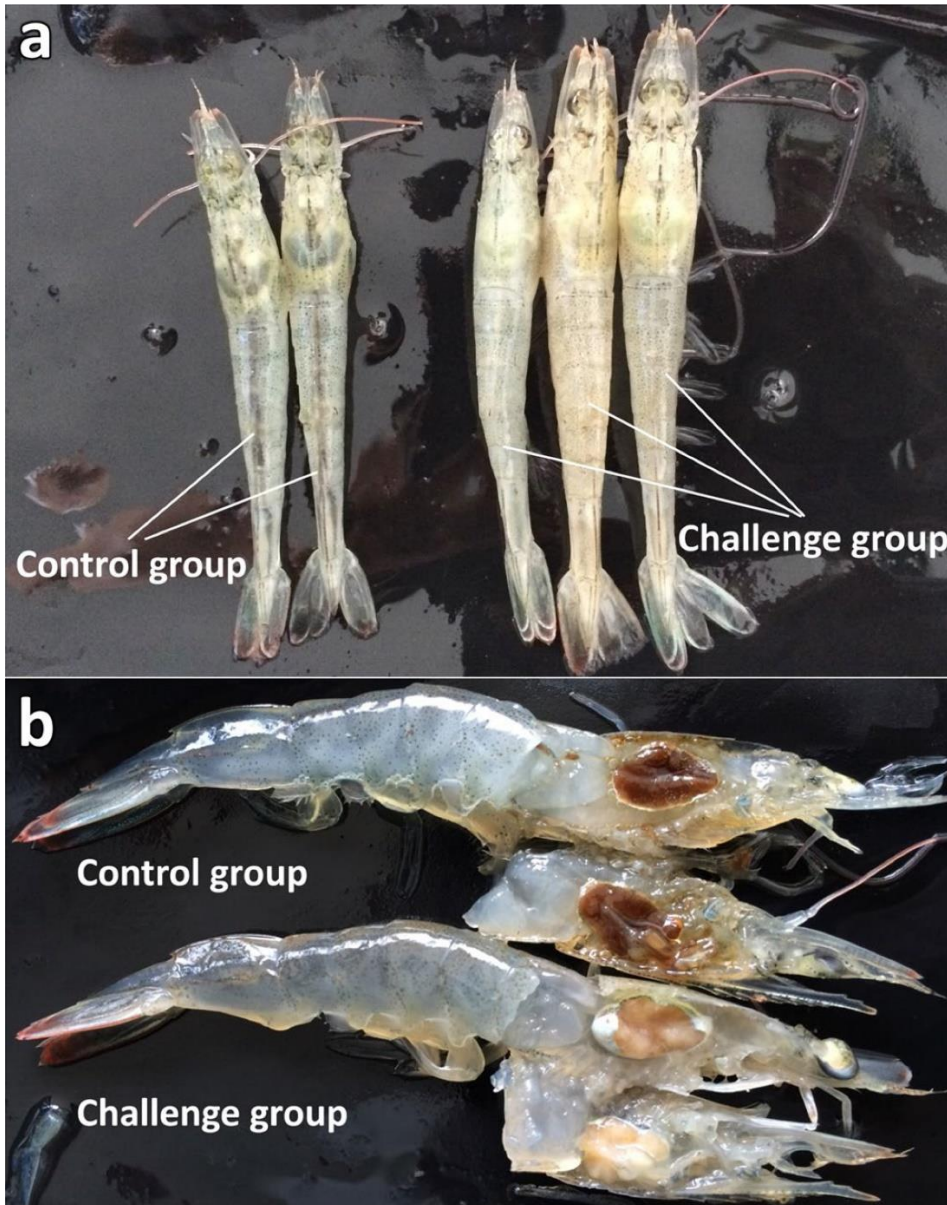
World Organisation for Animal Health [Manual of diagnostic tests for aquatic animals](#)

Infection with shrimp haemocyte iridescent virus (SHIV)

Also known as white head disease (WHD), Decapod iridescent virus 1 (DIV1) and *Cherax quadricarinatus* iridovirus (CQIV)

Exotic disease

Figure 182 Gross signs of Pacific white shrimp (*Penaeus (Litopenaeus) vannamei*) infected with SHIV



Note: When compared with healthy shrimp (control group), shrimp infected with SHIV (challenge group) have a whitish to yellowish head (a) caused by the pale necrotic hepatopancreas (b) and a slightly iridescent appearance of the carapace.
Source: Qiu et al. 2017

Signs of disease

Important: Animals with this disease may show one or more of these signs, but the pathogen may still be present in the absence of any signs.

Disease signs at the farm, tank or pond level are:

- lethargy
- cessation of feeding
- diseased shrimp sinking to the bottom of the pond
- sudden onset of high mortalities in late-postlarvae, juvenile or subadult prawns.

Gross pathological signs are:

- empty stomach and gut
- soft shell
- damaged antennae
- whitish to yellowish coloured head caused by a pale atrophied hepatopancreas
- white triangle under the carapace at the base of the rostrum in *Macrobrachium rosenbergii*
- slightly reddish body colour in approximately one third of affected shrimp.

Microscopic pathological signs are:

- many necrotic cells with pyknotic nuclei in the haematopoietic tissue and circulating haemocytes in the gills, hepatopancreas and haemolymph sinuses
- dark eosinophilic inclusions and pyknosis in haematopoietic tissue
- basophilic intracytoplasmic inclusions in haemocytes and other affected cells
- TEM shows many icosahedral non-enveloped virions in arrays within the cytoplasm of haemocytes found in the haemal sinuses, haematopoietic tissue, hepatopancreas and muscle.

Disease agent

SHIV, also known as Decapod iridescent virus 1 (DIV1), is an iridescent virus with a double stranded DNA genome, classified within the proposed genus *Decapodiridovirus* within the family *Iridoviridae*. SHIV emerged in China around 2014, causing high mortalities and significant economic losses in cultured *Penaeus (Litopenaeus) vannamei* and *Macrobrachium rosenbergii*. Genome sequencing has revealed that SHIV and *Cherax quadricarinatus* iridovirus (CQIV), identified from freshwater red claw crayfish *Cherax quadricarinatus*, are likely to be different strains of the same virus species.

Host range

Table 59 Species known to be susceptible to SHIV

Common name	Scientific name
Pacific white shrimp	<i>Penaeus (Litopenaeus) vannamei</i>

Table 60 Non-penaeids known to be susceptible to SHIV

Common name	Scientific name
Giant freshwater prawn ^a	<i>Macrobrachium rosenbergii</i>
Louisiana swamp crayfish ^a	<i>Procambarus clarkii</i>
Oriental freshwater shrimp ^a	<i>Macrobrachium nipponense</i>
Oriental prawn	<i>Exopalaemon carinicauda</i>
Redclaw crayfish ^a	<i>Cherax quadricarinatus</i>

^a Naturally susceptible.

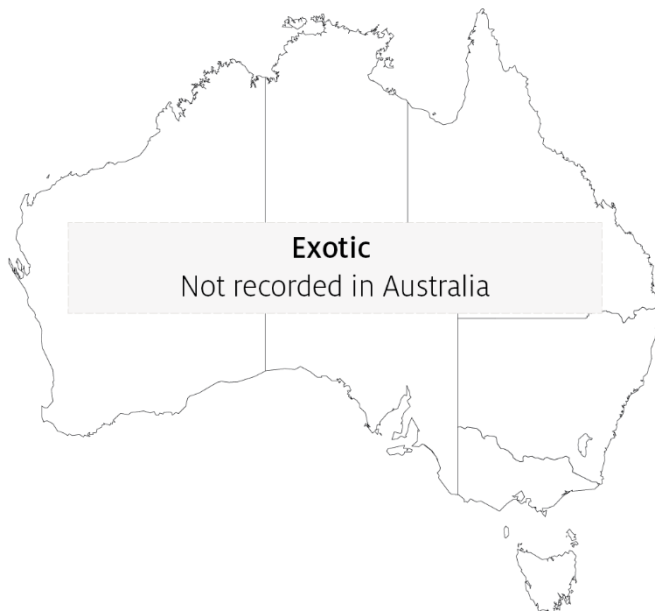Table 61 Potential carriers of SHIV

Common name	Scientific name
Chinese white shrimp	<i>Penaeus (Fenneropenaeus) chinensis</i>
Superb freshwater shrimp	<i>Macrobrachium superbum</i>
Cladocerans (water fleas)	Order Cladocera

Presence in Australia

Exotic disease—not recorded in Australia.

Map 42 Presence of SHIV, by jurisdiction



Epidemiology

- Infection with SHIV has been responsible for high mortalities (over 80%) in farmed *P. vannamei* and *M. rosenbergii* populations in China since 2014.
- Infection is horizontal via cannibalism of infected shrimp or through contact with infected faeces. Per os and reverse gavage infection experiments in *P. vannamei* resulted in 100% cumulative mortality within 2 weeks.
- Injection challenges exposing *P. vannamei*, *C. quadricarinatus*, and *Procambarus clarkii* to SHIV also resulted in 100% cumulative mortalities.
- Infected *M. rosenbergii* exhibit distinctive clinical signs called white head disease, characterised by a distinct white triangle area under the carapace at the base of the rostrum. This effect is a result of the pale colouration of diseased haematopoietic tissue.
- The virus is found mainly in haematopoietic tissue located above the stomach and at the base of antennae, pereopods and other appendages. However, SHIV infection is systemic and the virus is also found in the haemocytes, gills, hepatopancreas, pereopods, and muscle.
- qPCR tests show that the highest levels of virus in infected crustaceans are found in the haematopoietic tissue and haemocytes. The lowest viral levels are in the muscle.

Differential diagnosis

The list of [similar diseases](#) in the next section refers only to the diseases covered by this field guide. Gross pathological signs may also be representative of diseases not included in this guide. Do not rely on gross signs to provide a definitive diagnosis. Use them as a tool to help identify the listed diseases that most closely account for the observed signs.

Similar diseases

Acute hepatopancreatic necrosis disease (AHPND), gill associated virus disease (GAV), infection with infectious myonecrosis virus (MrNV), infection with *Macrobrachium rosenbergii* nodavirus, infection with white spot syndrome virus (WSSV) and infection with yellowhead virus genotype 1 (YHV1).

Sample collection

Perinuclear pale basophilic to dark basophilic inclusion bodies are evident in this group of muscle cells (arrows point at some examples).

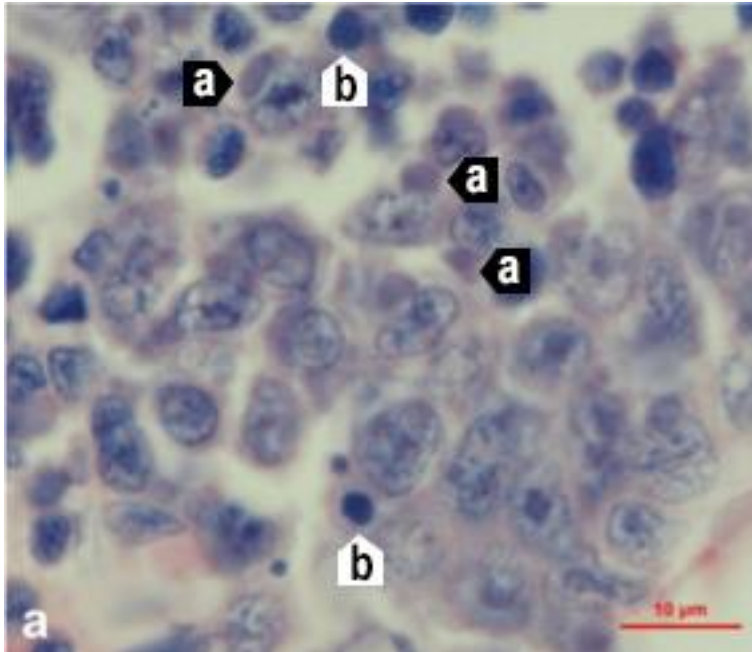
Emergency disease hotline

See something you think is this disease? Report it. Even if you're not sure.

Call the Emergency Animal Disease Watch Hotline on **1800 675 888**. They will refer you to the right state or territory agency.

Microscope images

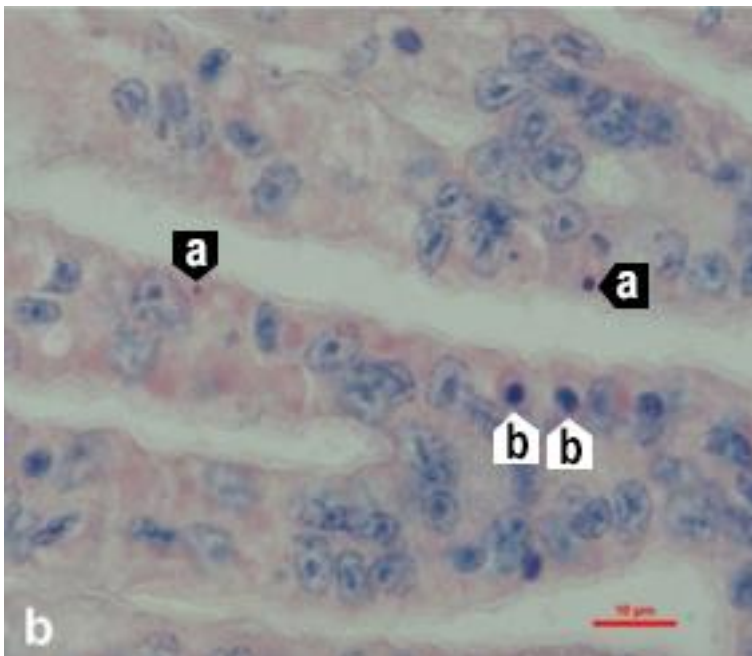
Figure 183 Haematopoietic tissue of Pacific white shrimp (*Penaeus (Litopenaeus) vannamei*) infected with SHIV



Note: Haemocytes and hepatopancreas cells with dark basophilic cytoplasmic inclusions (a) and numerous necrotic cells with pyknotic nuclei (b). Histological section with haematoxylin and eosin stain. Scale bar = 10 µm.

Source: Qiu et al. 2017

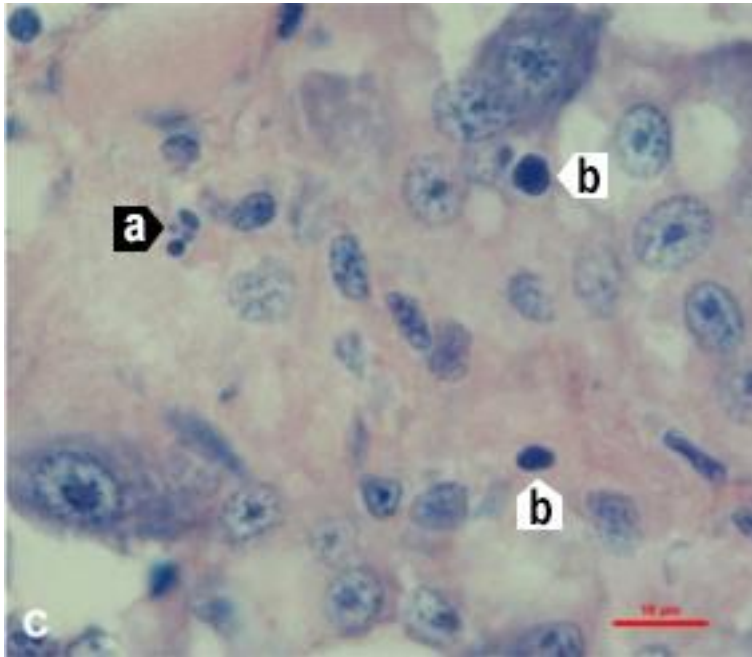
Figure 184 Gills of Pacific white shrimp (*Penaeus (Litopenaeus) vannamei*) infected with SHIV



Note: Haemocytes and hepatopancreas cells with dark basophilic cytoplasmic inclusions (a) and numerous necrotic cells with pyknotic nuclei (b). Histological section with haematoxylin and eosin stain. Scale bar = 10 µm.

Source: Qiu et al. 2017

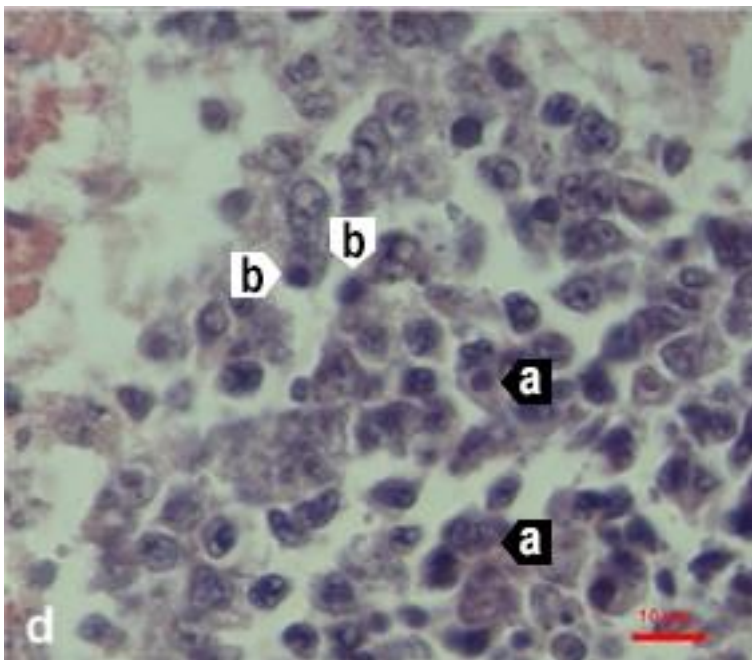
Figure 185 Hepatopancreas of Pacific white shrimp (*Penaeus (Litopenaeus) vannamei*) infected with SHIV



Note: Haemocytes and hepatopancreas cells with dark basophilic cytoplasmic inclusions (a) and numerous necrotic cells with pyknotic nuclei (b). Histological section with haematoxylin and eosin stain. Scale bar = 10 µm.

Source: Qiu et al. 2017

Figure 186 Periopods of Pacific white shrimp (*Penaeus (Litopenaeus) vannamei*) infected with SHIV



Note: Haemocytes and hepatopancreas cells with dark basophilic cytoplasmic inclusions (a) and numerous necrotic cells with pyknotic nuclei (b). Histological section with haematoxylin and eosin stain. Scale bar = 10 µm.

Source: Qiu et al. 2017

Further reading

Qiu L, Chen MM, Wan XY, Li C, Zhang QL, Wang RY, Cheng DY, Dong X, Yang B, Wang XH, Xiang JH, and Huang J 2017, 'Characterization of a new member of *Iridoviridae*, Shrimp haemocyte iridescent virus (SHIV), found in white leg shrimp (*Litopenaeus vannamei*)', *Scientific Reports*.

Qiu L, Chen X, Zhao RH, Li C, Gao W, Zhang QL, Huang J 2019, 'Description of a natural infection with Decapod iridescent virus 1 in farmed giant freshwater prawn, *Macrobrachium rosenbergii*', *Viruses*.

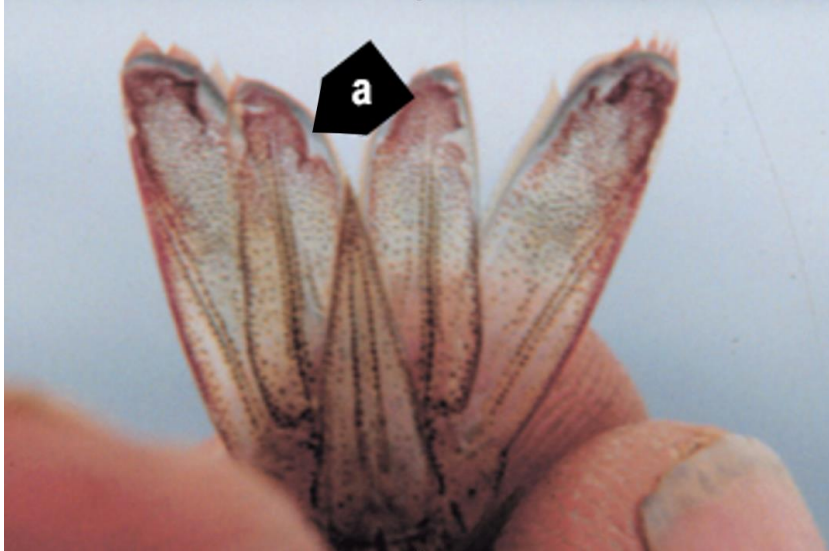
Xu L, Wang T, Li F, Yang F 2016, 'Isolation and preliminary characterization of a new pathogenic iridovirus from redclaw crayfish *Cherax quadricarinatus*', *Diseases of Aquatic Organisms*.

Infection with Taura syndrome virus (TSV)

Also known as Taura syndrome and red tail disease

Exotic disease

Figure 187 Acute Taura syndrome in Pacific white shrimp (*Penaeus (Litopenaeus) vannamei*)



Note: Distinctive red tail fan. Rough edges around cuticular epithelium in the uropods (tail fin) are common signs of infection and suggest focal necrosis of the epithelium at those sites (a).

Source: DV Lightner

Figure 188 Taura syndrome in surviving Pacific white shrimp (*Penaeus (Litopenaeus) vannamei*)



Note: Dark melanic lesions on carapace from a transitional phase infection.

Source: DV Lightner

Figure 189 Moribund, juvenile pond-reared Pacific white shrimp (*Penaeus (Litopenaeus) vannamei*) in peracute phase of Taura syndrome



Note: Infected shrimp are lethargic and have soft shells and distinctive red tail fans.
Source: DV Lightner

Figure 190 Juvenile pond-reared Pacific white shrimp (*Penaeus (Litopenaeus) vannamei*) in chronic or recovery phase of Taura syndrome



Note: Multiple melanised (dark) foci mark sites of resolving cuticular epithelium necrosis caused by TSV infection.
Source: DV Lightner

Signs of disease

Important: Animals with this disease may show one or more of these signs, but the pathogen may still be present in the absence of any signs.

Disease signs at the farm, tank or pond level are:

- lethargy
- cessation of feeding
- animals gathering at the pond edge when moribund
- sudden increase in presence of seabirds fishing in ponds
- sudden onset of high mortalities in late-postlarvae, juvenile or subadult prawns.

Gross pathological signs are:

- acute phase
 - empty stomach and pale red body surface and appendages
 - red tail fan and pleopods due to the expansion of red chromatophores
 - soft shell
- transition phase
 - multiple, irregularly shaped and randomly distributed melanised (dark) cuticular lesions
 - death, usually at moulting.

There are no obvious gross pathological signs of disease in the chronic phase.

Microscopic pathological signs are:

- necrosis of the cuticular epithelium of appendages
- multifocal lesions in the cuticular epithelium (transition phase)
- abundant pyknotic and karyorrhectic nuclei that give Taura syndrome lesions a pathodiagnostic peppered or buckshot-riddled appearance.

Disease agent

Taura syndrome is caused by infection with Taura syndrome virus (TSV), a small picorna-like RNA virus that belongs to the genus *Aparavirus* in the family *Dicistroviridae*.

Host range

A wide range of penaeid prawns (Table 62) and non-penaeid carriers (Table 63) are known to be susceptible to this virus.

Table 62 Species known to be susceptible to TSV

Common name	Scientific name
Black tiger prawn ^a	<i>Penaeus monodon</i>
Chinese white shrimp	<i>Penaeus (Fenneropenaeus) chinensis</i>
Gulf banana prawn	<i>Penaeus (Fenneropenaeus) merguensis</i>
Indian banana prawn	<i>Penaeus (Fenneropenaeus) indicus</i>
Kuruma prawn	<i>Penaeus (Marsupenaeus) japonicus</i>
Northern brown shrimp	<i>Penaeus (Farfantepenaeus) aztecus</i>
Northern pink shrimp	<i>Penaeus (Farfantepenaeus) duorarum</i>
Northern white shrimp ^a	<i>Penaeus (Litopenaeus) setiferus</i>
Pacific blue shrimp ^a	<i>Penaeus (Litopenaeus) stylirostris</i>
Pacific white shrimp ^a	<i>Penaeus (Litopenaeus) vannamei</i>
Red endeavour (greasyback) prawn ^a	<i>Metapenaeus ensis</i>
Southern white shrimp ^a	<i>Penaeus (Litopenaeus) schmitti</i>

^a Naturally susceptible. Note: Other species have been shown to be experimentally susceptible.

Table 63 Non-penaeid carriers

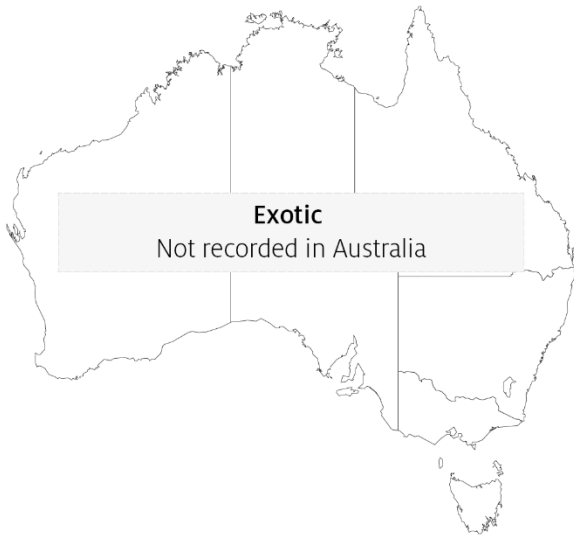Common name	Scientific name
Acorn and gooseneck barnacles ^a	<i>Chelonibia</i> spp., <i>Octolasmis</i> spp.
Fiddler crab	<i>Uca vocans</i>
Freshwater prawn	<i>Macrobrachium lanchesteri</i>
Giant freshwater prawn	<i>Macrobrachium rosenbergii</i>
Mud crab ^a	<i>Scylla serrata</i>
Mysid shrimp	<i>Palaemon styliferus</i>
Parasitic copepods	<i>Ergasilus manicatus</i>
Piscivorous birds	Various genera and species
Red crab	<i>Sesarma mederi</i>

^a Naturally susceptible. Note: Other species have been shown to be experimentally susceptible.

Presence in Australia

Exotic disease—not recorded in Australia.

Map 43 Presence of TSV, by jurisdiction



Epidemiology

- Taura syndrome is a disease mainly of the nursery phase of *Penaeus (Litopenaeus) vannamei*. It usually occurs within 14 to 40 days of stocking postlarvae into grow-out ponds or tanks and results in mortality rates of 40% to more than 90%.
- TSV has been documented in postlarvae, juvenile and adult life stages.
- Survivors of infection with TSV may become lifelong carriers.
- Transmission is horizontal through ingestion. Vertical transmission is suspected, but it has not been experimentally confirmed.
- Migratory birds, aquatic insects and humans are likely mechanical vectors of the virus. Birds may be an important route of transmission. TSV has been demonstrated to remain infectious for up to 48 hours in the faeces of sea gulls that have ingested infected prawn carcasses.
- Resistance of *Penaeus monodon* and *Penaeus (Marsupenaeus) japonicus* to TSV is unclear, but they appear to be more resistant than *P. vannamei*.
- TSV-resistant stocks of *P. vannamei* and *Penaeus (Litopenaeus) stylirostris* are commercially available. TSV-resistant stocks have shown survival rates of up to 100% following laboratory challenge.

Differential diagnosis

The list of [similar diseases](#) in the next section refers only to the diseases covered by this field guide. Gross pathological signs may also be representative of diseases not included in this guide. Do not rely on gross signs to provide a definitive diagnosis. Use them as a tool to help identify the listed diseases that most closely account for the observed signs.

Similar diseases

Infection with white spot syndrome virus (WSSV) and infection with yellowhead virus genotype 1 (YHV1).

Sample collection

Only trained personnel should collect samples. Using only gross pathological signs to differentiate between diseases is not reliable, and some aquatic animal disease agents pose a risk to humans. If you are not appropriately trained, phone your state or territory hotline number and report your observations. If you have to collect samples, the agency taking your call will advise you on the appropriate course of action. Local or district fisheries or veterinary authorities may also advise on sampling.

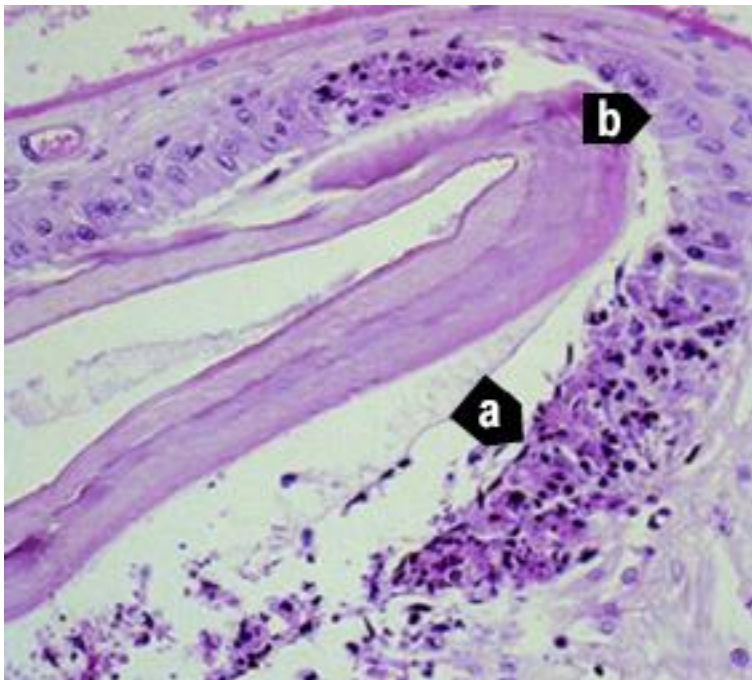
Emergency disease hotline

See something you think is this disease? Report it. Even if you're not sure.

Call the Emergency Animal Disease Watch Hotline on **1800 675 888**. They will refer you to the right state or territory agency.

Microscope images

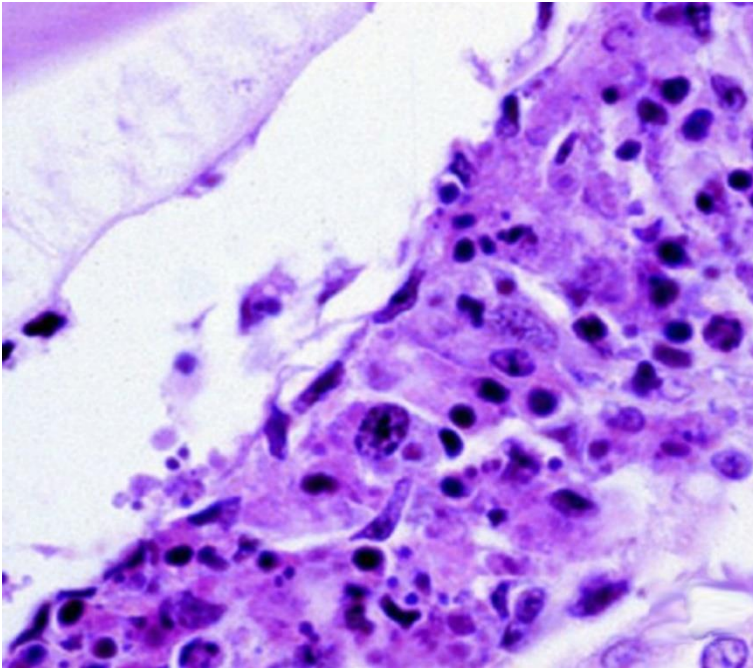
Figure 191 Histological section through stomach of juvenile Pacific white shrimp (*Penaeus (Litopenaeus) vannamei*) with peracute Taura syndrome



Note: Prominent areas of necrosis in cuticular epithelium (a), which secretes the overlying acellular cuticle. Adjacent to the focal lesions are normal-looking epithelial cells (b). 300x magnification.

Source: DV Lightner

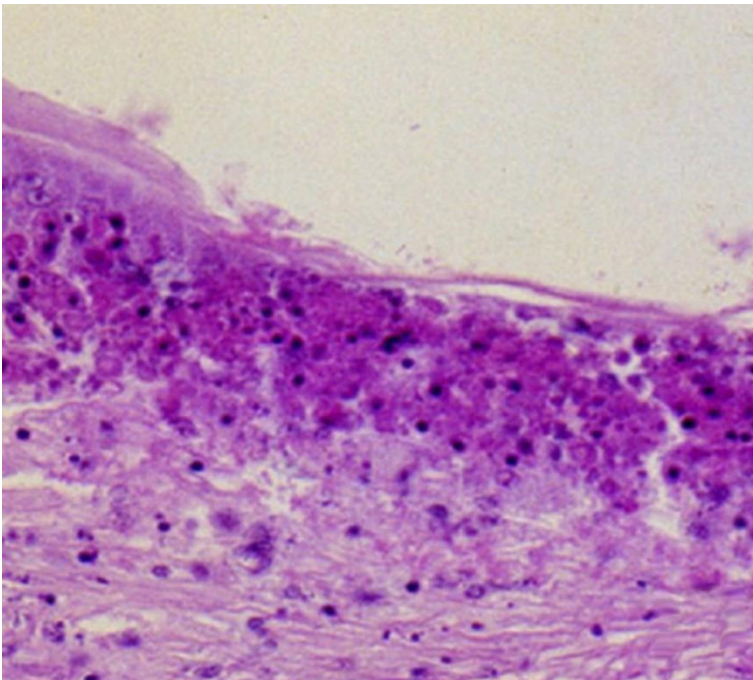
Figure 192 Characteristic lesion in peracute phase of Taura syndrome



Note: Higher magnification of Figure 191, bottom right (a). Classic Taura syndrome lesions consist of necrotic cuticular epithelial and subcuticular connective tissue cells with pyknotic and karyorrhectic nuclei; a generally increased cytoplasmic eosinophilia; and very numerous, variably staining cytoplasmic inclusions. Cytoplasmic inclusions and pyknotic and karyorrhectic nuclei give the lesion a pathodiagnostic peppered or buckshot-riddled appearance. Absence of haemocytes in or near the lesion suggest lesion is peracute. 900x magnification.

Source: DV Lightner

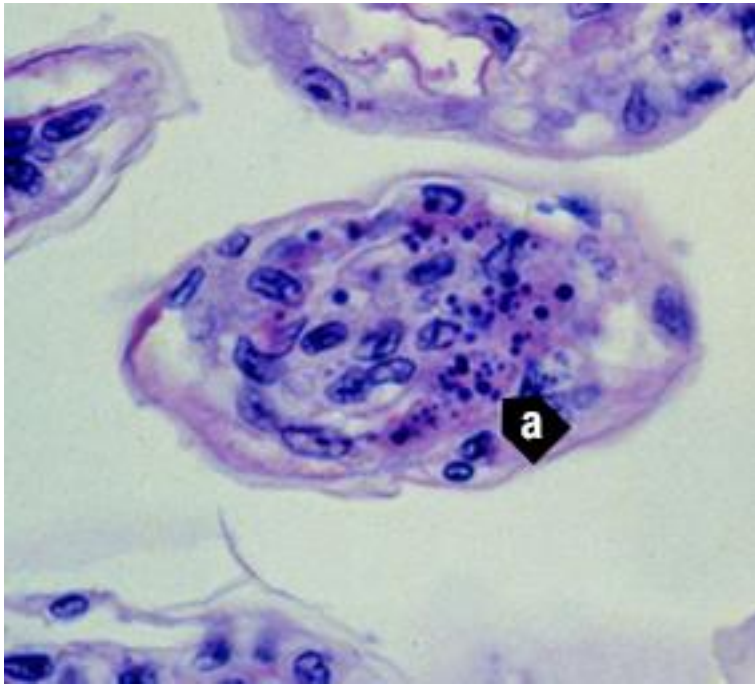
Figure 193 Pathognomonic focal Taura syndrome virus lesions in cuticular epithelium and subcutis of carapace of juvenile Pacific white shrimp (*Penaeus (Litopenaeus) vannamei*) with peracute Taura syndrome



Note: Large numbers of pyknotic and karyorrhectic nuclei. 450x magnification.

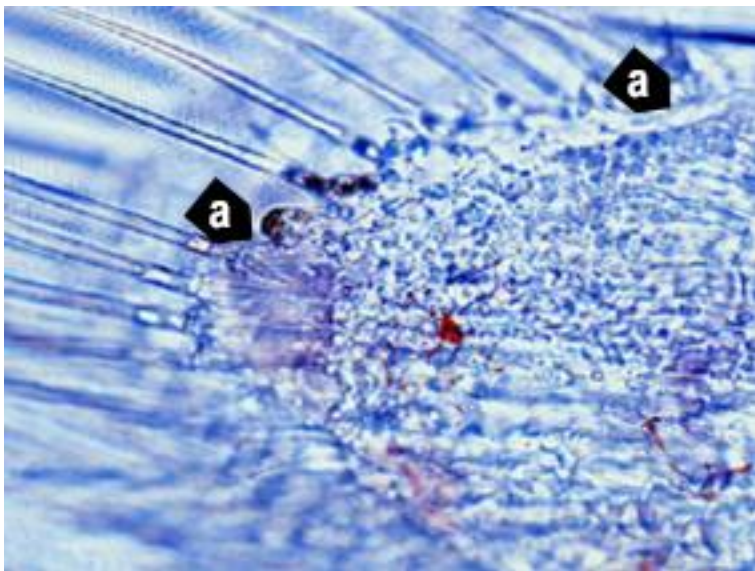
Source: DV Lightner

Figure 194 Pathognomonic focal Taura syndrome virus lesions in gills of juvenile Pacific white shrimp (*Penaeus (Litopenaeus) vannamei*)



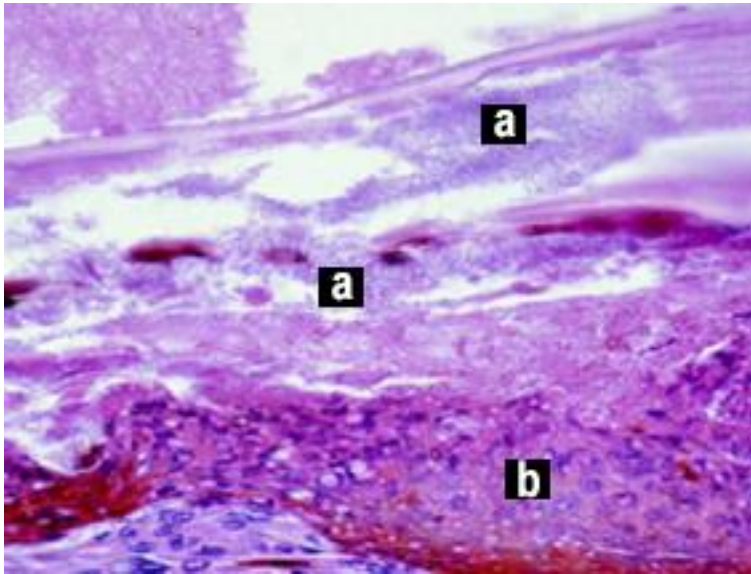
Note: Distinguishing characteristics of the lesions include nuclear pyknosis and karyorrhexis, increased cytoplasmic eosinophilia, and an abundance of variably staining and generally spherical cytoplasmic inclusions (a). 900x magnification. Source: DV Lightner

Figure 195 Unstained wet mount of uropod of experimentally infected postlarval Pacific white shrimp (*Penaeus (Litopenaeus) vannamei*) with peracute Taura syndrome



Note: Postlarva in the D4 stage of moult cycle, shown by the old cuticle separated from the new cuticle by a space. Approximate margins (a) of a focal area of necrosis in the cuticular epithelium. Area of necrosis is evidenced by vacant zone under the cuticular epithelium (where cuticular epithelium should be) and by refractile spheres (pyknotic and karyorrhectic nuclei) near periphery of lesion. Expanded red chromatophores are apparent in the subcuticular connective tissues of the uropod. 300x magnification. Source: DV Lightner

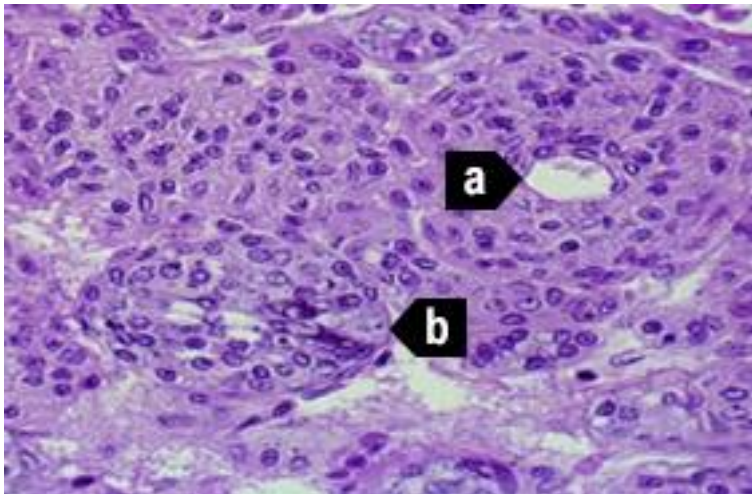
Figure 196 Histological section of resolving cuticular lesion in juvenile Pacific white shrimp (*Penaeus (Litopenaeus) vannamei*)



Note: Perforated cuticle is heavily colonised with masses of bacteria (a). Thick, melanised, haemocytic 'plug' (b) has formed basal to the cuticular epithelium to temporarily close wound from the outside. Basal to haemocyte plug (b), connective tissue elements and additional infiltrating haemocytes provide basal support for regeneration of cuticular epithelium. Pathognomonic Taura syndrome lesions in recovery or chronic phase of Taura syndrome are usually few, relative to the resolving lesions shown here, and are often entirely absent. 600x magnification.

Source: DV Lightner

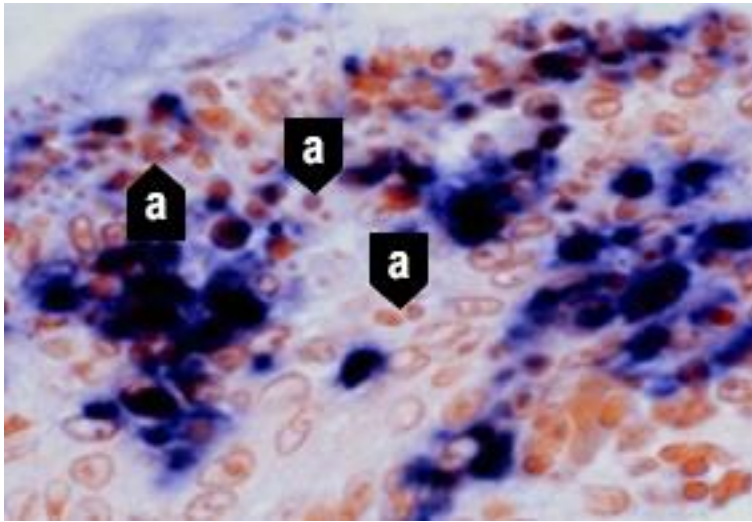
Figure 197 Midsagittal section of lymphoid organ of experimentally infected juvenile Pacific white shrimp (*Penaeus (Litopenaeus) vannamei*) in chronic or recovery phase of Taura syndrome



Note: TSV induces some significant lesions in the lymphoid organ (LO), but never pathognomonic Taura syndrome lesions of the type seen in the cuticular epithelium. Normal-looking LO cords or tissue is characterised by multiple layers of sheath cells around a central haemolymph vessel (a). Interspersed are accumulations of disorganised LO cells that form LO 'spheroids' (LOS). LOS lack a central vessel and consist of cells that show karyomegaly and large, prominent cytoplasmic vacuoles and other cytoplasmic inclusions (b). 450x magnification.

Source: DV Lightner

Figure 198 In situ hybridisation of appendage from postlarval Pacific white shrimp (*Penaeus (Litopenaeus) vannamei*) with peracute Taura syndrome



Note: Digoxigenin-labelled cDNA probe reacts with TSV-infected cells, staining cytoplasm of infected cuticular epithelial cells and subcuticular connective tissue. Probe does not react with pyknotic and karyorrhectic nuclei (a) because TSV is only cytoplasmic. These nuclear remnants contribute to 'peppered' or 'buckshot-riddled' appearance of TSV lesions. 900x magnification.

Source: DV Lightner

Further reading

CABI Invasive Species Compendium [Taura syndrome](#)

CEFAS International Database on Aquatic Animal Diseases [Taura syndrome](#)

World Organisation for Animal Health [Manual of diagnostic tests for aquatic animals](#)

Infection with white spot syndrome virus (WSSV)

Also known as white spot disease (WSD)

Exotic disease—restrictions apply

Figure 199 WSD in giant black tiger prawn (*Penaeus monodon*)



Note: White spots on carapace are typical of infection following acute phase of infection.

Source: B Diggles

Figure 200 WSD in giant black tiger prawn (*Penaeus monodon*)



Note: Carapace is loose and when removed, large smooth-edged white spots are evident. Numerous smaller white spots are also evident on the abdominal segments.

Source: B Diggles

Figure 201 Five juvenile black tiger prawns (*Penaeus monodon*) infected with WSSV lacking classical white spots



Note: Prawns exhibit few, if any, white spots. Prawns infected with WSSV can present as 'normal' prawns.

Source: B Diggles

Signs of disease

Important: Animals with this disease may show one or more of these signs, but the pathogen may still be present in the absence of any signs.

Disease signs at the farm, tank or pond level are:

- rapid onset of mass mortality (80% or more) in farmed penaeid prawns during the grow-out period
- lethargy
- cessation of feeding
- aggregations of moribund prawns near the water surface at the edge of the rearing pond or tank.

Gross pathological signs are:

- loose carapace
- high degree of colour variation, with a predominance of darkened (red, brown or pink) body surface and appendages
- heavy fouling of the surface and gills by external parasites
- white midgut line through the abdomen of severely affected larvae and postlarvae
- delayed (or completely absent) clotting reaction of the haemolymph of infected shrimp
- white calcium deposits embedded in the shell, causing white spots 0.5 to 3.0mm in diameter.

Prawns with WSD may not show distinctive clinical signs. If present, shell lesions can range from minute spots to discs several millimetres in diameter, and may coalesce into larger white plates. Spots are most easily observed by removing the cuticle over the cephalothorax, scraping away any

attached tissue with the thumbnail and holding the cuticle up to the light. However, white spots in the cuticle are unreliable for even preliminary diagnosis of WSD. Similar spots can be produced by some bacteria, high alkalinity and other infectious agents or environmental conditions.

Microscopic pathological signs are:

- hypertrophied nuclei in gills and/or cuticular epithelium
- viral aggregates (shown as small reflective spots) in unstained smear preparations of the haemolymph by dark-field microscopy
- pathognomonic inclusion bodies in histological sections in target tissues.

Disease agent

WSD is caused by infection with white spot syndrome virus (WSSV), a large DNA virus assigned as the only member of the genus *Whispovirus* (family *Nimaviridae*). The virus only infects crustaceans and appears not to be related to any other known viruses. It is not related to white spot disease of finfish, which is caused by parasitic ciliate protozoans. WSSV is known to occur in fresh, brackish and marine water.

Host range

All decapod crustaceans (order Decapoda) are considered susceptible to infection, including prawns, lobsters and crabs from marine, brackish or freshwater environments (Table 64). The disease has mainly been a problem in farmed penaeid (family *Penaeidae*) prawns.

Carriers of the virus (Table 65) include rotifers, marine molluscs, polychaete worms and non-decapod crustaceans such as *Artemia salina*, copepods, non-crustacean arthropods and aquatic insect larvae. Birds can also spread the virus.

Table 64 Species known to be susceptible to infection with WSSV

Common name	Scientific name
All decapod crustaceans	Decapoda—all species
Aloha prawn	<i>Penaeus marginatus</i>
American lobster	<i>Homarus americanus</i>
Argentine stiletto shrimp	<i>Artemesia longinaris</i>
Asian freshwater shrimp ^a	<i>Macrobrachium dayanum</i>
Barred estuarine shrimp ^a	<i>Palaemon serrifer</i>
Black tiger prawn ^a	<i>Penaeus monodon</i>
Brown tiger prawn ^a	<i>Penaeus esculentus</i>
Brush clawed shore crab	<i>Hemigrapsus penicillatus</i>
Chinese mitten crab ^a	<i>Eriocheir sinensis</i>
Chinese white shrimp ^a	<i>Penaeus (Fenneropenaeus) chinensis</i>
Crayfish (native to Europe) ^a	<i>Astacus</i> spp.
Crayfish (native to North America) ^a	<i>Orconectes</i> spp.
Cuata swimcrab	<i>Callinectes arcuatus</i>
Daggerblade grass shrimp	<i>Palaemon pugio</i>
European river crab	<i>Potamon potamios</i>

Common name	Scientific name
European shore crab	<i>Carcinus maenas</i>
Fiddler crab	<i>Uca vocans</i>
Freshwater crayfish ^a	<i>Cherax</i> spp.
Freshwater prawn	<i>Macrobrachium lanchesteri</i>
Giant crayfish (native to Australia)	<i>Astacopsis</i> spp.
Giant freshwater prawn ^a	<i>Macrobrachium rosenbergii</i>
Giant Tasmanian crayfish	<i>Astacopsis gouldi</i>
Gippsland spiny crayfish	<i>Euastacus kershawi</i>
Green tiger prawn or grooved tiger prawn ^a	<i>Penaeus semisulcatus</i>
Greentail prawn ^a	<i>Metapenaeus bennettiae</i>
Gulf banana prawn ^a	<i>Penaeus (Fenneropenaeus) merguensis</i>
Indian banana prawn ^a	<i>Penaeus (Fenneropenaeus) indicus</i>
Japanese crayfish	<i>Cambaroides japonicus</i>
Jelly prawns ^a	<i>Acetes</i> spp.
Kuruma prawn ^a	<i>Penaeus (Marsupenaeus) japonicus</i>
Louisiana swamp crayfish ^a	<i>Procambarus clarkii</i>
Mangrove swimming crab ^a	<i>Thalamita crenata</i>
Marbled crayfish	<i>Procambarus fallax. f. virginalis</i>
Mississippi grass shrimp	<i>Palaemonetes kadiakensis</i>
Mud crab ^a	<i>Scylla serrata</i>
Mysid shrimp	<i>Palaemon styliferus</i>
Noble crayfish	<i>Astacus astacus</i>
Northern brown shrimp ^a	<i>Penaeus (Farfantepenaeus) aztecus</i>
Northern pink shrimp ^a	<i>Penaeus (Farfantepenaeus) duorarum</i>
Northern white shrimp ^a	<i>Penaeus (Litopenaeus) setiferus</i>
Oriental freshwater shrimp ^a	<i>Macrobrachium nipponense</i>
Oriental prawn	<i>Exopalaemon carinicauda</i>
Pacific blue shrimp ^a	<i>Penaeus (Litopenaeus) stylirostris</i>
Pacific white shrimp ^a	<i>Penaeus (Litopenaeus) vannamei</i>
Red claw crayfish ^a	<i>Cherax quadricarinatus</i>
Red crab	<i>Sesarma mederi</i>
Red endeavour (greasyback) prawn ^a	<i>Metapenaeus ensis</i>
Sand crab ^a	<i>Portunus pelagicus</i>
Signal crayfish	<i>Pacifastacus leniusculus</i>
Smooth crayfish	<i>Geocherax</i> spp.
Southern brown shrimp	<i>Penaeus (Farfantepenaeus) subtilis</i>
Southern white shrimp	<i>Penaeus (Litopenaeus) schmitti</i>
Spiny crayfish	<i>Euastacus</i> spp.

Common name	Scientific name
Stone crayfish	<i>Austropotamobius torrentium</i>
Sunda river prawn	<i>Macrobrachium sintangene</i>
Superb freshwater shrimp	<i>Macrobrachium superbum</i>
Three spot swimming crab ^a	<i>Portunus sanguinolentus</i>
Tropical spiny lobster	<i>Panulirus</i> spp.
Turkish crayfish	<i>Astacus leptodactylus</i>
Western white shrimp	<i>Penaeus (Litopenaeus) occidentalis</i>
White-clawed crayfish	<i>Austropotamobius pallipes</i>
Yellow-leg shrimp	<i>Penaeus (Farfantepenaeus) californiensis</i>
Yabbies (freshwater)	<i>Cherax destructor</i>

^a Naturally susceptible. Note: Other species are likely to be susceptible or shown to be experimentally susceptible.

Table 65 Non-decapod crustacean carriers

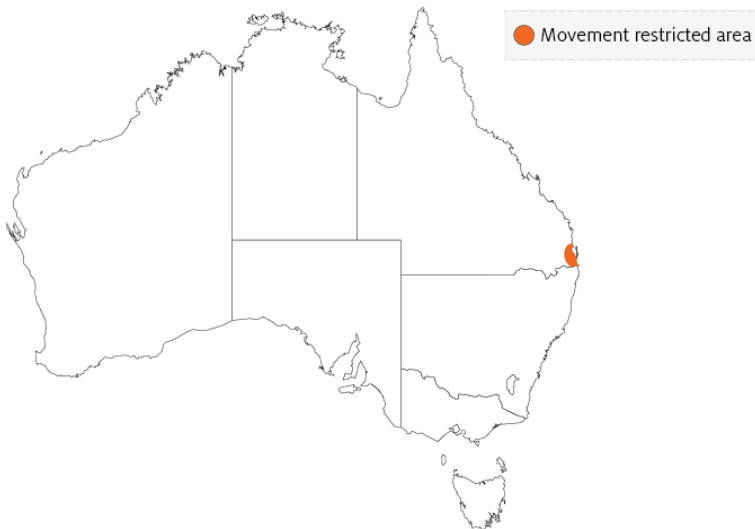Common name	Scientific name
Annelids	Various genera and species
Aquatic insects	Various genera and species
Brine shrimp	<i>Artemia salina</i>
Molluscs	Various genera and species
Parasitic copepods	<i>Ergasilus manicatus</i>
Piscivorous birds	Various genera and species
Planktonic copepods	<i>Paracartia grani</i>
Polychaetes	Various genera and species
Rotifers	Various genera and species

Presence in Australia

Exotic disease—under official control.

WSD was confirmed in South East Queensland in December 2016. An emergency response to contain and eradicate the disease is ongoing.

Map 44 Presence of WSSV, by jurisdiction



Epidemiology

- WSD is mainly a disease of farmed penaeid prawns, but many species of crustaceans are susceptible to infection with WSSV.
- Rapid mortalities of up to 80% or more within 3 to 10 days have been reported in many countries.
- Prawn farm productivity falls to about 40% of normal rate for 2 years, and then recovers to about 70% over the long term.
- Some of the species listed in the [host range](#) section (such as *Penaeus monodon*) are extremely susceptible to WSSV. Others may be infected but are more resistant to disease.
- Infection may be low level and chronic (lifelong carriers are possible) in healthy crustaceans, or acute infection with disease and mortalities.
- Viral multiplication and disease appears to be induced by environmental and handling stress. Stressors include eye-stalk ablation, spawning, moulting, high stocking densities, changes in salinity, temperature and pH, and plankton blooms. Imposing such stressors on suspect populations can be a useful diagnostic method for detecting the virus.
- All life stages are susceptible, from eggs to broodstock.
- Vertical transmission occurs from infected broodstock.
- Horizontal transmission of disease is usually via cannibalism of sick or dying prawns, or directly through contaminated water.
- Vectors of the virus include rotifers, marine molluscs, polychaete worms and non-decapod crustaceans including *Artemia salina*, copepods, non-crustacean arthropods and insect larvae.

- Birds can transmit the disease from pond to pond by releasing caught prawns over neighbouring ponds.
- White spot syndrome virus can persist and retain infectivity in seawater at 30°C for at least 30 days (under laboratory conditions) and for at least 4 days in ponds.

Differential diagnosis

The list of [similar diseases](#) in the next section refers only to the diseases covered by this field guide. Gross pathological signs may also be representative of diseases not included in this guide. Do not rely on gross signs to provide a definitive diagnosis. Use them as a tool to help identify the listed diseases that most closely account for the observed signs.

Similar diseases

Acute hepatopancreatic necrosis disease (AHPND), infection with *Hepatobacter penaei* (NHP), infection with infectious hypodermal and haematopoietic necrosis virus (IHHNV), infection with shrimp haemocyte iridescent virus (SHIV), infection with Taura syndrome virus (TSV) and infection with yellowhead virus genotype 1 (YHV1).

Sample collection

Only trained personnel should collect samples. Using only gross pathological signs to differentiate between diseases is not reliable, and some aquatic animal disease agents pose a risk to humans. If you are not appropriately trained, phone your state or territory hotline number and report your observations. If you have to collect samples, the agency taking your call will advise you on the appropriate course of action. Local or district fisheries or veterinary authorities may also advise on sampling.

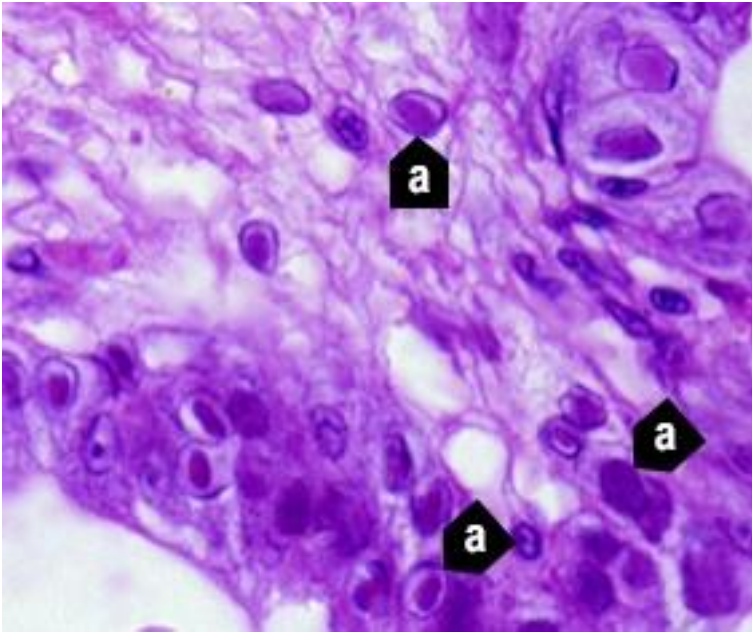
Emergency disease hotline

See something you think is this disease? Report it. Even if you're not sure.

Call the Emergency Animal Disease Watch Hotline on **1800 675 888**. They will refer you to the right state or territory agency.

Microscope images

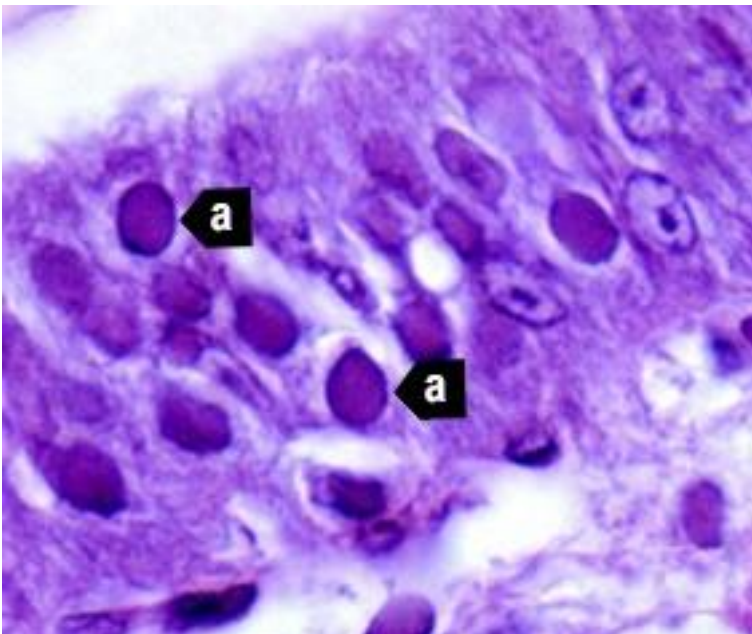
Figure 202 Photomicrograph of histological section from stomach of juvenile black tiger prawn (*Penaeus monodon*) with WSD



Note: Prominent intranuclear inclusion bodies are abundant in cuticular epithelium and subcuticular connective tissue of the organ (a). Cells in different phases of infection display intranuclear inclusion bodies. Early-phase inclusion bodies in this section are centronuclear and eosinophilic. These are separated from nuclear membrane and marginated chromatin by an artefactual halo. 900x magnification.

Source: DV Lightner

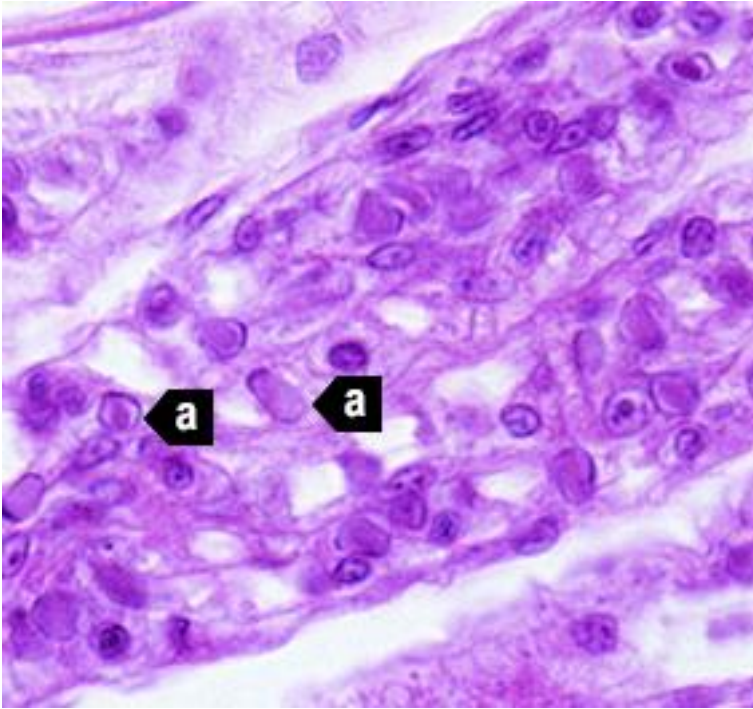
Figure 203 Histological section of stomach of juvenile Chinese white shrimp (*Penaeus (Fenneropenaeus) chinensis*) with advanced WSD



Note: Fully developed WSSV intranuclear inclusion bodies (a) are more basophilic, appear granular in texture and nearly fill affected hypertrophied nucleus. 1300x magnification.

Source: DV Lightner

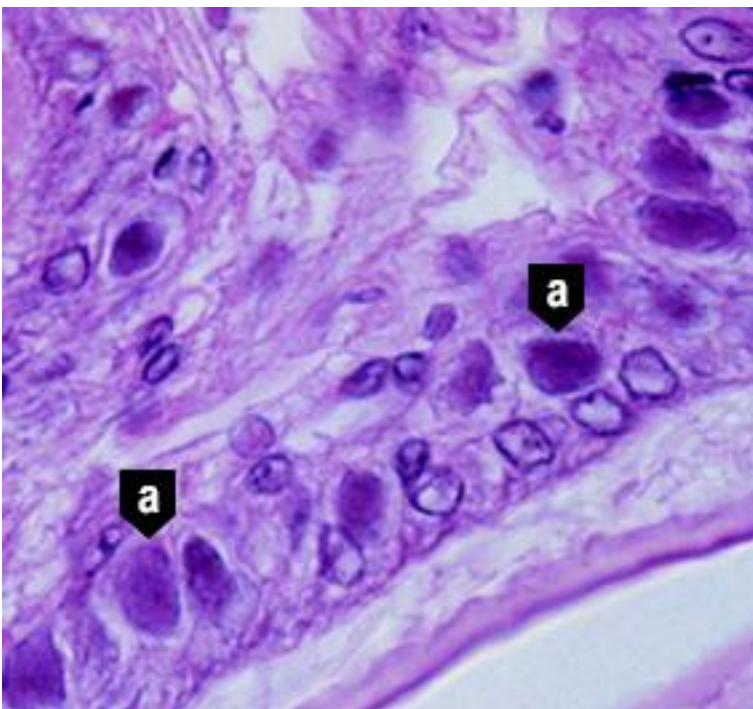
Figure 204 Histological section of gills from juvenile Chinese white shrimp (*Penaeus (Fenneropenaeus) chinensis*) with WSD



Note: Nearly one-quarter of cells are infected, as indicated by developing and fully developed intranuclear inclusion bodies (a). 900x magnification.

Source: DV Lightner

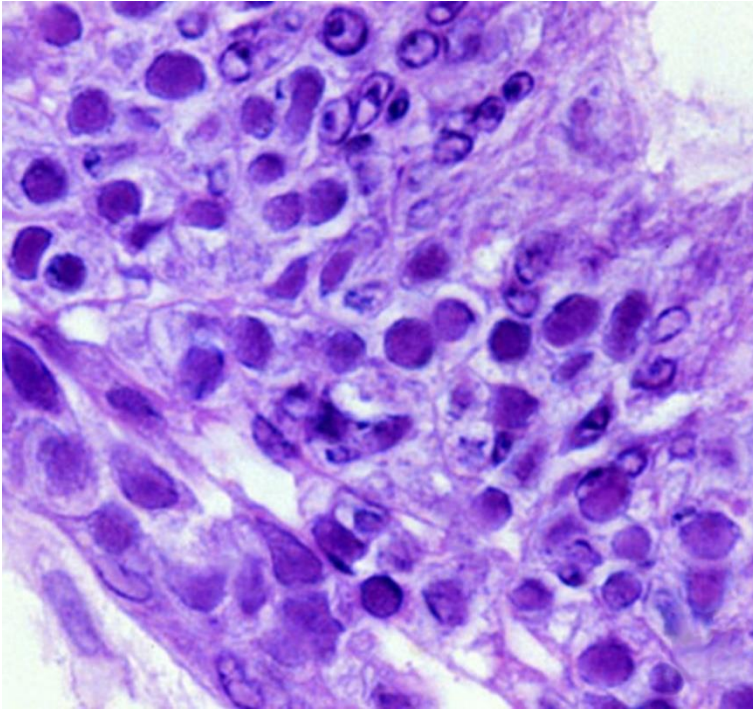
Figure 205 Histological section of stomach of Pacific blue shrimp (*Penaeus (Litopenaeus) stylirostris*) experimentally infected with WSSV



Note: Severe grade 4 infection evidenced by classic WSD intranuclear inclusion bodies (a). 900x magnification.

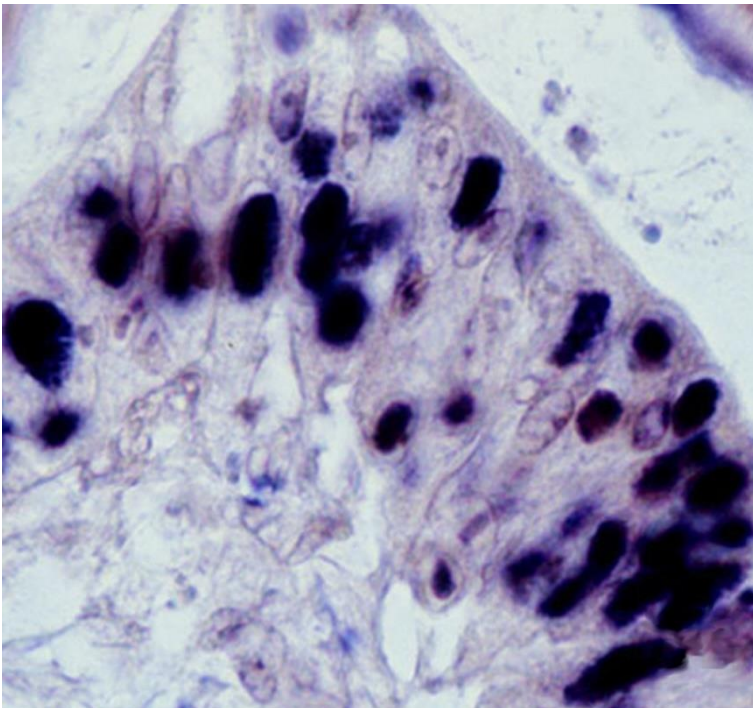
Source: DV Lightner

Figure 206 Histological section of stomach of Pacific white shrimp (*Penaeus (Litopenaeus) vannamei*) experimentally infected with WSSV



Note: Severe grade 4 infection with many classic WSD intranuclear inclusion bodies. 900x magnification.
Source: DV Lightner

Figure 207 In situ hybridisation of histological section of stomach of juvenile Pacific white shrimp (*Penaeus (Litopenaeus) stylirostris*) with WSD



Note: Intranuclear inclusion bodies in the cuticular epithelium of stomach reacting to digoxigenin-labelled DNA probe. 900x magnification.
Source: DV Lightner

Further reading

CABI Invasive Species Compendium [White spot disease](#)

CEFAS International Database on Aquatic Animal Diseases [White spot disease](#)

Department of Agriculture [AQUAVETPLAN disease strategy manual: White spot disease of prawns](#)

World Organisation for Animal Health [Manual of Diagnostic tests for aquatic animals](#)

Infection with yellowhead virus genotype 1 (YHV1)

Also known as yellowhead disease

Exotic disease

Figure 208 Yellowhead disease in giant black tiger prawns (*Penaeus monodon*)



Note: Infected prawns (left) show pale yellow heads.

Source: DV Lightner

Signs of disease

Important: Animals with this disease may show one or more of these signs, but the pathogen may still be present in the absence of any signs.

Disease signs at the farm, tank or pond level are:

- aggregations of moribund prawns near the water surface at the edge of the rearing pond or tank
- abnormally high feeding rate of infected 5g to 15g prawns for several days and then cessation of feeding
- mass mortality (up to 100%) occurring 2 to 4 days after cessation of feeding.

Gross pathological signs are:

- yellowing of the cephalothorax and general bleaching of the body
- white, yellow or brown gills
- exceptionally soft digestive gland compared with normal
- yellow, swollen digestive gland, making the head appear yellow.

Microscopic pathological signs are:

- moderate to large numbers of deeply basophilic, evenly stained, spherical, cytoplasmic inclusions within tissues of ectodermal and mesodermal origin.

Disease agent

Yellowhead disease is caused by infection with yellowhead virus genotype 1 (YHV1), a corona-like RNA virus in the genus *Okavirus*, family *Roniviridae* and order *Nidovirales*. YHV1 is one of at least 10 genotypes in the yellowhead complex of viruses and is the only known agent of yellowhead disease. Gill-associated virus (GAV) is designated as genotype 2 (covered separately within the field guide). Several other known genotypes in the complex (genotypes 3 to 10) occur commonly in black tiger prawns (*Penaeus monodon*) in East Africa, Asia and Australia. Most of these other genotypes are rarely or never associated with disease.

Host range

YHV1 is highly infectious for most known species of cultivated penaeid prawns. There are variations in the susceptibility of different species to disease. Laboratory trials have shown that YHV1 can cause high mortality in black tiger prawns, Pacific white shrimp, Pacific blue shrimp, northern brown shrimp, northern pink shrimp, Sunda river prawns, mysid shrimp and barred estuarine shrimp. Until proven otherwise, it should be assumed that most penaeid prawns worldwide are susceptible to infection with YHV1.

Table 66 Species known to be susceptible to infection with YHV1

Common name	Scientific name
Barred estuarine shrimp	<i>Palaemon serrifer</i>
Black tiger prawn ^a	<i>Penaeus monodon</i>
Brown tiger prawn	<i>Penaeus esculentus</i>
Daggerblade grass shrimp	<i>Palaemon pugio</i>
Giant freshwater prawn	<i>Macrobrachium rosenbergii</i>
Greentail prawn	<i>Metapenaeus bennettiae</i>
Gulf banana prawn ^a	<i>Penaeus (Fenneropenaeus) merguensis</i>
Jelly prawns ^a	<i>Acetes</i> spp.
Kuruma prawn ^a	<i>Penaeus (Marsupenaeus) japonicus</i>
Mississippi grass shrimp	<i>Palaemon kadiakensis</i>
Mysid shrimp ^a	<i>Palaemon styliiferus</i>
Northern brown shrimp	<i>Penaeus (Farfantepenaeus) aztecus</i>
Northern pink shrimp	<i>Penaeus (Farfantepenaeus) duorarum</i>
Northern white shrimp ^a	<i>Penaeus (Litopenaeus) setiferus</i>
Pacific blue shrimp	<i>Penaeus (Litopenaeus) stylirostris</i>
Pacific white shrimp	<i>Penaeus (Litopenaeus) vannamei</i>
Red endeavour (greasyback) prawn ^a	<i>Metapenaeus ensis</i>
Sunda river prawn	<i>Macrobrachium sintangene</i>

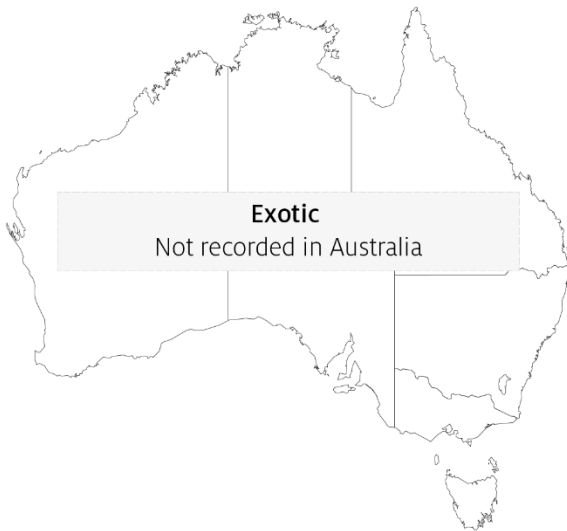^a Naturally susceptible. Note: Other species shown to be experimentally susceptible.

Presence in Australia

Exotic disease—not recorded in Australia.

YHV1 is the most virulent genotype within the yellowhead complex, and the only known agent to cause yellowhead disease. It has never been recorded in Australia and is considered exotic. Other genotypes are known to occur in Australia, including YHV2 (gill associated virus), YHV6 and YHV7.

Map 45 Presence of YHV1, by jurisdiction



Epidemiology

- *Penaeus monodon* suffers acute epizootics, with mortality reaching 100% within 3 to 5 days of the first appearance of gross signs of infection.
- YHV1 can be transmitted horizontally by injection, ingestion of infected tissue, immersion in membrane-filtered tissue extracts or cohabitation with infected shrimp. Transmission has also been demonstrated by injection of extracts of jelly prawns (*Acetes* spp.) collected from infected ponds.
- Vertical transmission occurs from both male and female parents, possibly via surface infection or contamination of tissue surrounding fertilised eggs.
- *Penaeus monodon* younger than 15 days postlarvae are resistant to YHV1. Those from postlarval days 20 to 25 to subadult are highly susceptible.
- Mortalities usually occur during the early to late juvenile stages in rearing ponds.
- There are at least 10 genotypes of virus in the yellowhead virus group. YHV1 is the only genotype known to cause yellowhead disease.

Differential diagnosis

The list of [similar diseases](#) in the next section refers only to the diseases covered by this field guide. Gross pathological signs may also be representative of diseases not included in this guide. Gross signs should not be relied on to provide a definitive diagnosis. They should be used as a tool to help identify the listed diseases that most closely account for the observed signs.

Similar diseases

Gill associated virus disease (GAV), infection with *Hepatobacter penaei* (NHP), infection with shrimp haemocyte iridescent virus (SHIV) and infection with Taura syndrome virus (TSV).

Sample collection

Only trained personnel should collect samples. Using only gross pathological signs to differentiate between diseases is not reliable, and some aquatic animal disease agents pose a risk to humans. If you are not appropriately trained, phone your state or territory hotline number and report your observations. If you have to collect samples, the agency taking your call will advise you on the appropriate course of action. Local or district fisheries or veterinary authorities may also advise on sampling.

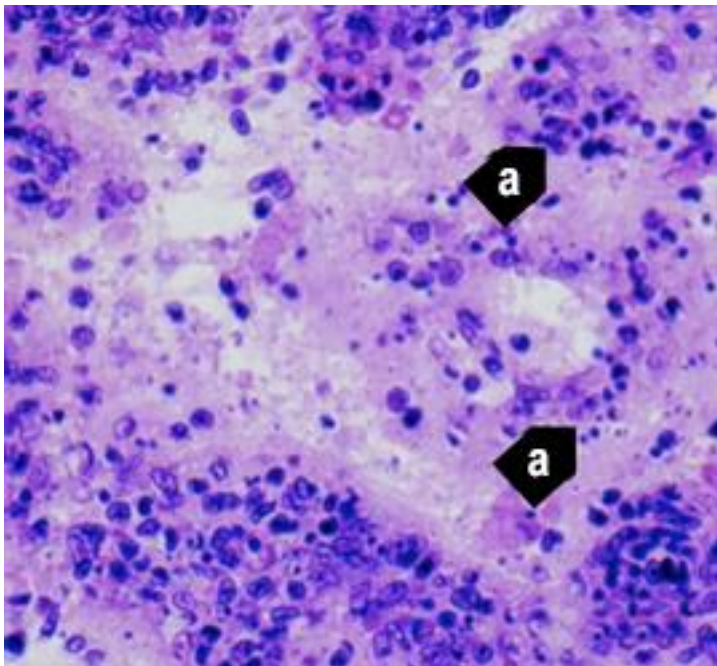
Emergency disease hotline

See something you think is this disease? Report it. Even if you're not sure.

Call the Emergency Animal Disease Watch Hotline on **1800 675 888**. They will refer you to the right state or territory agency.

Microscope images

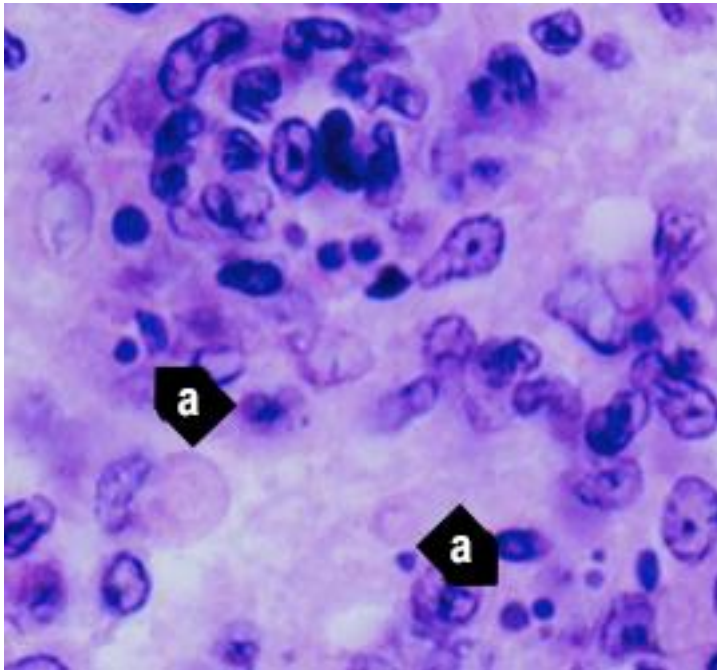
Figure 209 Histological section of lymphoid organ of juvenile giant black tiger prawn (*Penaeus monodon*) with severe acute yellowhead disease



Note: Generalised, diffuse necrosis of lymphoid organ (LO) cells with pyknotic and karyorrhectic nuclei (a). Necrosis in acute yellowhead disease distinguishes it from infection due to Taura syndrome virus, which produces similar cytopathology in other target tissues, but not in the LO. 525x magnification.

Source: DV Lightner

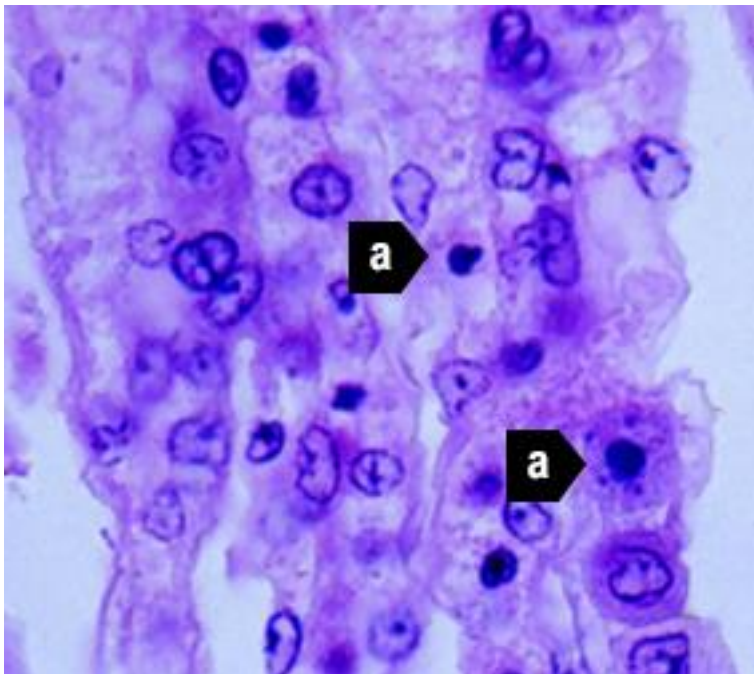
Figure 210 Histological section of lymphoid organ of juvenile giant black tiger prawn (*Penaeus monodon*) with severe acute yellowhead disease



Note: Same sample as Figure 209. Single or multiple perinuclear inclusion bodies, ranging from pale to darkly basophilic, are apparent in some affected cells (a). 1700x magnification.

Source: DV Lightner

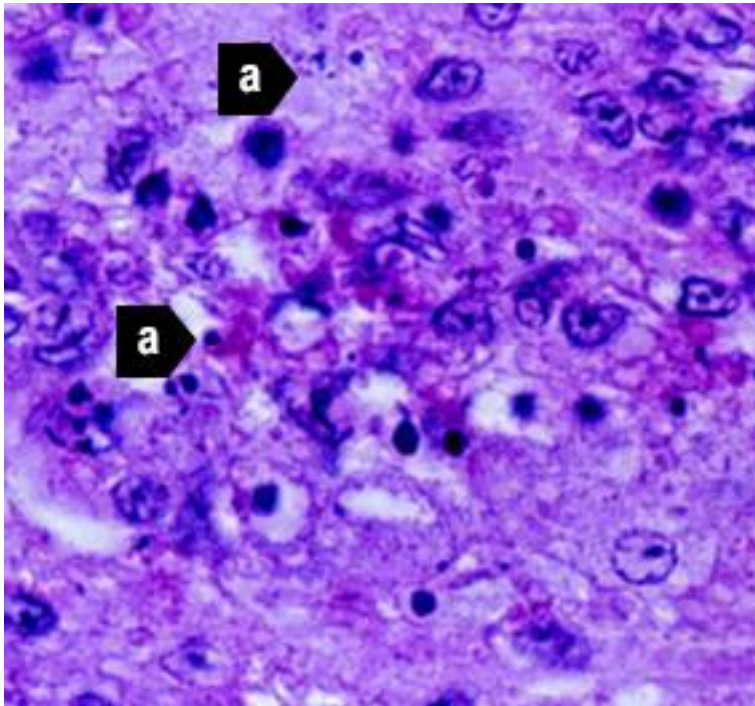
Figure 211 Histological section of the gills from a juvenile black tiger prawn (*Penaeus monodon*) with yellowhead disease



Note: Generalised, diffuse necrosis of cells in the gill lamellae, affected cells displaying pyknotic and karyorrhectic nuclei (a). A few large, conspicuous, generally spherical cells with basophilic cytoplasm are present in the section. These cells may be immature haemocytes, released prematurely in response to a yellowhead virus-induced haemocytopaenia. 1000x magnification.

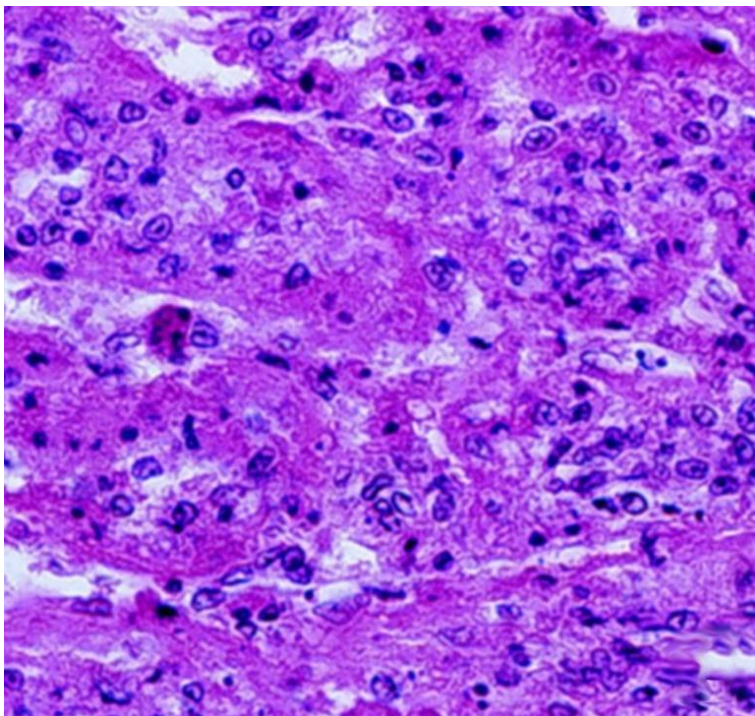
Source: DV Lightner

Figure 212 Histological section of lymphoid organ of juvenile Pacific white shrimp (*Penaeus (Litopenaeus) vannamei*) experimentally infected with YHV1



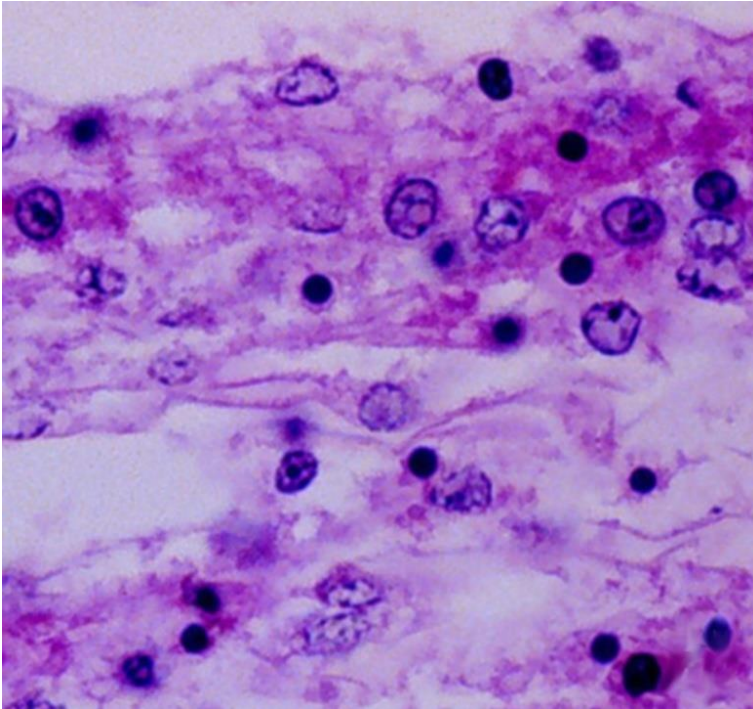
Note: Severe (grade 3–4) diffuse to multifocal necrosis, characterised by cells with increased eosinophilic cytoplasm, pyknotic or karyorrhectic nuclei (a) and pale to densely basophilic perinuclear inclusions. 1000x magnification.
Source: DV Lightner

Figure 213 Histological section of lymphoid organ of northern brown shrimp (*Penaeus (Farfantepenaeus) aztecus*) experimentally infected with YHV1



Note: Severe (grade 3–4) diffuse to multifocal necrosis, characterised by cells with increased eosinophilic cytoplasm, pyknotic or karyorrhectic nuclei and pale to densely basophilic perinuclear inclusions. 525x magnification.
Source: DV Lightner

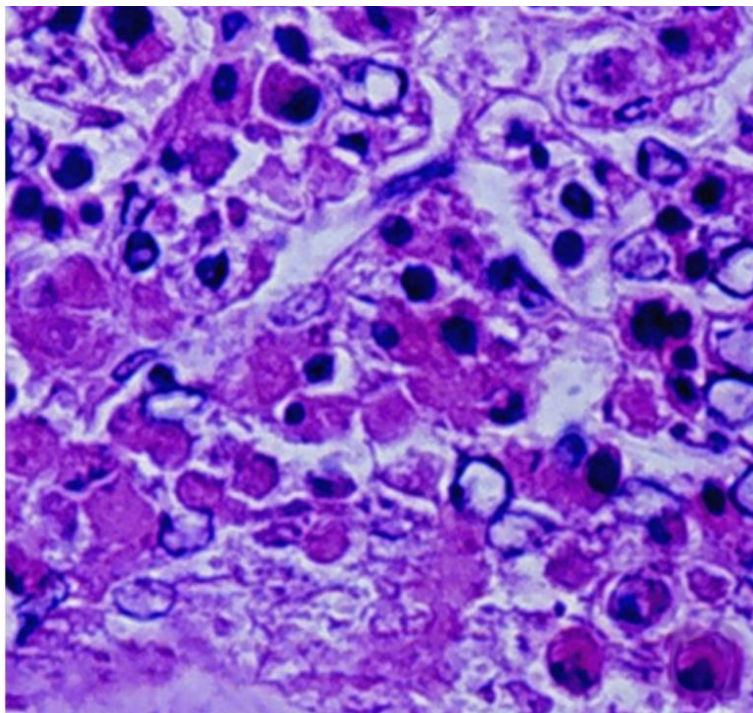
Figure 214 Histological section of gills of juvenile northern pink shrimp (*Penaeus (Farfantepenaeus) duorarum*) experimentally infected with YHV1



Note: Severe (grade 4) diffuse to multifocal necrosis, characterised by cells with increased eosinophilic cytoplasm, pyknotic or karyorrhectic nuclei, and pale to densely basophilic perinuclear inclusions. 1000× magnification.

Source: DV Lightner

Figure 215 Histological section of oesophagus of Pacific white shrimp (*Penaeus (Litopenaeus) vannamei*) experimentally infected with YHV1



Note: Severe (grade 4) diffuse to multifocal necrosis is present, characterised by cells with increased eosinophilic cytoplasm, pyknotic or karyorrhectic nuclei, and pale to densely basophilic perinuclear inclusions. 1000x magnification.

Source: DV Lightner

Further reading

CABI Invasive Species Compendium [Yellow head disease](#)

CEFAS International Database on Aquatic Animal Diseases [Yellowhead disease](#)

World Organisation for Animal Health [Manual of diagnostic tests for aquatic animals](#)

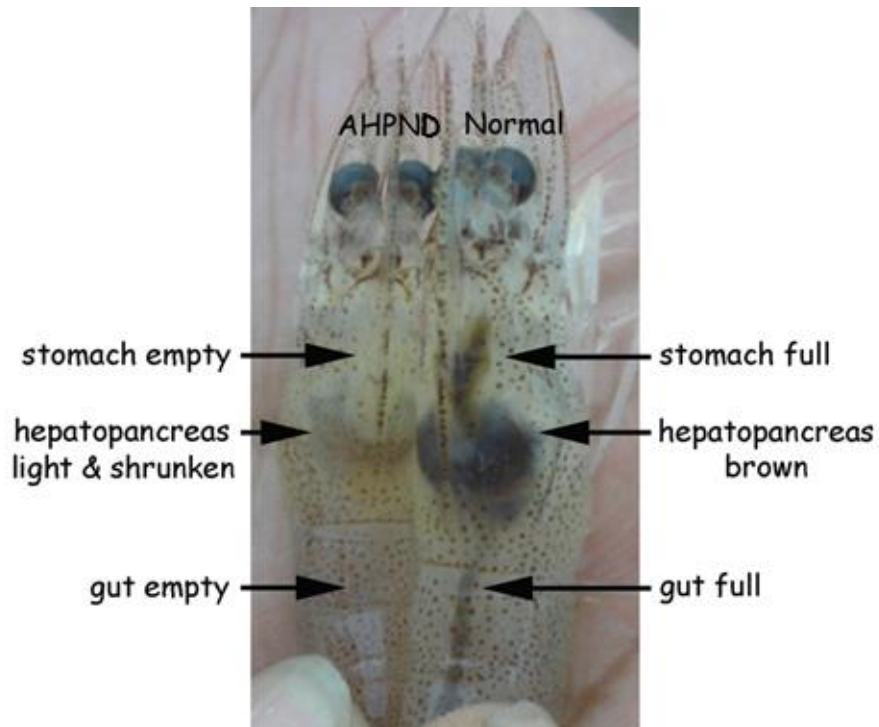
Bacterial diseases of crustaceans

Acute hepatopancreatic necrosis disease (AHPND)

Also known as early mortality syndrome (EMS)

Exotic disease

Figure 216 Pacific white shrimp (*Penaeus (Litopenaeus) vannamei*) with AHPND



Note: Infected shrimp shows empty stomach and gut and a paler and shrunken hepatopancreas. Healthy shrimp shows a full stomach and gut and brown hepatopancreas.

Source: DV Lightner

Figure 217 Black tiger prawn (*Penaeus monodon*) with AHPND



Note: Pale colour and small size of excised, atrophied hepatopancreas.

Source: DV Lightner

Signs of disease

Important: Animals with this disease may show one or more of these signs, but the pathogen may still be present in the absence of any signs.

Disease signs at the farm, tank or pond level are:

- pale to white hepatopancreas due to pigment loss in the connective tissue capsule
- moribund prawns sink to bottom
- onset of clinical signs and mass mortality up to 100% starting as early as 10 days post stocking and usually within 30 to 35 days.

Gross pathological signs are:

- soft shell
- guts with discontinuous contents or no contents
- black (melanised) spots or streaks visible within the hepatopancreas
- atrophy (shrinkage) of the hepatopancreas
- hepatopancreas does not squash easily between thumb and forefinger.

Microscopic pathological signs are:

- acute phase
 - massive and progressive degeneration of the hepatopancreas tubules from proximal to distal
 - significant rounding and sloughing of hepatopancreas tubule epithelial cells into the tubule lumens, collecting ducts and posterior stomach
- terminal phase
 - massive secondary bacterial infection (*Vibrio* spp.) in the sloughed cells
 - complete destruction of the hepatopancreas.

The only definitive histopathology is in the acute stage with the massive sloughing of hepatopancreas tubule epithelial cells in the absence of bacteria.

Disease agent

AHPND is also known as early mortality syndrome (EMS), and is caused by infection with *Vibrio parahaemolyticus* (Vp_{AHPND}). Vp_{AHPND} contains a plasmid (pVA1) of an approximately 70-kbp with genes that encode homologues of the *Photobacterium* insect-related (Pir) toxins PirA and PirB. There are reports of the isolation of other *Vibrio* species from clinical cases of AHPND. However, only Vp_{AHPND} has been demonstrated to cause AHPND.

Host range

This disease affects mainly *Penaeus (Litopenaeus) vannamei* and *Penaeus monodon*. It may also be problematic in *Penaeus (Fenneropenaeus) chinensis*. Kuruma prawns are unaffected but may act as carriers. Live polychaete worms may also act as vectors for specific virulent strains of *Vibrio parahaemolyticus* when used to feed broodstock prawns.

Table 67 Species known to be susceptible to AHPND

Common name	Scientific name
Black tiger prawn ^a	<i>Penaeus monodon</i>
Chinese white shrimp ^a	<i>Penaeus (Fenneropenaeus) chinensis</i>
Kuruma prawn	<i>Penaeus (Marsupenaeus) japonicus</i>
Pacific white shrimp ^a	<i>Penaeus (Litopenaeus) vannamei</i>

^a Naturally susceptible.

Table 68 Non-crustacean carriers of AHPND

Common name	Scientific name
Polychaetes ^a	Various genera and species

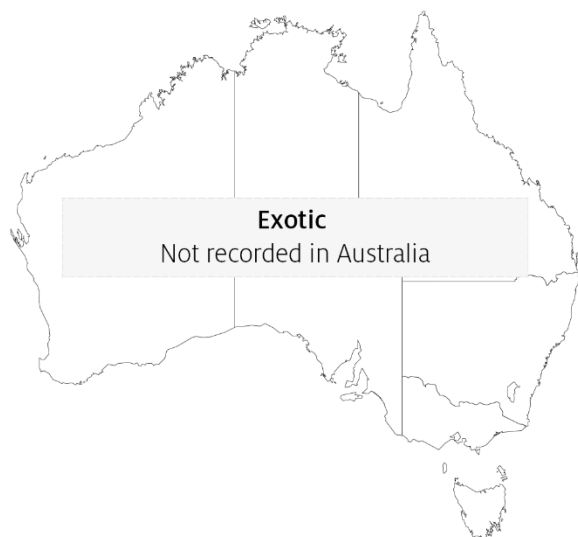^a Naturally susceptible.

Presence in Australia

Exotic disease—not recorded in Australia.

Vibrio parahaemolyticus is known to occur in Australia. However, specific strains containing the plasmid (pVA1) of approximately 70-kbp with genes that encode homologues of the *Photobacterium* insect-related (Pir) toxins, PirA and PirB have not been recorded.

Map 46 Presence of AHPND, by jurisdiction



Epidemiology

- AHPND was first reported in 2009 as a novel disease of unknown aetiology in cultured prawns and was initially named early mortality syndrome (EMS). A more descriptive term for the syndrome, acute hepatopancreatic necrosis syndrome (AHPNS), was later adopted.
- With the aetiological agents now identified, the current disease name is AHPND.
- AHPND is transmitted horizontally by the oral route and cohabitation.
- Water sources with low salinity (less than 20ppt) seem to reduce the incidence of the disease.
- Other factors that may lead to AHPND in areas where these specific bacterial strains are present include overfeeding, poor seed quality, poor water quality, poor feed quality, algal blooms or algal crashes.
- The hatchery practice of feeding live polychaete worms to broodstock to increase nauplii production presents a significant biosecurity risk and is a possible source of AHPND.
- It may be possible to reduce AHPND outbreaks by changing the design of rearing ponds, and through changes in husbandry practices.

Differential diagnosis

The list of [similar diseases](#) in the next section refers only to the diseases covered by this field guide. Gross pathological signs may also be representative of diseases not included in this guide. Do not rely on gross signs to provide a definitive diagnosis. Use them as a tool to help identify the listed diseases that most closely account for the observed signs.

Similar diseases

Infection with *Enterocytozoon hepatopenaei* (EHP), infection with *Hepatobacter penaei* (NHP) and infection with shrimp haemocyte iridescent virus (SHIV).

Sample collection

Only trained personnel should collect samples. Using only gross pathological signs to differentiate between diseases is not reliable, and some aquatic animal disease agents pose a risk to humans. If you are not appropriately trained, phone your state or territory hotline number and report your observations. If you have to collect samples, the agency taking your call will advise you on the appropriate course of action. Local or district fisheries or veterinary authorities may also advise on sampling.

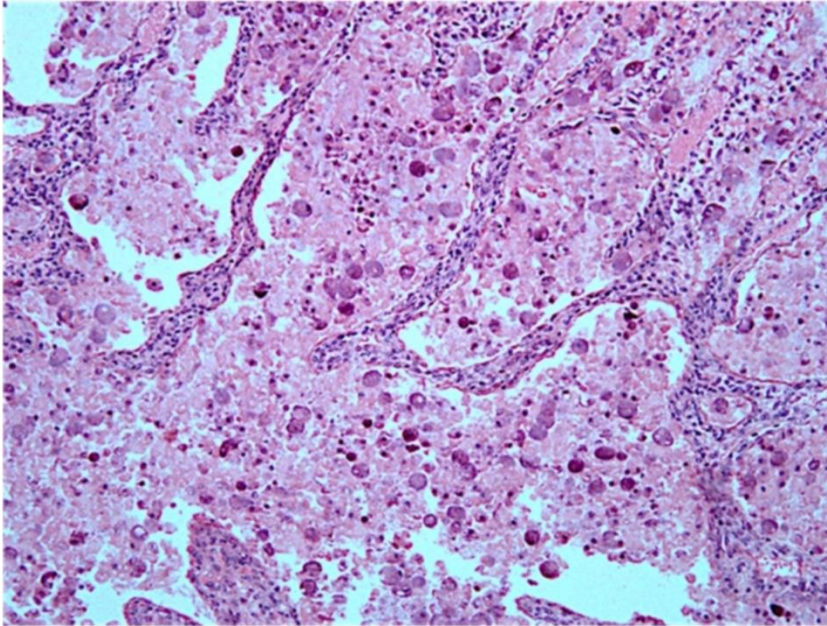
Emergency disease hotline

See something you think is this disease? Report it. Even if you're not sure.

Call the Emergency Animal Disease Watch Hotline on **1800 675 888**. They will refer you to the right state or territory agency.

Microscope images

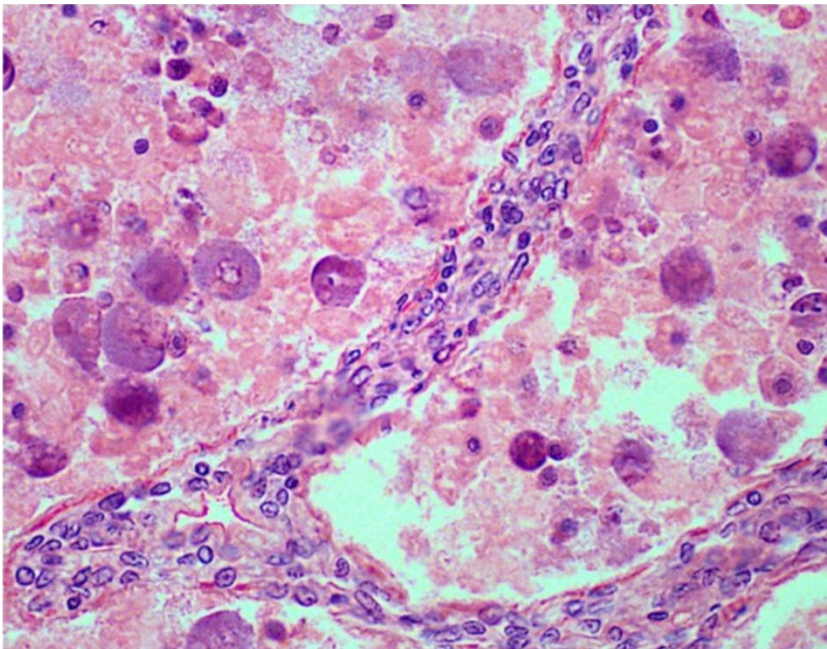
Figure 218 Low-magnification photomicrograph of hepatopancreas of juvenile Pacific white shrimp (*Penaeus (Litopenaeus) vannamei*) with acute AHPND



Note: Massive necrosis and sloughing of the tubule epithelial cells into the tubule lumen.

Source: J Brock

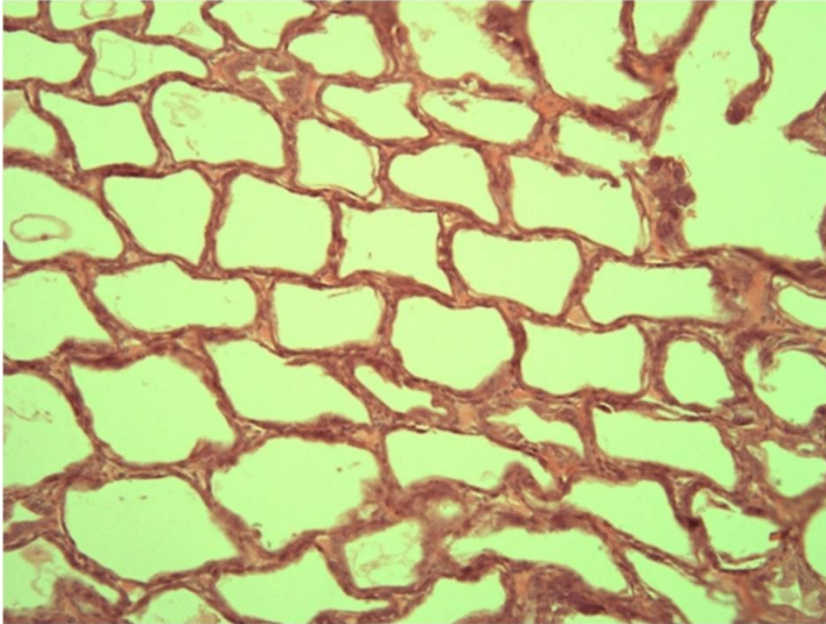
Figure 219 High magnification photomicrograph of hepatopancreas of juvenile Pacific white shrimp (*Penaeus (Litopenaeus) vannamei*) with acute AHPND



Note: Massive necrosis, sloughing and rounding up of tubule epithelial cells as they disintegrate into the tubule lumen in the absence of obvious bacterial infection.

Source: J Brock

Figure 220 Low magnification photomicrograph of hepatopancreas of juvenile Pacific white shrimp (*Penaeus (Litopenaeus) vannamei*) with terminal AHPND



Note: Severe atrophy of the hepatopancreas tubules with almost complete loss of epithelium.

Source: J Brock

Further reading

CABI Invasive Species Compendium [Acute hepatopancreatic necrosis disease](#)

Network of Aquaculture Centres in Asia-Pacific [Acute hepatopancreatic necrosis: disease card](#)

World Organisation for Animal Health [Manual of diagnostic tests for aquatic animals](#)

Infection with *Hepatobacter penaei*

Also known as necrotising hepatopancreatitis (NHP)

Exotic disease

Figure 221 Pacific white shrimp (*Penaeus (Litopenaeus) vannamei*) infected with *Hepatobacter penaei*



Note: Marked reduction in size and pale colour of hepatopancreas.

Source: DV Lightner

Figure 222 Swimmerets of a Pacific white shrimp (*Penaeus (Litopenaeus) vannamei*) infected with *Hepatobacter penaei*



Note: Darkening at base of swimmerets, giving a fouled, 'dirty' appearance.

Source: DV Lightner

Signs of disease

Important: Animals with this disease may show one or more of these signs, but the pathogen may still be present in the absence of any signs.

Disease signs at the farm, tank or pond level are:

- lethargy
- emaciation
- heavy protozoan or bacterial fouling
- reduced growth rate.

Gross pathological signs are:

- soft shell
- flaccid body
- black gills
- empty intestinal tract
- degenerated or atrophied digestive gland (hepatopancreas), which appears pale to white
- black (melanised) streaks in the hepatopancreas.

Microscopic pathological signs are:

- multifocal granulomatous lesions in hepatopancreatic tubules, with atrophy of adjacent hepatopancreatic tubule epithelial cells
- tubular cells within the granulomatous lesions that can be hypertrophied and contain basophilic organisms within the cytoplasm
- sloughing of tubule epithelial cells
- severe haemocytic inflammation of the intratubular spaces.

Disease agent

NHP is caused by infection with *Hepatobacter penaei*, a Gram-negative, intracytoplasmic species of alphaproteobacterium that infects the hepatopancreas of prawns. *H. penaei* is also referred to as the NHP bacterium.

H. penaei exists in two morphological forms:

- rod-shaped, nonflagellated rickettsia-like organism
- helical flagellated form.

Host range

Table 69 Species known to be susceptible to *Hepatobacter penaei*

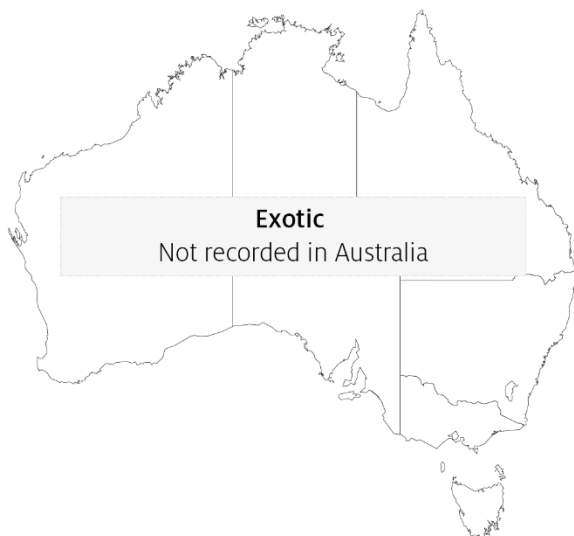Common name	Scientific name
Aloha prawn	<i>Penaeus marginatus</i>
American lobster	<i>Homarus americanus</i>
Black tiger prawn	<i>Penaeus monodon</i>
Gulf banana prawn	<i>Penaeus (Fenneropenaeus) merguensis</i>
Northern brown shrimp ^a	<i>Penaeus (Farfantepenaeus) aztecus</i>
Northern pink shrimp ^a	<i>Penaeus (Farfantepenaeus) duorarum</i>
Northern white shrimp ^a	<i>Penaeus (Litopenaeus) setiferus</i>
Pacific blue shrimp ^a	<i>Penaeus (Litopenaeus) stylirostris</i>
Pacific white shrimp ^a	<i>Penaeus (Litopenaeus) vannamei</i>
Yellow-leg shrimp ^a	<i>Penaeus (Farfantepenaeus) californiensis</i>

^a Naturally susceptible.

Presence in Australia

Exotic disease—not recorded in Australia.

Map 47 Presence of *Hepatobacter penaei*, by jurisdiction



Epidemiology

- NHP outbreaks are often preceded by lengthy periods of high water temperatures (29°C to 31°C) and elevated salinity (up to 40ppt).
- Mortalities usually occur midway through the grow-out phase and can reach 90% to 95% within 30 days.
- NHP appears to be transmitted by direct ingestion of carrier prawns (survivors of *H. penaei* infections may carry the bacteria for life) and through contaminated water.
- *Hepatobacter penaei* may also be shed in faeces and contribute to disease transmission.

Differential diagnosis

The list of [similar diseases](#) in the next section refers only to the diseases covered by this field guide. Gross pathological signs may also be representative of diseases not included in this guide. Do not rely on gross signs to provide a definitive diagnosis. Use them as a tool to help identify the listed diseases that most closely account for the observed signs.

Similar diseases

Acute hepatopancreatic necrosis disease (AHPND) and infection with *Enterocytozoon hepatopenaei* (EHP).

Sample collection

Only trained personnel should collect samples. Using only gross pathological signs to differentiate between diseases is not reliable, and some aquatic animal disease agents pose a risk to humans. If you are not appropriately trained, phone your state or territory hotline number and report your observations. If you have to collect samples, the agency taking your call will advise you on the appropriate course of action. Local or district fisheries or veterinary authorities may also advise on sampling.

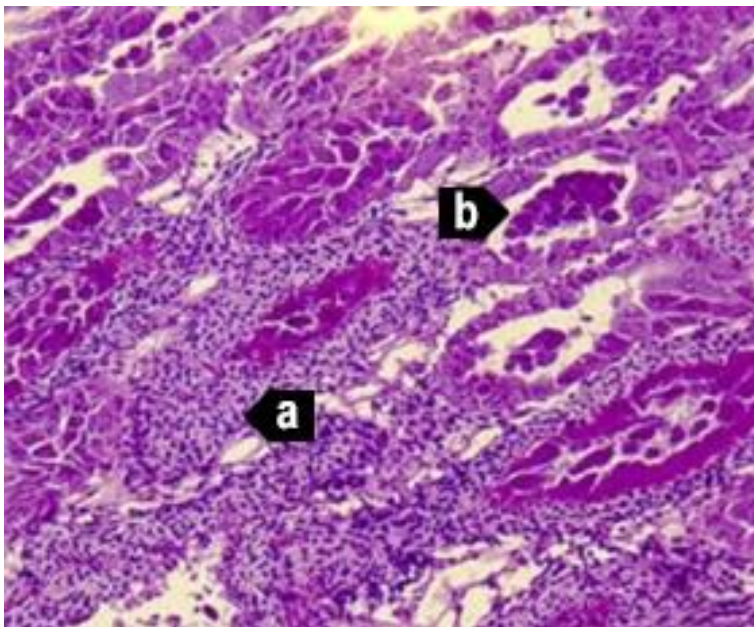
Emergency disease hotline

See something you think is this disease? Report it. Even if you're not sure.

Call the Emergency Animal Disease Watch Hotline on **1800 675 888**. They will refer you to the right state or territory agency.

Microscope images

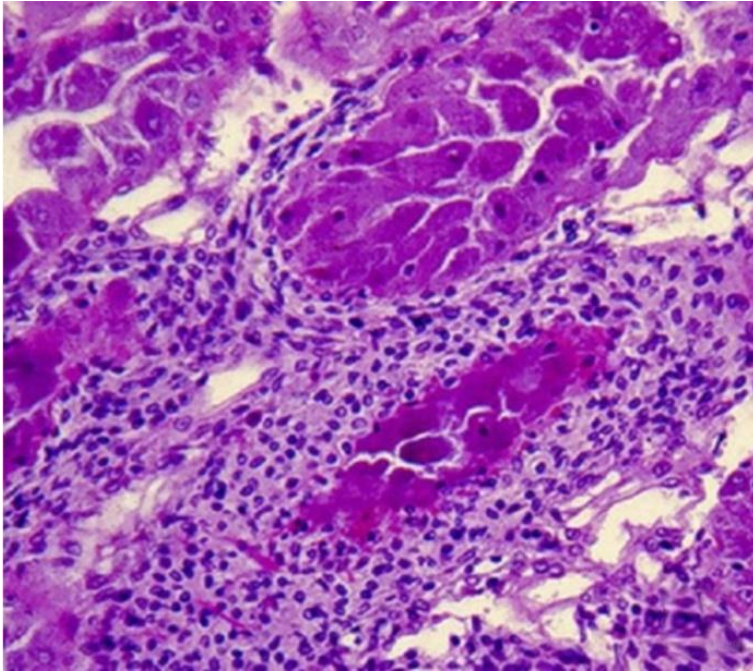
Figure 223 Photomicrograph of hepatopancreas of juvenile Pacific white shrimp (*Penaeus (Litopenaeus) vannamei*) with severe subacute (grade 3–4) NHP



Note: Principal histopathological changes due to the disease include severe haemocytic inflammation (with some melanised foci) of the intratubular spaces (a) in response to necrosis, cytolysis and sloughing of hepatopancreas tubule epithelial cells (b). 150x magnification.

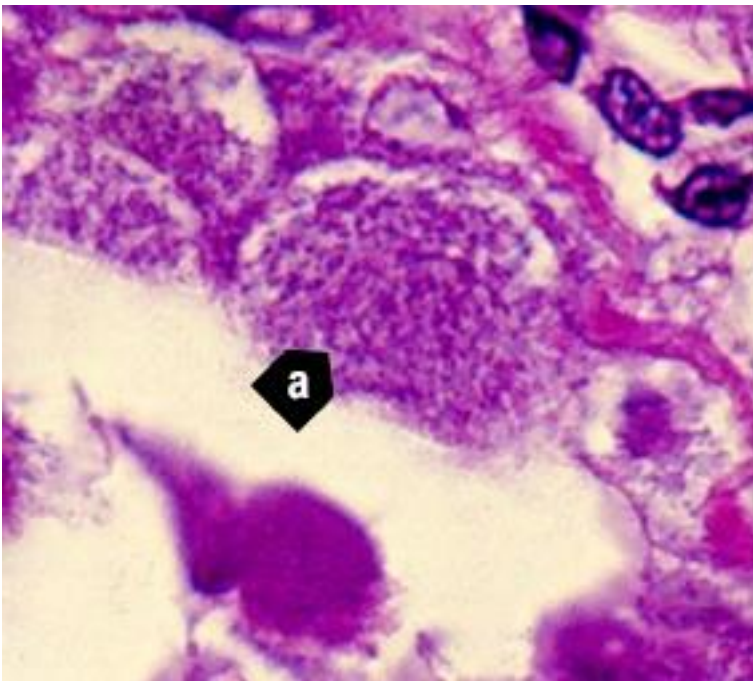
Source: DV Lightner

Figure 224 Photomicrograph of hepatopancreas of juvenile Pacific white shrimp (*Penaeus (Litopenaeus) vannamei*) with severe subacute (grade 3–4) NHP



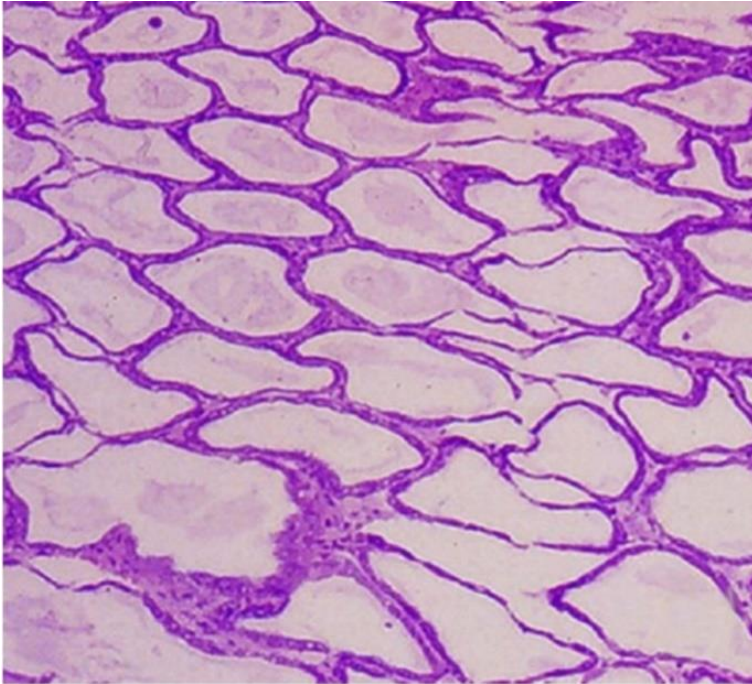
Note: Higher magnification of upper left of Figure 223. 300x magnification.
Source: DV Lightner

Figure 225 Photomicrograph of hepatopancreas of juvenile Pacific white shrimp (*Penaeus (Litopenaeus) vannamei*) with severe subacute (grade 3–4) NHP



Note: Higher magnification view of Figure 223 and Figure 224. Tubule epithelial cells have no cytoplasmic lipid droplets. Instead, they contain masses of the tiny, non-membrane bound intracytoplasmic *H. penaei* (a). 1700x magnification.
Source: DV Lightner

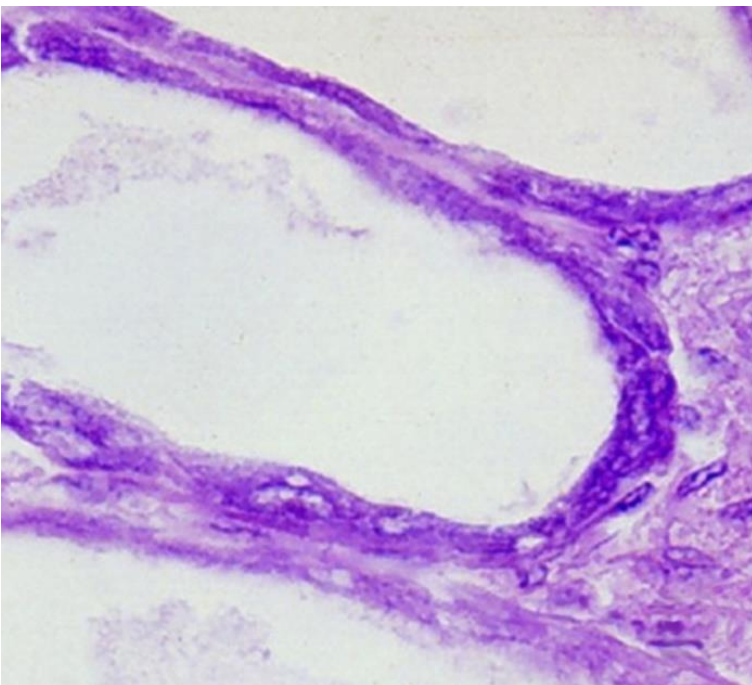
Figure 226 Photomicrograph of hepatopancreas of juvenile Pacific white shrimp (*Penaeus (Litopenaeus) vannamei*) with severe chronic NHP



Note: Hepatopancreas tubule epithelium is markedly atrophied, resulting in the formation of large oedematous (fluid-filled or 'watery') areas. 100x magnification

Source: DV Lightner

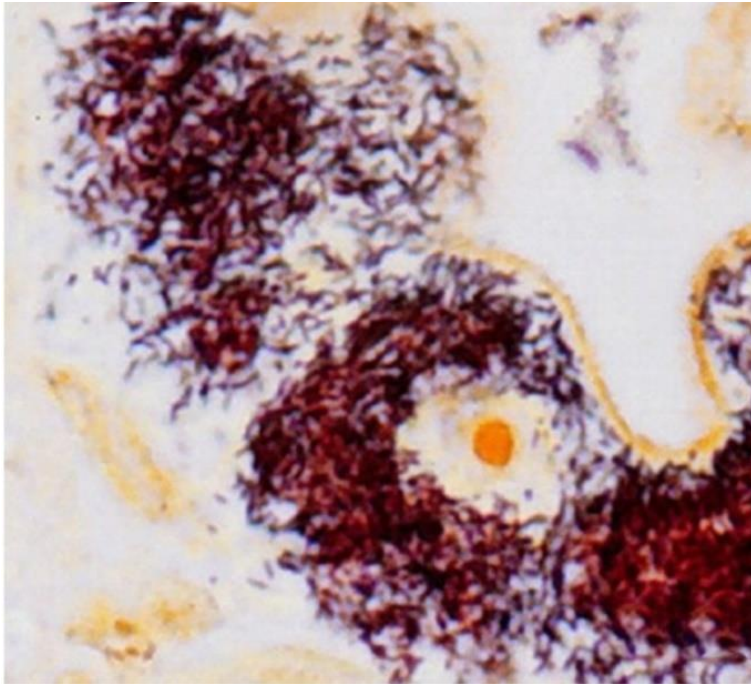
Figure 227 Photomicrograph of atrophied hepatopancreas from juvenile Pacific white shrimp (*Penaeus (Litopenaeus) vannamei*) with chronic NHP



Note: In contrast to the subacute phase of NHP, chronic-phase NHP shows no, or only occasional, foci of haemocytic inflammation of the necrotic or degenerating hepatopancreatic tubules. NHP bacteria may be found in the cytoplasm of an occasional hepatopancreocyte. 900x magnification.

Source: DV Lightner

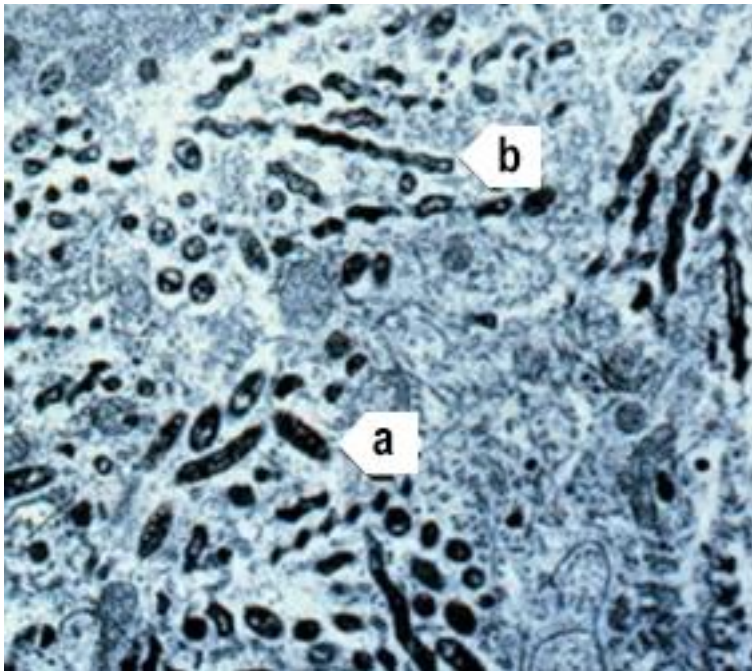
Figure 228 Hepatopancreocyte containing cytoplasmic masses of the NHP bacterium



Note: Silver stain has been used to show individual bacteria as brown or black. Unaffected cells and nuclei are pale brown. 1600x magnification.

Source: DV Lightner

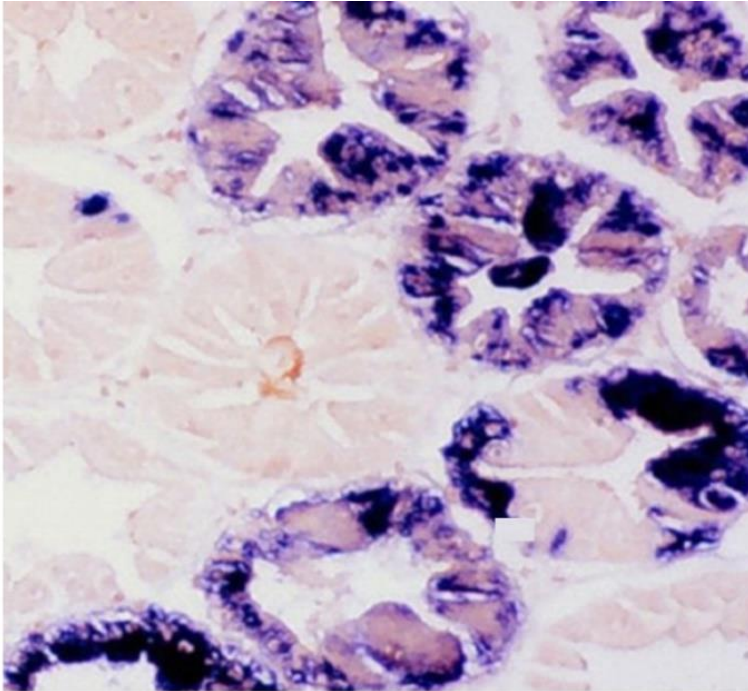
Figure 229 Transmission electron microscope micrograph of a hepatopancreocyte of a juvenile Pacific white shrimp (*Penaeus (Litopenaeus) vannamei*) with NHP



Note: The micrograph shows many intracellular rod-shaped forms (a) and helical forms (b) of the NHP bacterium in the cytoplasm. 10,000x magnification

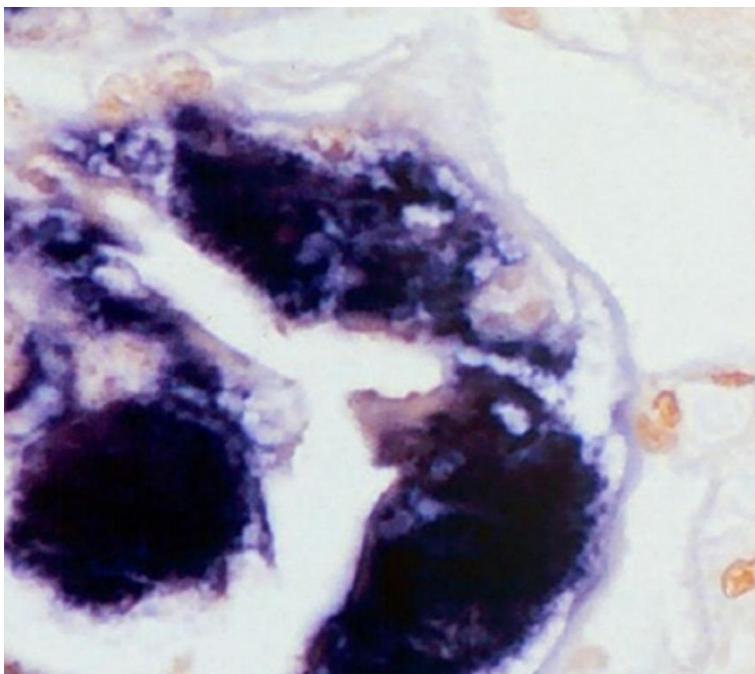
Source: DV Lightner

Figure 230 Hepatopancreas of juvenile Pacific white shrimp (*Penaeus (Litopenaeus) vannamei*) with NHP



Note: The digoxigenin-labelled DNA probe marks cytoplasmic masses of *Hepatobacter penaei* blue-black.
250x magnification.
Source: DV Lightner

Figure 231 Hepatopancreas of juvenile Pacific white shrimp (*Penaeus (Litopenaeus) vannamei*) with NHP



Note: The digoxigenin-labelled DNA probe marks cytoplasmic masses of *H. penaei* blue-black. 1000x magnification.
Source: DV Lightner

Further reading

CABI Invasive Species Compendium [Necrotising hepatopancreatitis](#)

CEFAS International Database on Aquatic Animal Diseases '[Hepatobacter penaei](#)' ([Necrotising hepatopancreatitis](#))

World Organisation for Animal Health [Manual of diagnostic tests for aquatic animals](#)

Parasitic diseases of crustaceans

Infection with *Enterocytozoon hepatopenaei* (EHP)

Also known as hepatopancreatic microsporidiosis

Exotic disease

Signs of disease

Important: Animals with this disease may show one or more of these signs, but the pathogen may still be present in the absence of any signs.

Disease signs at the farm, tank or pond level are:

- unusually retarded growth in the absence of other gross signs of disease.
- There are no specifically distinctive gross signs of infection by EHP.

Microscopic pathological signs are:

- the presence of basophilic, cytoplasmic inclusions (microsporidian sporocysts) containing clusters of elliptical to somewhat ovoid spores of $1.1 \pm 0.21\mu\text{m}$ by $0.6\text{--}0.7 \pm 0.1\mu\text{m}$ in haematoxylin and eosin stained tissue sections of hepatopancreas tubule epithelial cells
- free spores released from lysed cells occasionally observable in the tubule lumens.

Disease agent

Hepatopancreatic microsporidiosis is caused by infection with *Enterocytozoon hepatopenaei* (EHP), a microsporidian parasite classified within the family *Enterocytozoonidae*. It was first discovered in *Penaeus monodon* in Thailand in 2004.

Host range

Species known to be susceptible to *E. hepatopenaei* are listed in Table 70 and Table 71. A similar microsporidian has been reported to infect kuruma prawns in Queensland, but the taxonomic affinities of that parasite are unclear. *E. hepatopenaei* has also been detected in frozen *Artemia* biomass and live polychaetes.

Table 70 Species known to be susceptible to EHP

Common name	Scientific name
Black tiger prawn ^a	<i>Penaeus monodon</i>
Pacific white shrimp ^a	<i>Penaeus (Litopenaeus) vannamei</i>
Pacific blue shrimp	<i>Penaeus (Litopenaeus) stylirostris</i>

^a Naturally susceptible.

Table 71 Non-crustacean carriers

Common name	Scientific name
Brine shrimp ^a	<i>Artemia salina</i>
Polychaetes ^a	Various genera and species

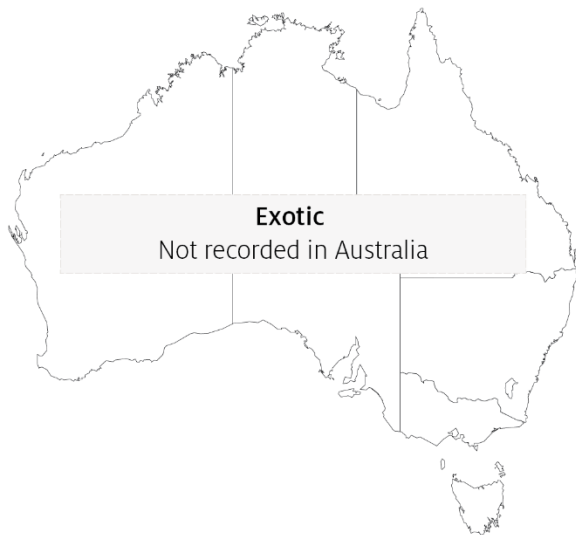^a Naturally susceptible.

Presence in Australia

Exotic disease—not recorded in Australia.

EHP is considered exotic to Australia. However, other microsporidians have been reported to infect kuruma prawns (*Penaeus (Marsupenaeus) japonicus*) in Queensland.

Map 48 Presence of *Enterocytozoon hepatopenaei*, by jurisdiction



Epidemiology

- EHP is known to infect only the tubule epithelial cells of the hepatopancreas of prawns.
- EHP should therefore not be confused with other microsporidians with different tissue tropism, such as *Agmasoma penaei* that infects muscle tissue and connective tissue leading to the gross signs of 'cotton shrimp disease' or 'white back' disease.
- EHP can be transmitted horizontally among prawns cohabiting in rearing ponds.
- Heavily infected prawns may display white faeces that are packed with microsporidian spores.
- Infection with EHP may be a significant risk factor in the development of acute hepatopancreatic necrosis disease (AHPND).

Differential diagnosis

The list of [similar diseases](#) in the next section refers only to the diseases covered by this field guide. Gross pathological signs may also be representative of diseases not included in this guide. Do not rely on gross signs to provide a definitive diagnosis. Use them as a tool to help identify the listed diseases that most closely account for the observed signs.

Similar diseases

Acute hepatopancreatic necrosis disease (AHPND) and infection with *Hepatobacter penaei* (NHP).

Sample collection

Only trained personnel should collect samples. Using only gross pathological signs to differentiate between diseases is not reliable, and some aquatic animal disease agents pose a risk to humans. If you are not appropriately trained, phone your state or territory hotline number and report your observations. If you have to collect samples, the agency taking your call will advise you on the appropriate course of action. Local or district fisheries or veterinary authorities may also advise on sampling.

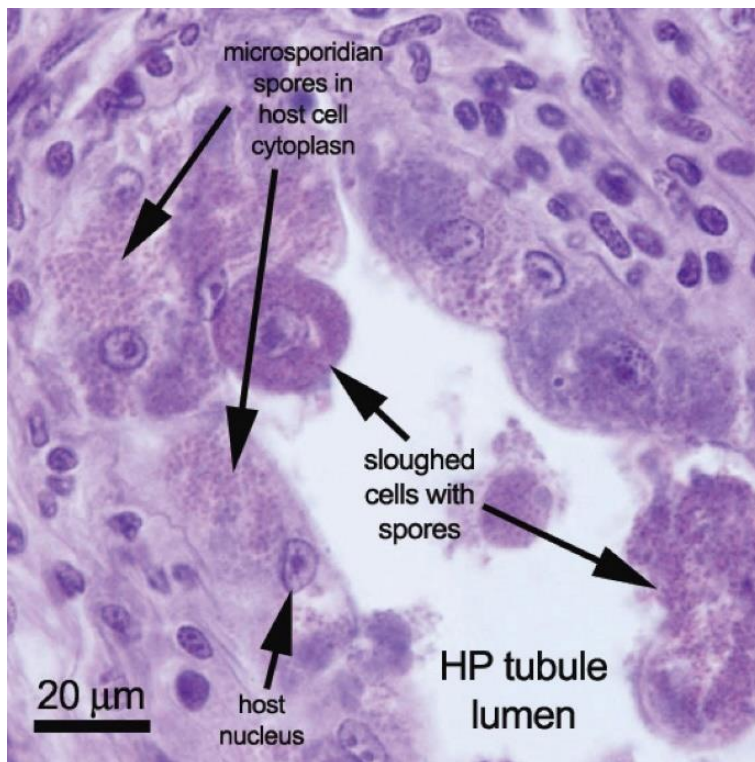
Emergency disease hotline

See something you think is this disease? Report it. Even if you're not sure.

Call the Emergency Animal Disease Watch Hotline on **1800 675 888**. They will refer you to the right state or territory agency.

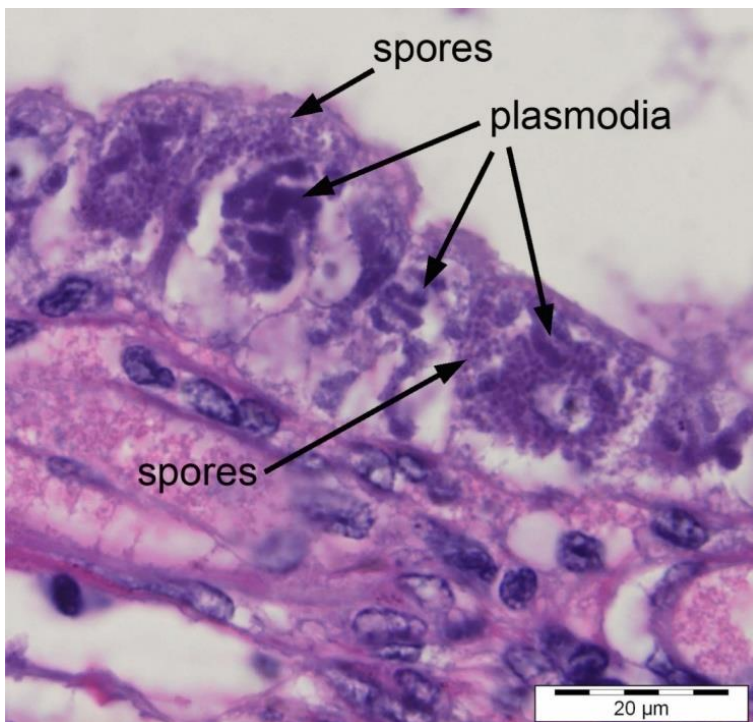
Microscope images

Figure 232 Histopathology of hepatopancreas of Pacific white shrimp (*Penaeus (Litopenaeus) vannamei*) infected with *Enterocytozoon hepatopenaei*



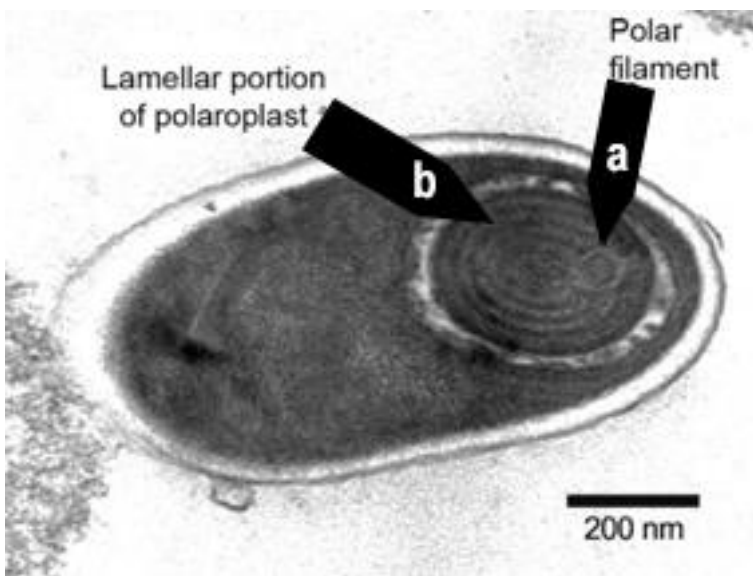
Note: Sloughed tubule epithelial cells containing many microsporidian spores in the cytoplasm. Scale bar = 20µm.
Source: T Flegel

Figure 233 Histopathology of hepatopancreas of Pacific white shrimp (*Penaeus (Litopenaeus) vannamei*) infected with *Enterocytozoon hepatopenaei*



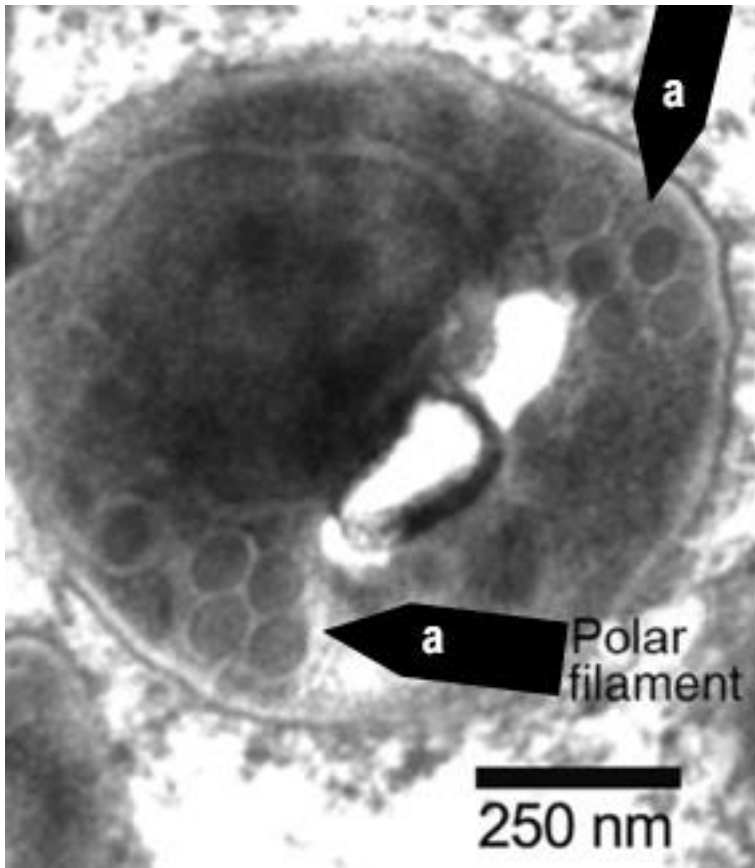
Note: Numerous spores inside sporocysts (plasmodia). Scale bar = 20μm.
Source: T Flegel

Figure 234 Electron micrograph of spore of *Enterocytozoon hepatopenaei*



Note: Polar filament (a) with 5 or 6 coils, in lamellar portion of polaroplast (b). Scale bar = 200nm
Source: T Flegel

Figure 235 Electron micrograph cross-section of polar filament in *Enterocytozoon hepatopenaei* spore



Note: Cross-sections of coils (a) of the polar filament. Scale bar = 250nm
Source: T Flegel

Further reading

Network of Aquaculture Centres in Asia-Pacific [Hepatopancreatic microsporidiosis caused by infection with 'Enterocytooon hepatopenaei': disease card](#)

Other diseases of crustaceans

Infection with *Aphanomyces astaci*

Also known as crayfish plague

Exotic disease

Figure 236 Dorsal surface of signal crayfish (*Pacifastacus leniusculus*) resistant to crayfish plague



Note: Focal melanised spot on upper carapace due to infection by *Aphanomyces astaci*.

Source: T Vrålstad

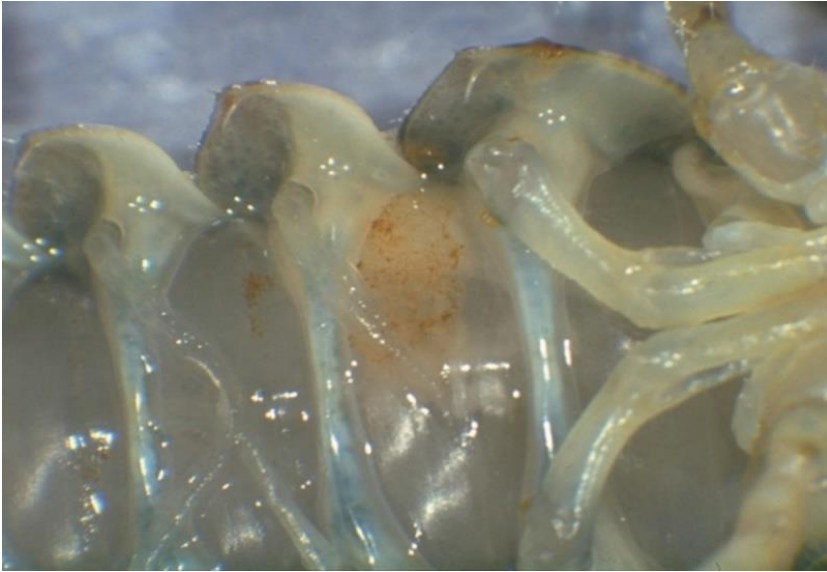
Figure 237 Ventral surface of signal crayfish (*Pacifastacus leniusculus*) resistant to crayfish plague



Note: Focal melanised spot on abdominal segment due to infection by *Aphanomyces astaci*.

Source: T Vrålstad

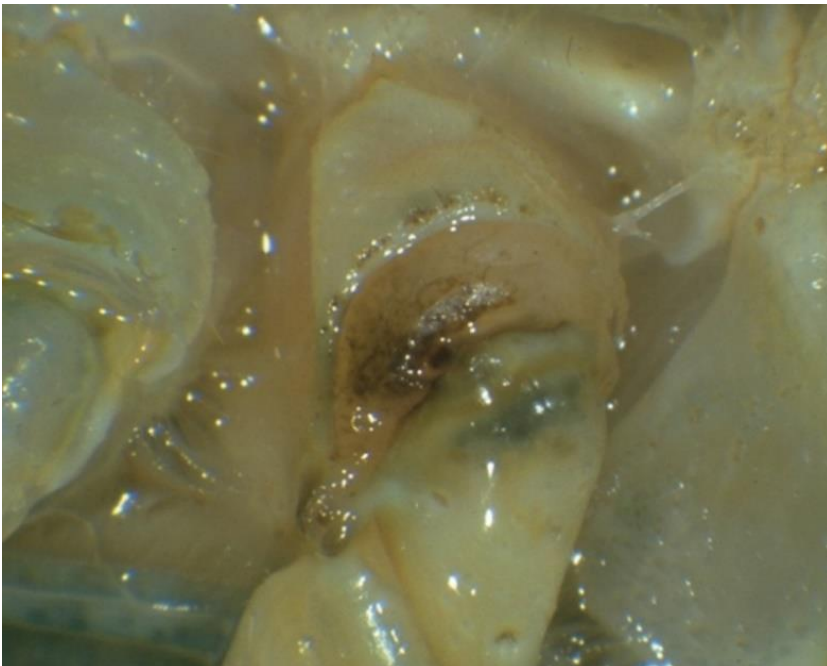Figure 238 Signs of crayfish plague in body of susceptible stone crayfish (*Austropotamobius torrentium*)



Note: Typical brown markings on an abdominal segment are caused by infection with *Aphanomyces astaci*. Healthy muscle tissue is present on either side of the affected segment.

Source: D Alderman

Figure 239 Signs of crayfish plague in leg of susceptible stone crayfish (*Austropotamobius torrentium*)



Note: Classic darkening at base of walking legs is caused by infection with *Aphanomyces astaci*.

Source: D Alderman

Signs of disease

Important: Animals with this disease may show one or more of these signs, but the pathogen may still be present in the absence of any signs.

Disease signs at the farm, tank or pond level are:

- high mortality at the time of the initial outbreak (usually near 100%)
- many dead or weak crayfish floating or lying in watercourses or ponds (mortalities may go unnoticed in the wild)
- crayfish in open water during daylight hours
- unsteady and raised gait ('walking on stilts')
- weakened, rapid tail escape response
- crayfish unable to remain upright (more evident when out of water)
- progressive paralysis
- crayfish trying to scratch or pinch themselves (occasionally seen).
- Gross pathological signs are:
 - fungal growth on soft, non-calcified parts of the carapace
 - brown or black spots on the carapace, where fungal hyphae proliferate
 - fine black lines on the soft shell underneath the tail
 - melanised (black) shell in chronically infected individuals
 - death occurring within days or weeks of the initial infection (particularly in European crayfish, *Astacus* sp.)
 - white and necrotic musculature in the tail.
- Microscopic pathological signs are:
 - aseptate hyphae on the cuticle.

Disease agent

Crayfish plague is caused by infection with the oomycete *Aphanomyces astaci*. Although previously regarded as a fungus, the genus *Aphanomyces* is now classified with diatoms and brown algae in a group called Stramenopiles or Chromista. This pathogen is known to occur in freshwater only.

Host range

Table 72 Species known to be susceptible to crayfish plague

Common name	Scientific name
Asian freshwater shrimp ^a	<i>Macrobrachium dayanum</i>
Chinese mitten crab ^a	<i>Eriocheir sinensis</i>
Crayfish (native to Europe) ^a	<i>Astacus</i> spp.
Crayfish (native to North America) ^a	<i>Orconectes</i> spp.
European river crab	<i>Potamon potamios</i>
Freshwater crayfish ^a	<i>Cherax</i> spp.
Giant crayfish (native to Australia)	<i>Astacopsis</i> spp.
Giant Tasmanian crayfish	<i>Astacopsis gouldi</i>
Gippsland spiny crayfish	<i>Euastacus kershawi</i>
Japanese crayfish ^a	<i>Cambaroides japonicus</i>
Louisiana red swamp crayfish ^a	<i>Procambarus clarkii</i>
Marbled crayfish ^a	<i>Procambarus fallax. f. virginalis</i>
Noble crayfish ^a	<i>Astacus astacus</i>
Redclaw crayfish ^a	<i>Cherax quadricarinatus</i>
Signal crayfish ^a	<i>Pacifastacus leniusculus</i>
Smooth crayfish (native to Australia)	<i>Geocherax</i> spp.
Spiny crayfish (native to Australia)	<i>Euastacus</i> spp.
Stone crayfish ^a	<i>Austropotamobius torrentium</i>
Turkish crayfish ^a	<i>Astacus leptodactylus</i>
White-clawed crayfish ^a	<i>Austropotamobius pallipes</i>
Yabbies (freshwater, native to Australia) ^a	<i>Cherax destructor</i>

a Naturally susceptible.

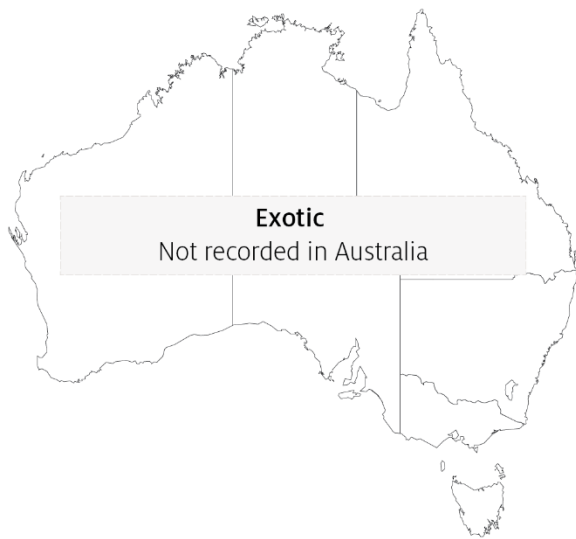Table 73 Non-crustacean vectors of crayfish plague

Common name	Scientific name
Piscivorous birds	Various genera and species

Presence in Australia

Exotic disease—not recorded in Australia.

Map 49 Presence of crayfish plague, by jurisdiction



Epidemiology

- Mortalities of up to 100% have occurred in Europe, with local extinction of susceptible populations.
- North American crayfish (signal crayfish, Louisiana red swamp crayfish, *Orconectes* sp.) can be infected without showing clinical signs or succumbing to the disease. This allows them to become carriers of the disease agent and a source of transmission to less resistant species of crayfish.
- The disease was introduced into Europe by American freshwater crayfish and has decimated European crayfish stocks (wild and cultured). Until recently, there was no evidence of development of resistance to the disease among European species. There is now evidence of latent subclinical *Aphanomyces astaci* infections in some European crayfish, including noble crayfish (*Astacus astacus*) and Turkish crayfish (*Astacus leptodactylus*).
- Crayfish plague can occur at any time of year but is more likely in the summer months.
- Death occurs between 5 and 50 days (or more) from initial infection, depending on water temperature and initial number of zoospores. As little as one zoospore may be sufficient to initiate a lethal infection in susceptible crayfish species.
- *Aphanomyces astaci* releases motile zoospores directly to the water column when crayfish die. This is the primary transmission mechanism; motile zoospores of *A. astaci* swim actively in the water column and show positive movement towards other crayfish.
- Zoospores emerging from spores can swim for up to 5 days at 20°C but are capable of encystment and re-emergence up to 3 times, extending the period of their infective viability to several weeks.
- Translocation and migration of fish, birds and other wildlife can allow them to act as vectors, transporting the disease agent into previously unexposed waters.

- *Aphanomyces astaci* can be introduced to a new susceptible crayfish population on contaminated ropes, traps, fishing gear, boots, nets and other equipment.
- Infection with *A. astaci* may be suspected when mortalities are observed to be limited to highly susceptible species of freshwater crayfish (where all other flora and fauna, particularly other crustaceans, are normal and healthy).
- The known host range for *A. astaci* has expanded as more ornamental crayfish species are examined. There have been several instances where Australian crayfish species have been infected with *A. astaci* after intermingling with North American or European crayfish species within the ornamental trade.

Differential diagnosis

The list of [similar diseases](#) in the next section refers only to the diseases covered by this field guide. Gross pathological signs may also be representative of diseases not included in this guide. Do not rely on gross signs to provide a definitive diagnosis. Use them as a tool to help identify the listed diseases that most closely account for the observed signs.

Similar diseases

None of the other diseases in this field guide result in the rapid mortality of crayfish or other gross signs of crayfish plague. In Australia, infection with the microbial parasite *Thelohania* (or porcelain disease) may cause similar gross signs. Initial misdiagnosis has occurred when pollution has resulted in mortality of aquatic crustaceans where other species have survived. In a few cases, examination by light microscopy can further define a diagnosis. However, further laboratory examination is always required for a definitive diagnosis.

Sample collection

Only trained personnel should collect samples. Using only gross pathological signs to differentiate between diseases is not reliable, and some aquatic animal disease agents pose a risk to humans. If you are not appropriately trained, phone your state or territory hotline number and report your observations. If you have to collect samples, the agency taking your call will advise you on the appropriate course of action. Local or district fisheries or veterinary authorities may also advise on sampling.

Emergency disease hotline

See something you think is this disease? Report it. Even if you're not sure.

Call the Emergency Animal Disease Watch Hotline on **1800 675 888**. They will refer you to the right state or territory agency.

Further reading

CEFAS International Database on Aquatic Animal Diseases [Crayfish plague](#)

Department of Agriculture [AQUAVETPLAN disease strategy manual: Crayfish plague](#)

World Organisation for Animal Health [Manual of diagnostic tests for aquatic animals](#)

***Monodon* slow growth syndrome (MSGs)**

Including infection with Laem-Singh virus (LSNV)

Exotic disease

Figure 240 Deformity of *Penaeus monodon* with MSGS



Note: Stunted growth and bamboo shaped abdominal segments.

Source: DV Lightner

Figure 241 Hepatopancreas of *Penaeus monodon* with MSGS



Note: Carapace lifted to show abnormal hepatopancreas.

Source: DV Lightner

Figure 242 Unusual markings on carapace of *Penaeus monodon* with MSGS



Note: Bright yellow markings on near legs.
Source: DV Lightner

Signs of disease

Important: Animals with this disease may show one or more of these signs, but the pathogen may still be present in the absence of any signs.

Disease signs at the farm, tank or pond level are:

- abnormally slow growth, resulting in irregularly sized prawns
- low average daily weight gain of less than 0.1g/day at 4 months of age.
- Gross pathological signs are:
- unusually dark colour
- unusually bright yellow markings
- brittle antennae
- bamboo-shaped abdominal segments.

There are no definitive microscopic pathological signs.

Disease agent

MSGS is a disease associated with the Laem-Singh virus (LSNV). The complete aetiology for MSGS is uncertain and there is no clear case definition for this syndrome. A working case definition for surveillance and data gathering purposes is listed in the [epidemiology](#) section. A key component is the positive detection of LSNV by RT-PCR; LSNV is considered a necessary but insufficient component cause. Known pathogens are unlikely to be the cause of MSGS. Previous trials have indicated that a filterable infectious agent is involved.

Host range

Table 74 Species known to be susceptible to MSGS

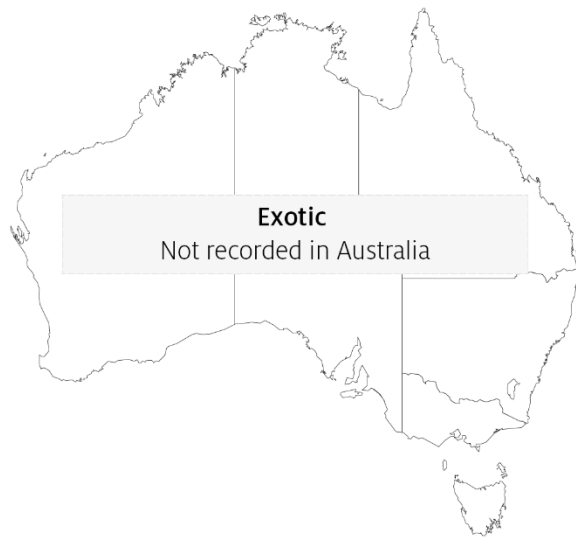Common name	Scientific name
Black tiger prawn	<i>Penaeus monodon</i>

a Naturally susceptible.

Presence in Australia

Exotic disease—not recorded in Australia.

Map 50 Presence of MSGS, by jurisdiction



Epidemiology

- The cause of MSGS is uncertain, but a working case definition allows for suspected case data to be collected if the population:
 - tests positive for Laem-Singh virus
 - has a coefficient of variation of more than 35% by weight
 - is free from hepatopancreatic parvovirus infection or any other hepatopancreatic infection
 - shows 3 of the signs of disease listed here.
- In countries where the Pacific white shrimp (*Penaeus (Litopenaeus) vannamei*) has already been introduced, Pacific white shrimp and black tiger prawns (*Penaeus monodon*) should be reared separately. This is particularly important at the maturation and hatchery phases.

Differential diagnosis

The list of [similar diseases](#) in the next section refers only to the diseases covered by this field guide. Gross pathological signs may also be representative of diseases not included in this guide. Do not rely on gross signs to provide a definitive diagnosis. Use them as a tool to help identify the listed diseases that most closely account for the observed signs.

Similar diseases

No diseases listed in this field guide are similar to *Monodon* slow growth syndrome.

Sample collection

Only trained personnel should collect samples. Using only gross pathological signs to differentiate between diseases is not reliable, and some aquatic animal disease agents pose a risk to humans. If you are not appropriately trained, phone your state or territory hotline number and report your observations. If you have to collect samples, the agency taking your call will advise you on the appropriate course of action. Local or district fisheries or veterinary authorities may also advise on sampling.

Emergency disease hotline

See something you think is this disease? Report it. Even if you're not sure.

Call the Emergency Animal Disease Watch Hotline on **1800 675 888**. They will refer you to the right state or territory agency.

Further reading

Network of Aquaculture Centres in Asia-Pacific [‘Monodon’ slow growth syndrome and Laem-Singh virus retinopathy: disease card](#)

Poornima, M, Seetang-Nun, Y, Alavandi, SV & Dayal, J 2012, [Laem-Singh virus: A probable etiological agent associated with Monodon slow growth syndrome in farmed black tiger shrimp \(*Penaeus monodon*\)](#), *Indian Journal of Virology*, vol. 23.

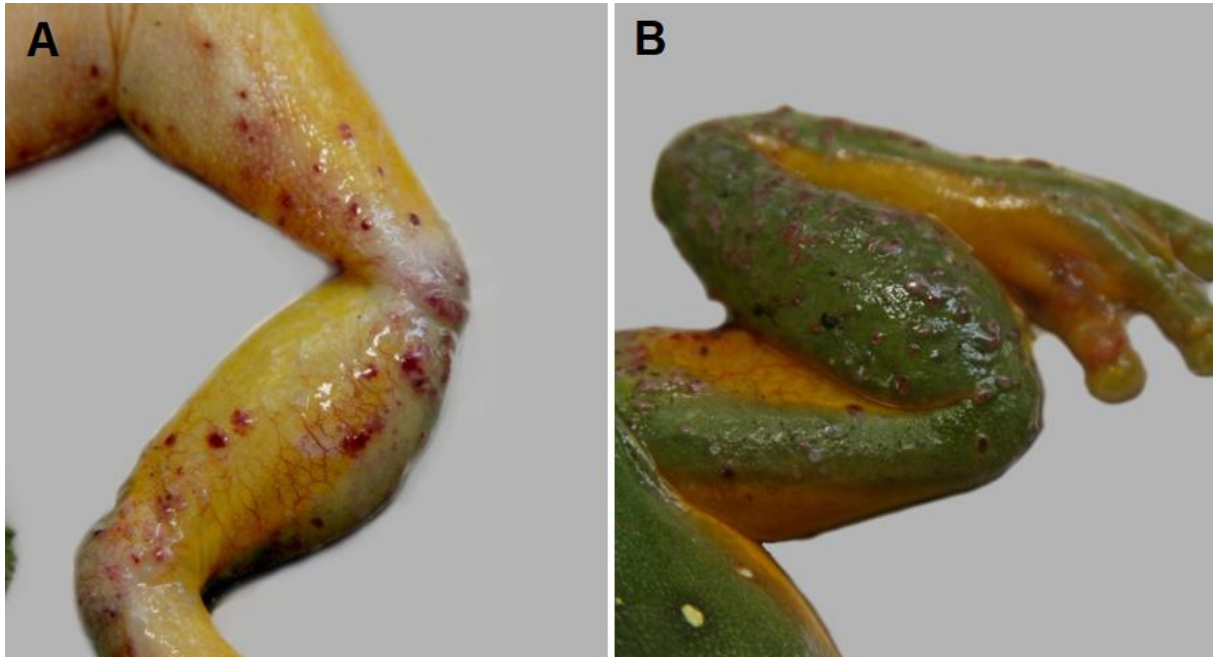5. Diseases of amphibians

Viral diseases of amphibians

Infection with ranavirus

Also known as frog virus 3 (FV-3), Bohle iridovirus (BIV), *Ambystoma tigrinum* virus (ATV), and Mahaffey Road virus (MHRV)

Figure 243 Hindlimb of magnificent tree frog (*Litoria splendida*) infected with Mahaffey Road virus



Note: Haemorrhagic skin papules and subcutaneous oedema of the ventral surface (A). Skin papules and erosions on the dorsal surface (B).

Source: Ian Jerrett

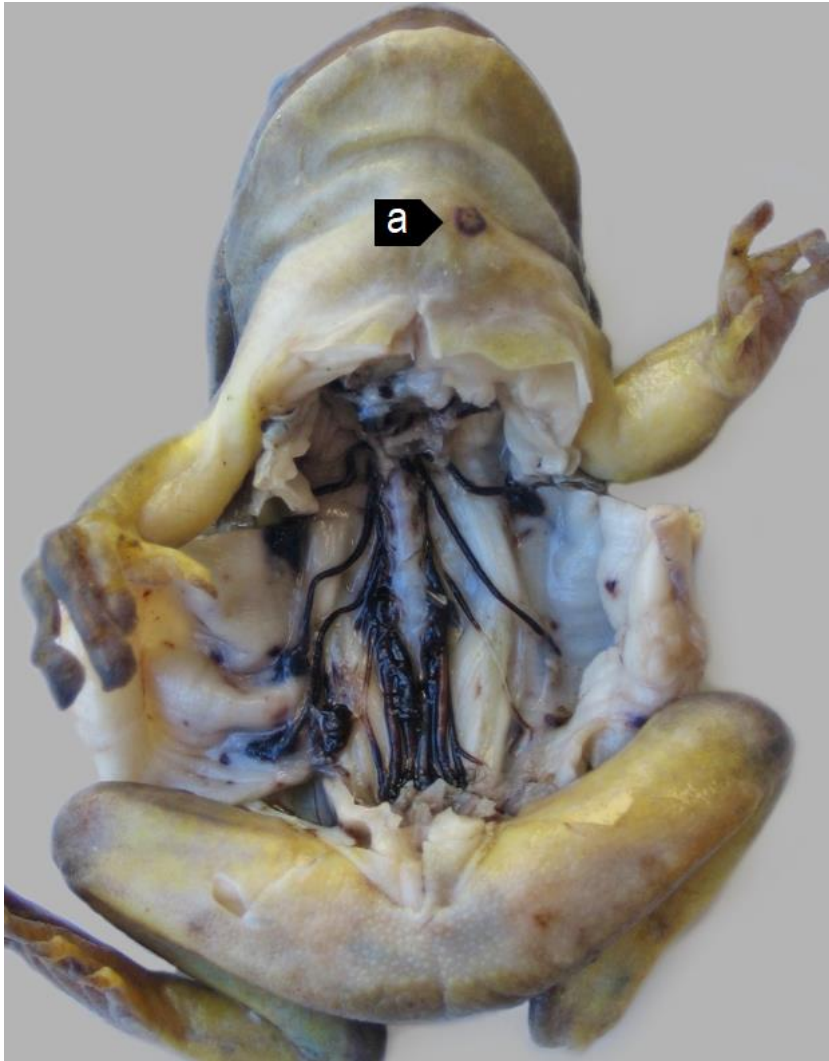
Figure 244 Ornate burrowing frog (*Platyplectrum ornatus*) metamorphs infected with Bohle iridovirus



Note: Varying levels of ascites.

Source: R Speare

Figure 245 Green tree frog (*Litoria caerulea*) infected with Mahaffey Road virus



Note: Haemorrhagic perineural tissue and spinal nerves together with petechiation of the parietal coelomic serosa. A skin ulcer (a) is evident on the ventral neck.

Signs of disease

Important: Animals with this disease may show one or more of these signs, but the pathogen may still be present in the absence of any signs.

Disease signs at the farm, tank or pond level are:

- erratic swimming
- lethargy
- loss of equilibrium
- buoyancy problems
- morbidity
- rapid severe mortality events.

Gross pathological signs are:

- poor body condition
- lordosis (abnormal forward curvature of the spine).

In tadpoles and metamorphs, additional gross pathological signs are:

- ascites (free fluid in the abdominal cavity)
- generalised oedema (fluid swelling) of tissues
- focal haemorrhages.

In adults, additional gross pathological signs are:

- skin ulcers, papules and/or erosions
- focal and systematic haemorrhages
- enlargement of the spleen or liver
- oedema of subcutaneous tissue (particularly around the jaw and head, with the tongue protruding).

Microscopic pathological signs are:

- severe renal, pulmonary, hepatic, splenic and haematopoietic necroses and haemorrhages
- basophilic intracytoplasmic inclusion bodies
- erosion, ulceration and hyperplasia of epithelial epidermal cells.

Disease agent

This disease is caused by infection with members of the genus *Ranavirus* (family *Iridoviridae*). Viruses infecting amphibians include frog virus 3 (FV-3), Bohle iridovirus (BIV), *Ambystoma tigrinum* virus (ATV), and Mahaffey Road virus (MHRV). There are many other tentative species in this genus. Bohle iridovirus and Mahaffey Road virus are known from northern Australia in native frogs and cane toads.

Host range

Amphibians (all members of the class Amphibia) are considered to be susceptible to infection with ranavirus. Natural infections are known from most of the major families of the orders Anura (frogs and toads) and Caudata (salamanders, newts and sirens).

Infection with ranaviruses in fish and reptiles can result in asymptomatic infections through to epizootics, depending on species, stress and environmental factors.

In challenge experiments, species acutely susceptible to Bohle iridovirus were:

- juvenile green tree frogs (*Litoria caerulea*)
- striped burrowing frogs (*Cyclorana alboguttata*)
- short-footed frogs (*Cyclorana brevipes*)
- red-backed toadlets (*Pseudophryne coriacea*).

Species less susceptible in trials were:

- adult red tree frogs (*Litoria rubella*)
- bumpy rocketfrog (*Litoria inermis*)
- adult green tree frogs (*Litoria caerulea*)
- ornate nursery frogs (*Cophixalus ornatus*)
- sharp-snouted day frogs (*Taudactylus acutirostris*)
- cane toads (*Bufo marinus*).

Table 75 Species known to be susceptible to ranavirus

Common name	Scientific name
Frogs and toads	Order Anura
Bumpy rocket frog ^a	<i>Litoria inermis</i>
Cane toad ^a	<i>Rhinella marina</i>
Great barred frog	<i>Mixophyes fasciolatus</i>
Green tree frog ^a	<i>Litoria caerulea</i>
Magnificent tree frog ^a	<i>Litoria splendida</i>
Ornate burrowing frog ^a	<i>Platyplectrum ornatus</i>
Ornate nursery frog ^a	<i>Cophixalus ornatus</i>
Red tree frog	<i>Litoria rubella</i>
Red-backed toadlet ^a	<i>Pseudophryne coriacea</i>
Sharp-snouted day frog ^a	<i>Taudactylus acutirostris</i>
Short-footed frog	<i>Cyclorana brevipes</i>
Striped burrowing frog ^a	<i>Cyclorana alboguttata</i>
Salamanders newts and sirens	Order Caudata
Alpine newt	<i>Ichthyosaura alpestris</i>
Blue tailed fire belly newt	<i>Cynops cyanurus</i>
Chiang Mai crocodile newt	<i>Tylototriton uyenoii</i>
Chinese firebelly newt	<i>Cynops orientalis</i>
Clouded salamander	<i>Hynobius nebulosus</i>
Eastern newt	<i>Notophthalmus viridescens</i>
European cave salamander	<i>Speleomantes</i> spp.
Fire salamander	<i>Salamandra salamandra</i>
French cave salamander	<i>Hydromantes strinatii</i>
Italian newt	<i>Lissotriton italicus</i>
Japanese clawed salamander	<i>Onychodactylus japonicas</i>
Japanese fire belly newt	<i>Cynops pyrrhogaster</i>
Lesser siren	<i>Siren intermedia</i>
North African fire salamander	<i>Salamandra algira</i>

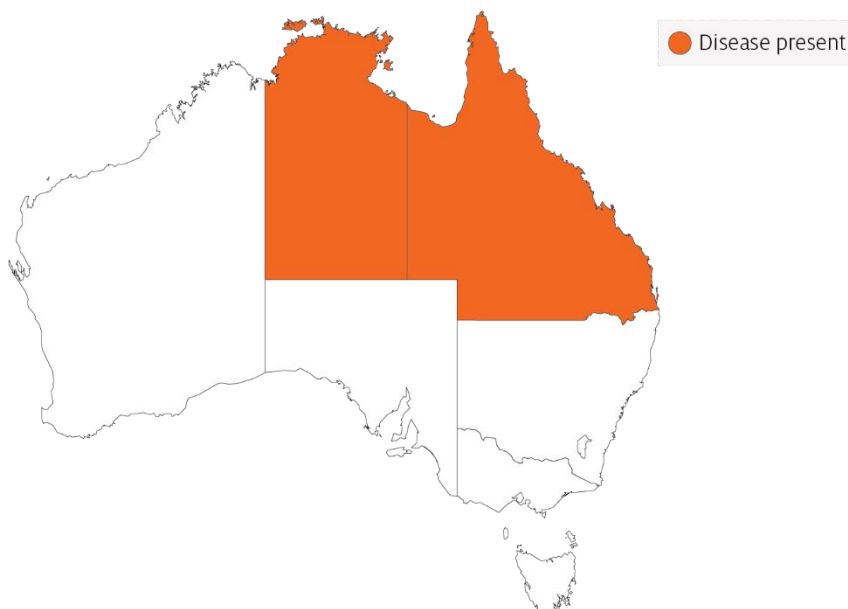
Common name	Scientific name
Northern crested newt	<i>Triturus cristatus</i>
Northern spectacled salamander	<i>Salamandrina perspicillata</i>
Rough skinned newt	<i>Taricha granulosa</i>
Sardinian brook salamander	<i>Euproctus platycephalus</i>
Siberian salamander	<i>Salamandrella keyserlingii</i>
Smooth newt	<i>Lissotriton vulgaris</i>
Spanish ribbed newt	<i>Pleurodeles waltl</i>
Sword tailed newt	<i>Cynops ensicauda</i>
Vietnamese crocodile newt	<i>Tylototriton vietnamensis</i>
Vietnamese salamander	<i>Paramesotriton deloustali</i>
Wenxian knobby newt	<i>Tylototriton wenxianensis</i>
Yellow spotted newt	<i>Neurergus crocatus</i>
Zeigler's crocodile newt	<i>Tylototriton zieglerei</i>

a Naturally susceptible. Note: other species likely to be susceptible or shown to be experimentally susceptible.

Presence in Australia

Infection with ranavirus has been officially reported in Australia. Bohle iridovirus was originally isolated from tadpoles of ornate burrowing frogs (*Platyplectrum ornatus*) in far north Queensland. It has since been isolated from moribund green tree frogs and captive juvenile red-backed toadlets. Another ranavirus, Mahaffey Road virus, was reported from moribund tree frogs in Darwin, Northern Territory. There is serological evidence of ranavirus infection in cane toads across northern Australia.

Map 51 Presence of ranavirus, by jurisdiction



Epidemiology

- Two syndromes in frogs are associated with ranavirus infection: ulcerative syndrome and haemorrhagic syndrome.
- The most common presentation is a rapid, severe mortality event with death due to peracute systemic haemorrhagic disease. However, in Australia, morbidity is more common.
- Mortality and morbidity vary from species to species (0-100%), and may be variable depending on virus type, and age and health status of the host.
- Horizontal transmission occurs via contaminated water, animal-to-animal contact and predation or cannibalism.
- These viruses can be spread between widely separated river systems and impoundments. This suggests viral persistence and the existence of transmission mechanisms other than direct horizontal transmission.
- Vertical transmission is considered likely, but has not been experimentally documented.
- Possible vectors include nets, boats and other equipment, or amphibians used for bait by recreational fishers. Birds are potential mechanical vectors.
- Temperature is considered a likely factor influencing disease outbreaks, with the prevalence or severity of outbreaks greater during warmer months.

Differential diagnosis

The list of [similar diseases](#) in the next section refers only to the diseases covered by this field guide. Gross pathological signs may also be representative of diseases not included in this guide. Do not rely on gross signs to provide a definitive diagnosis. Use them as a tool to help identify the listed diseases that most closely account for the observed signs.

Similar diseases

No diseases in this field guide are similar to infection with ranavirus.

Sample collection

Only trained personnel should collect samples. Using only gross pathological signs to differentiate between diseases is not reliable, and some aquatic animal disease agents pose a risk to humans. If you are not appropriately trained, phone your state or territory hotline number and report your observations. If you have to collect samples, the agency taking your call will advise you on the appropriate course of action. Local or district fisheries or veterinary authorities may also advise on sampling.

Emergency disease hotline

See something you think is this disease? Report it. Even if you're not sure.

Call the Emergency Animal Disease Watch Hotline on **1800 675 888**. They will refer you to the right state or territory agency.

Further reading

Wildlife Health Australia [Ranaviral disease in wild Australian amphibians](#)

World Organisation for Animal Health [Manual of Diagnostic Tests for Aquatic Animals](#)

Other diseases of amphibians

Infection with *Batrachochytrium dendrobatidis* (Bd)

Also known as chytridiomycosis, cutaneous chytridiomycosis and amphibian chytrid fungus

Figure 246 Great barred frog (*Mixophyes fasciolatus*) with severe infection with *Batrachochytrium dendrobatidis*



Note: Pieces of shedding skin on the body.

Source: L Berger

Signs of disease

Important: Animals with this disease may show one or more of these signs, but the pathogen may still be present in the absence of any signs.

Disease signs at the farm, tank or pond level are:

- lethargy
- ataxia
- paralysis
- loss of flee response
- loss of righting reflex
- abnormal sitting posture
- tetanic spasms
- nocturnal species emerging during daylight
- burrowing species remaining outside of burrows.

Gross pathological signs are:

- erythema (redness) of the ventral surface
- lesions ranging from no obvious change to sloughing (as small flakes of skin).

Gross changes to the skin may be seen in severe infections. However, these are not specific to the disease.

Microscopic pathological signs are:

- loss of pigmented jaw sheaths and teeth rows in tadpoles' mouthparts
- zoosporangia in the outer epidermal layers that are seen on fresh pieces of shed skin and in histological sections
- hyperkeratosis of the epidermis in areas where zoosporangia occur.

Disease agent

Chytridiomycosis is caused by infection with the parasitic chytrid fungus, *Batrachochytrium dendrobatidis* (Bd), of the class Chytridiomycota, order Rhizophydiales. Recent evidence suggests that *B. dendrobatidis* originated in Southeast Asia and was spread worldwide through international trade of amphibians.

Host range

Most, if not all, amphibians appear to be susceptible to infection with *B. dendrobatidis*. This includes all members of the orders Anura (frogs and toads), Caudata (including salamanders, newts and sirens) and Gymnophiona (caecilians).

Amphibian species differ in degree of susceptibility; some are naturally resistant, while others are extremely susceptible with *B. dendrobatidis* infection, greatly increasing extinction risk in some isolated populations. In Australia, *B. dendrobatidis* has been directly implicated in the extinction of at least four native frog species and the decline of many others.

Table 76 Species known to be susceptible to *Batrachochytrium dendrobatidis*

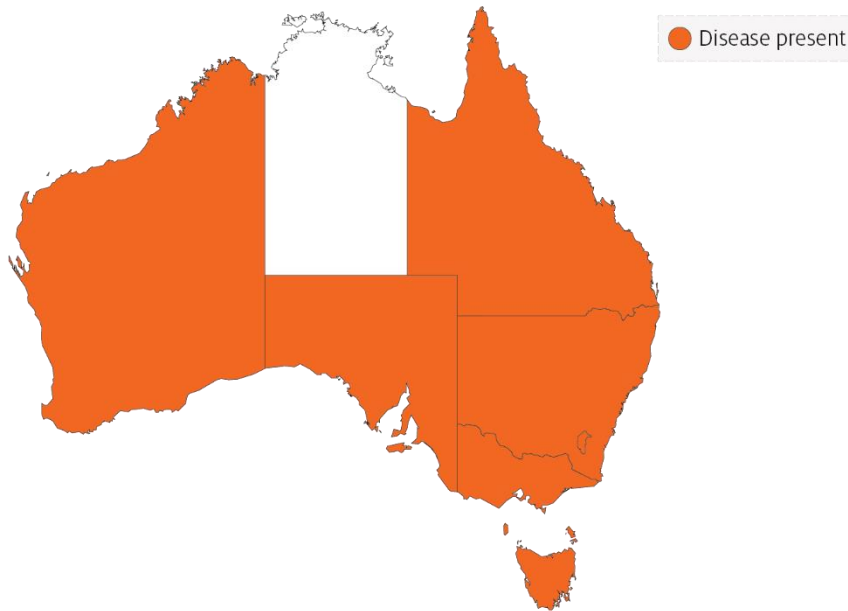
Common name	Scientific name
Caecilians	Order Gymnophiona
Frogs and toads	Order Anura
Bumpy rocket frog	<i>Litoria inermis</i>
Cane toad	<i>Bufo marinus</i>
Great barred frog	<i>Mixophyes fasciolatus</i>
Green tree frog	<i>Litoria caerulea</i>
Magnificent tree frog	<i>Litoria splendida</i>
Ornate burrowing frog	<i>Limnodynastes ornatus</i>
Ornate nursery frog	<i>Cophixalus ornatus</i>
Red tree frog	<i>Litoria rubella</i>
Red-backed toadlet	<i>Pseudophryne coriacea</i>
Sharp-snouted day frog	<i>Taudactylus acutirostris</i>
Short-footed frog	<i>Cyclorana brevipes</i>
Striped burrowing frog	<i>Cyclorana alboguttata</i>
Salamanders newts and sirens	Order Caudata
Alpine newt	<i>Ichthyosaura alpestris</i>
Blue tailed fire belly newt	<i>Cynops cyanurus</i>
Chiang Mai crocodile newt	<i>Tylototriton uyenoi</i>
Chinese firebelly newt	<i>Cynops orientalis</i>

Common name	Scientific name
Clouded salamander	<i>Hynobius nebulosus</i>
Eastern newt	<i>Notophthalmus viridescens</i>
European cave salamander	<i>Speleomantes</i> spp.
Fire salamander	<i>Salamandra salamandra</i>
French cave salamander	<i>Hydromantes strinatii</i>
Italian newt	<i>Lissotriton italicus</i>
Japanese clawed salamander	<i>Onychodactylus japonicas</i>
Japanese fire belly newt	<i>Cynops pyrrhogaster</i>
Lesser siren	<i>Siren intermedia</i>
North African fire salamander	<i>Salamandra algira</i>
Northern crested newt	<i>Triturus cristatus</i>
Northern spectacled salamander	<i>Salamandrina perspicillata</i>
Rough skinned newt	<i>Taricha granulosa</i>
Sardinian brook salamander	<i>Euproctus platycephalus</i>
Siberian salamander	<i>Salamandrella keyserlingii</i>
Smooth newt	<i>Lissotriton vulgaris</i>
Spanish ribbed newt	<i>Pleurodeles waltl</i>
Sword tailed newt	<i>Cynops ensicauda</i>
Vietnamese crocodile newt	<i>Tylototriton vietnamensis</i>
Vietnamese salamander	<i>Paramesotriton deloustali</i>
Wenxian knobby newt	<i>Tylototriton wenxianensis</i>
Yellow spotted newt	<i>Neurergus crocatus</i>
Zeiglers crocodile newt	<i>Tylototriton zieglerei</i>

Presence in Australia

Infection with *B. dendrobatidis* has been officially reported across Australia in Queensland, New South Wales, the Australian Capital Territory, Victoria, South Australia, Tasmania and Western Australia. It does not occur in arid inland areas.

Map 52 Presence of *Batrachochytrium dendrobatidis*, by jurisdiction



Epidemiology

- All age classes, except eggs, are known to be susceptible to infection. Mortality has only rarely been reported in tadpoles.
- *Batrachochytrium dendrobatidis* infects only keratinised tissues (skin of metamorphosed amphibians or the mouthparts of tadpoles). In contrast, *B. salamandrivorans* in salamanders infects only epidermal tissues, causing ulceration.
- Optimal temperature for growth of the fungus is between 17°C and 25°C. The sporangia die in temperatures of 32°C or higher. The pathogen can persist in very low host densities.
- Incubation times vary from about 14 to more than 70 days. Mortalities usually occur within 2 to 3 days of the first clinical signs and have approached 100% in some Australian amphibians.
- Horizontal transmission is via waterborne, motile zoospores and is likely to be by direct animal-to-animal contact. Vertical transmission via eggs has not been demonstrated.
- Outbreaks may be associated with seasons (cooler months), altitude (most declines are generally restricted to high-altitude populations) and breeding habitat.
- Large-scale mortality of newly metamorphosed amphibians may indicate infection, as some species appear to be most susceptible at this time.

Differential diagnosis

The list of [similar diseases](#) in the next section refers only to the diseases covered by this field guide. Gross pathological signs may also be representative of diseases not included in this guide. Do not rely on gross signs to provide a definitive diagnosis. Use them as a tool to help identify the listed diseases that most closely account for the observed signs.

Similar diseases

Infection with *Batrachochytrium salamandrivorans*.

Sample collection

Only trained personnel should collect samples. Using only gross pathological signs to differentiate between diseases is not reliable, and some aquatic animal disease agents pose a risk to humans. If you are not appropriately trained, phone your state or territory hotline number and report your observations. If you have to collect samples, the agency taking your call will advise you on the appropriate course of action. Local or district fisheries or veterinary authorities may also advise on sampling.

Emergency disease hotline

See something you think is this disease? Report it. Even if you're not sure.

Call the Emergency Animal Disease Watch Hotline on **1800 675 888**. They will refer you to the right state or territory agency.

Further reading

Department of the Environment and Energy [Infection of amphibians with chytrid fungus resulting in chytridiomycosis \(2016\)](#)

Imperial College London [Global Bd mapping project](#)

World Organisation for Animal Health [Manual of Diagnostic Tests for Aquatic Animals](#)

Infection with *Batrachochytrium salamandrivorans* (Bsal)

Also known as Bsal chytridiomycosis and salamander chytrid disease

Exotic disease

Figure 247 Adult fire salamander (*Salamandra salamandra*) infected by *Batrachochytrium salamandrivorans*



Note: Lesions consist of multifocal erosions with a black margin and dysecdysis.

Source: F Pasmans

Signs of disease

Important: Animals with this disease may show one or more of these signs, but the pathogen may still be present in the absence of any signs.

Disease signs at the farm, tank or pond level are:

- anorexia
- apathy
- ataxia
- high levels of mortality at temperatures below 25°C.

Gross pathological signs are:

- discolouration and/or roughening of the skin, with excessive skin sloughing
- focal or multifocal skin ulcerations with significant degradation of the epidermis, impairment of vital skin functions, and subsequent death.

Microscopic pathological signs are:

- lesions consisting of focal necrotic epidermal ulcerations with high numbers of colonial thalli of *B. salamandrivorans*, bordered by keratinocytes containing intracellular fungal thalli.

Disease agent

Bsal chytridiomycosis is caused by infection with the parasitic chytrid fungus, *Batrachochytrium salamandrivorans* (Bsal) of the class Chytridiomycota, order Rhizophydiales. *B. salamandrivorans* was first detected in wild salamanders in the Netherlands and Belgium in 2013/14, and was subsequently found in captive salamanders and newts in Germany, and the UK. Investigations suggest *B. salamandrivorans* probably originated in southeast Asia, where it has been found in Japan, Thailand, Vietnam and China.

Host range

A range of salamanders, newts and sirens (order Caudata) appear to be highly susceptible to infection with *B. salamandrivorans*. Members of the families Salamandridae, Plethodontidae, Hynobiidae and Sirenidae can carry the pathogen, often without showing any clinical signs. Species endemic to Asia appear to be more resistant to disease but may be asymptomatic carriers of the fungus.

Table 77 Species known to be susceptible to *Batrachochytrium salamandrivorans*

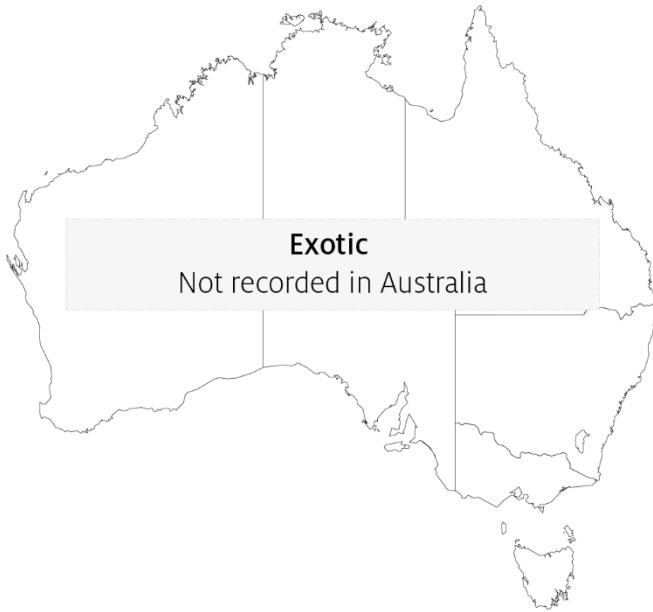Common name	Scientific name
Alpine newt	<i>Ichthyosaura alpestris</i>
Blue tailed fire belly newt	<i>Cynops cyanurus</i>
Chiang Mai crocodile newt	<i>Tylototriton uyenoi</i>
Clouded salamander	<i>Hynobius nebulosus</i>
Eastern newt	<i>Notophthalmus viridescens</i>
European cave salamanders	<i>Speleomantes</i> spp.
Fire salamander	<i>Salamandra salamandra</i>
French cave salamander	<i>Hydromantes strinatii</i>
Italian newt	<i>Lissotriton italicus</i>
Japanese clawed salamander	<i>Onychodactylus japonicas</i>
Japanese fire belly newt	<i>Cynops pyrrhogaster</i>
Lesser siren	<i>Siren intermedia</i>
North African fire salamander	<i>Salamandra algira</i>
Northern crested newt	<i>Triturus cristatus</i>
Northern spectacled salamander	<i>Salamandrina perspicillata</i>
Rough skinned newt	<i>Taricha granulosa</i>
Sardinian brook salamander	<i>Euproctus platycephalus</i>
Siberian salamander	<i>Salamandrella keyserlingii</i>
Smooth newt	<i>Lissotriton vulgaris</i>
Spanish ribbed newt	<i>Pleurodeles waltl</i>
Sword tailed newt	<i>Cynops ensicauda</i>
Vietnamese crocodile newt	<i>Tylototriton vietnamensis</i>
Vietnamese salamander	<i>Paramesotriton deloustali</i>
Wenxian knobby newt	<i>Tylototriton wenxianensis</i>
Yellow spotted newt	<i>Neurergus crocatus</i>

Common name	Scientific name
Zeigler's crocodile newt	<i>Tylototriton ziegleri</i>

Presence in Australia

Exotic disease—not recorded in Australia.

Map 53 Presence of *Batrachochytrium salamandrivorans*, by jurisdiction



Epidemiology

- *Batrachochytrium salamandrivorans* infects epidermal tissue causing multifocal ulcerations.
- Optimal temperature for growth of the fungus is 15°C and optimal salinity is 0ppt (freshwater). Desiccation is fatal for all life stages of the fungus.
- Horizontal transmission is via waterborne, motile zoospores and is likely to be by direct animal-to-animal contact.
- Mortality occurs 12 to 18 days after exposure to infective zoospores at 15°C, and within 22 to 27 days when susceptible animals are placed in contact with infected animals.
- Zoospores can remain viable in water for up to 3 weeks.
- *Batrachochytrium salamandrivorans* has been eliminated from wild salamanders by exposure to greater than 25°C for at least 10 days, or a synergistic treatment with antifungals.
- Disease outbreaks in wild populations may be seasonal (during the cooler months), and can cause significant population declines that may lead to extinction.

Differential diagnosis

The list of [similar diseases](#) in the next section refers only to the diseases covered by this field guide. Gross pathological signs may also be representative of diseases not included in this guide. Do not rely on gross signs to provide a definitive diagnosis. Use them as a tool to help identify the listed diseases that most closely account for the observed signs.

Similar diseases

Infection with *Batrachochytrium dendrobatidis*.

Sample collection

Only trained personnel should collect samples. Using only gross pathological signs to differentiate between diseases is not reliable, and some aquatic animal disease agents pose a risk to humans. If you are not appropriately trained, phone your state or territory hotline number and report your observations. If you have to collect samples, the agency taking your call will advise you on the appropriate course of action. Local or district fisheries or veterinary authorities may also advise on sampling.

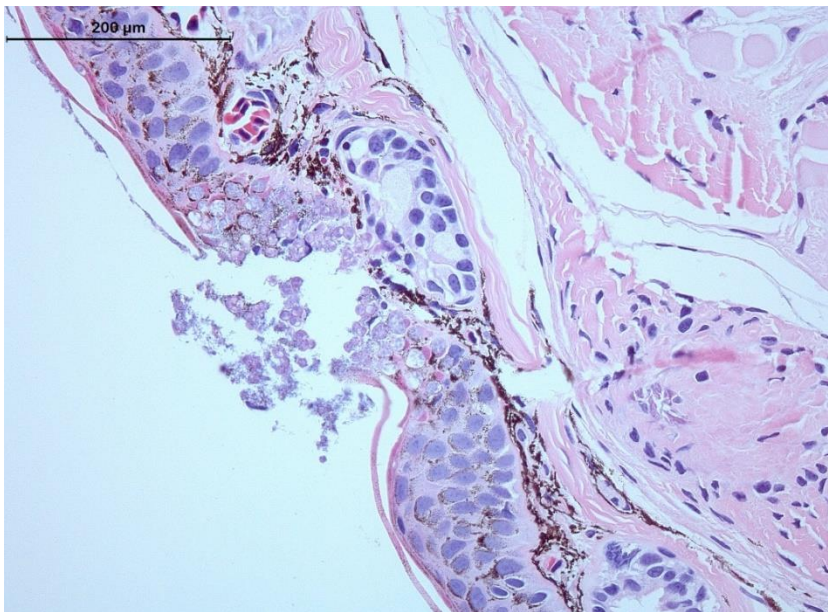
Emergency disease hotline

See something you think is this disease? Report it. Even if you're not sure.

Call the Emergency Animal Disease Watch Hotline on **1800 675 888**. They will refer you to the right state or territory agency.

Microscope images

Figure 248 Hematoxylin and eosin stained section of skin of fire salamander (*Salamandra salamandra*) infected by *Batrachochytrium salamandrivorans*



Note: Histopathological lesions consist of multifocal epidermal erosions, with numerous colonial chytrid thalli inside epidermal cells and bacterial overgrowth. Scale bar = 200μm

Source: A Martel

Further reading

European Food Safety Authority [Scientific and technical assistance concerning the survival, establishment and spread of 'Batrachochytrium salamandrivorans' \(Bsal\) in the EU](#)

World Organisation for Animal Health, ['Batrachochytrium salamandrivorans' disease card](#)

Appendix A: Species' common and scientific names

Finfish

Table A1 Common and scientific names of non-salmonid finfish

Common name	Scientific name
Freshwater bream	<i>Abramis brama</i>
Yellowfin bream	<i>Acanthopagrus australis</i>
Yellowfin seabream	<i>Acanthopagrus latus</i>
Black sea bream or black porgy	<i>Acanthopagrus schlegelii</i>
Convict surgeonfish	<i>Acanthurus triostegus</i>
Siberian sturgeon	<i>Acipenser baerii</i>
Russian sturgeon	<i>Acipenser gueldenstaedtii</i>
Atlantic sturgeon	<i>Acipenser oxyrinchus</i>
White sturgeon	<i>Acipenser transmontanus</i>
Chanda perch	<i>Ambassis agassizii</i>
Rock bass	<i>Ambloplites rupestris</i>
White catfish	<i>Ameiurus catus</i>
Black bullhead or European catfish	<i>Ameiurus melas</i>
Yellow bullhead	<i>Ameiurus natalis</i>
Brown bullhead	<i>Ameiurus nebulosus</i>
Pacific sand lance	<i>Ammodytes hexapterus</i>
Pacific sand eel	<i>Ammodytes personatus</i>
Sand eel	<i>Ammodytes</i> spp.
Lesser sand eel	<i>Ammodytes tobianus</i>
Striped grunter	<i>Amniataba percoides</i>
Climbing perch	<i>Anabas testudineus</i>
Atlantic wolfish	<i>Anarhichas lupus</i>
Spotted wolffish	<i>Anarhichas minor</i>
European eel	<i>Anguilla anguilla</i>
Shortfin eel	<i>Anguilla australis</i>
Japanese eel	<i>Anguilla japonica</i>
American eel	<i>Anguilla rostrate</i>
Toothless catfish	<i>Anodontiglanis dahlia</i>
Sablefish	<i>Anoplopoma fimbria</i>
Dwarf cichlids	<i>Apistogramma</i> spp.
African lampeye killifish	<i>Aplocheilichthys normani</i>
Freshwater drum	<i>Aplodinotus grunniens</i>

Common name	Scientific name
Lesser argentine	<i>Argentina sphyraena</i>
Mulloway	<i>Argyrosomus japonicus</i>
Bighead carp	<i>Aristichthys nobilis</i>
Fork-tailed catfish	<i>Arius</i> spp.
Oscar	<i>Astronotus ocellatus</i>
White seabass	<i>Atractoscion nobilis</i>
Tubesnout	<i>Aulorhynchus flavidus</i>
Tinfoil barb	<i>Barbonymus schwanenfeldii</i>
Silver perch	<i>Bidyanus bidyanus</i>
Silver bream	<i>Blicca bjoerkna</i>
Japanese tilefish	<i>Branchiostegus japonicus</i>
Goldfish or shubunkin	<i>Carassius auratus</i>
Crucian carp	<i>Carassius carassius</i>
Milkfish	<i>Chanos chanos</i>
Golden grey mullet	<i>Chelon auratus</i>
Snapper	<i>Chrysophrys auratus</i>
Cichlids or Tilapias	<i>Cichlidae</i>
Froggatt's catfish	<i>Cinetodus froggatti</i>
Walking catfish	<i>Clarias batrachus</i>
Atlantic herring	<i>Clupea harengus</i>
Pacific herring	<i>Clupea pallasii</i>
Estuary catfish	<i>Cnidoglanis macrocephalus</i>
Thick-lipped gourami	<i>Colisa labiosa</i>
Redbelly tilapia	<i>Coptodon zilli</i>
Bullhead	<i>Cottus gobio</i>
Humpback grouper	<i>Cromileptes altivelis</i>
Goldsinny	<i>Ctenolabrus rupestris</i>
Grass carp	<i>Ctenopharyngodon idella</i>
Shiner perch	<i>Cymatogaster aggregata</i>
Cyprinids	<i>Cyprinidae</i>
Common carp and koi carp	<i>Cyprinus carpio</i>
Sind danio	<i>Danio devario</i>
Zebrafish	<i>Danio rerio</i>
European seabass	<i>Dicentrarchus labrax</i>
Gizzard shad	<i>Dorosoma cepedianum</i>
Glass knifefish	<i>Eigenmannia virescens</i>
Fourbeard rockling	<i>Enchelyopus cimbrius</i>
Shotted halibut	<i>Eopsetta grigorjewi</i>

Common name	Scientific name
White grouper	<i>Epinephelus aeneus</i>
Red-spotted grouper or Hong Kong grouper	<i>Epinephelus akaara</i>
Yellow grouper	<i>Epinephelus awoara</i>
Longtooth grouper	<i>Epinephelus bruneus</i>
Orange-spotted grouper	<i>Epinephelus coioides</i>
Brown marbled grouper	<i>Epinephelus fuscoguttatus</i>
Tiger grouper hybrid	<i>Epinephelus fuscoguttatus</i> × <i>E. lanceolatus</i>
Giant grouper	<i>Epinephelus lanceolatus</i>
Malabar grouper	<i>Epinephelus malabaricus</i>
Dusky grouper	<i>Epinephelus marginatus</i>
Black spot grouper	<i>Epinephelus melanostigma</i>
Six-bar grouper	<i>Epinephelus sexfasciatus</i>
Grouper and estuary cod	<i>Epinephelus</i> spp.
Estuarine rockcod	<i>Epinephelus tauvina</i>
Pike	<i>Esox lucius</i>
Muskellunge	<i>Esox masquinongy</i>
Orange chromide	<i>Etroplus maculatus</i>
Crimson seabream	<i>Evynnis japonica</i>
Yellowback seabream	<i>Evynnis tumifrons</i>
Tropical two-winged flying fish	<i>Exocoetus volitans</i>
Mummichog	<i>Fundulus heteroclitus</i>
Walleye pollock or Alaska pollock	<i>Gadus chalcogramma</i>
Pacific cod	<i>Gadus macrocephalus</i>
Tomcod	<i>Gadus microgadus</i>
Atlantic cod	<i>Gadus morhua</i>
Mountain galaxias	<i>Galaxias olidus</i>
Galaxiids	<i>Galaxiidae</i> all species
Mosquito fish	<i>Gambusia affinis</i>
Amphipods	<i>Gammarus pulex</i>
Three-spined stickleback	<i>Gasterosteus aculeatus</i>
Girella or rudderfish	<i>Girella punctata</i>
Luderick	<i>Girella tricuspidata</i>
Mouth almighty	<i>Glossamia aprion</i>
Flathead goby	<i>Glossogobius giuris</i>
Korean flounder	<i>Glyptocephalus stelleri</i>
Eurasian ruffe	<i>Gymnocephalus cernua</i>
Greenling	<i>Hexagrammos otakii</i>
American plaice	<i>Hippoglossoides platessoides</i>

Common name	Scientific name
Atlantic halibut	<i>Hippoglossus hippoglossus</i>
Pacific halibut	<i>Hippoglossus stenolepis</i>
Armoured weaselfish	<i>Hoplobrotula armata</i>
Great sandeel	<i>Hyperoplus lanceolatus</i>
Surf smelt	<i>Hypomesus pretiosus</i>
Silver carp	<i>Hypophthalmichthys molitrix</i>
Seven-band grouper	<i>Hyporthodus septemfasciatus</i>
Blue catfish	<i>Ictalurus furcatus</i>
Channel catfish	<i>Ictalurus punctatus</i>
Devil stinger	<i>Inimicus japonicus</i>
Nurseryfish	<i>Kurtus gulliveri</i>
Wrasses	<i>Labridae</i> all species
Wrasse	<i>Labrus bergylta</i>
Curviceps	<i>Laetacara curviceps</i>
River lamprey	<i>Lampetra fluviatilis</i>
Japanese seabass	<i>Lateolabrax japonicus</i>
Seabass	<i>Lateolabrax</i> spp.
Barramundi	<i>Lates calcarifer</i>
Striped trumpeter	<i>Latris lineata</i>
Spangled perch	<i>Leiopotherapon unicolor</i>
Pumpkinseed	<i>Lepomis gibbosus</i>
Bluegill	<i>Lepomis macrochirus</i>
Chinese emperor	<i>Lethrinus haematopterus</i>
Spangled emperor	<i>Lethrinus nebulosus</i>
Chub	<i>Leuciscus cephalus</i>
Ide or orfe	<i>Leuciscus idus</i>
Dace	<i>Leuciscus leuciscus</i>
Dab	<i>Limanda limanda</i>
Burbot	<i>Lota lota</i>
Mangrove jack	<i>Lutjanus argentimaculatus</i>
Crimson snapper	<i>Lutjanus erythropterus</i>
Common shiner	<i>Luxilus cornutus</i>
Eastern freshwater cod	<i>Maccullochella ikei</i>
Murray cod	<i>Maccullochella peelii</i>
Golden perch	<i>Macquaria ambigua</i>
Macquarie perch	<i>Macquaria australasica</i>
Australian bass	<i>Macquaria novemaculeata</i>
Paradise fish	<i>Macropodus opercularis</i>

Common name	Scientific name
Haddock	<i>Melanogrammus aeglefinus</i>
Rainbow fish	<i>Melanotaenia splendida</i>
Whiting	<i>Merlangius merlangus</i>
Pacific hake	<i>Merluccius productus</i>
Pacific tomcod	<i>Microgadus proximus</i>
Blue whiting	<i>Micromesistius poutassou</i>
Smallmouth bass	<i>Micropterus dolomieu</i>
Largemouth bass	<i>Micropterus salmoides</i>
Ram cichlid	<i>Mikrogeophagus ramirezi</i>
White perch	<i>Morone americana</i>
White bass	<i>Morone chrysops</i>
Yellow bass	<i>Morone mississippiensis</i>
Striped bass	<i>Morone saxatilis</i>
Silver redhorse	<i>Moxostoma anisurum</i>
Shorthead redhorse	<i>Moxostoma macrolepidotum</i>
Sea mullet	<i>Mugil cephalus</i>
Mulletts	<i>Mugilidae</i> , all species
Red mullet	<i>Mullus barbatus</i>
Southern pygmy perch	<i>Nannoperca australis</i>
Bony bream	<i>Nematalosa erebi</i>
Berney's catfish	<i>Neoarius berneyi</i>
Triangular shield catfish	<i>Neoarius leptaspis</i>
Round goby	<i>Neogobius melanostomus</i>
Black catfish	<i>Neosilurus ater</i>
Emerald shiner	<i>Notropis atherinoides</i>
Spottail shiner	<i>Notropis hudsonius</i>
Tadpole madtom	<i>Noturus gyrinus</i>
Japanese parrotfish	<i>Oplegnathus fasciatus</i>
Spotted knifejaw	<i>Oplegnathus punctatus</i>
Blue tilapia	<i>Oreochromis aureus</i>
Nile tilapia	<i>Oreochromis niloticus</i>
Tilapia hybrids	<i>Oreochromis niloticus</i> × <i>O. aureus</i>
Malaysian red hybrid tilapia	<i>Oreochromis niloticus</i> × <i>O. mossambicus</i>
Sleepy cod	<i>Oxyeleotris lineolata</i>
Marble goby	<i>Oxyeleotris marmorata</i>
Giant gudgeon	<i>Oxyeleotris selheimi</i>
Snapper	<i>Pagrus auratus</i>
Red sea bream	<i>Pagrus major</i>

Common name	Scientific name
Silver pomfret	<i>Pampus argenteus</i>
Striped catfish or tra	<i>Pangasianodon hypophthalmus</i>
Sutchi catfish	<i>Pangasius hypophthalmus</i>
Flounders	<i>Paralichthyidae</i>
Japanese flounder	<i>Paralichthys olivaceus</i>
Giant glassfish	<i>Parambassis gulliveri</i>
Chicken grunt	<i>Parapristipoma trilineatum</i>
English sole	<i>Parophrys vetulus</i>
Yellow catfish	<i>Pelteobagrus fulvidraco</i>
Rainbow krib	<i>Pelvicachromis pulcher</i>
Yellow perch	<i>Perca flavescens</i>
Redfin or European perch	<i>Perca fluviatilis</i>
Trout-perch	<i>Percopsis omiscomaycus</i>
Sea lamprey	<i>Petromyzon marinus</i>
Minnow	<i>Phoxinus phoxinus</i>
Bluntnose minnow	<i>Pimephales notatus</i>
Fathead minnow	<i>Pimephales promelas</i>
Orbiculate batfish	<i>Platax orbicularis</i>
Flounder	<i>Platichthys flesus</i>
Dusky flathead	<i>Platycephalus fuscus</i>
Bartail flathead	<i>Platycephalus indicus</i>
Ayu	<i>Plecoglossus altivelis</i>
Crescent sweetlips	<i>Plectorhinchus cinctus</i>
Sea bass	<i>Plectranthias yamakawai</i>
Spotted coral grouper	<i>Plectropomus maculatus</i>
Plaice	<i>Pleuronectes platessa</i>
Sailfin mollies	<i>Poecilia latipinna</i>
Guppy	<i>Poecilia reticulata</i>
Molly	<i>Poecilia sphenops</i>
Coalfish or pollock	<i>Pollachius virens</i>
Sand goby	<i>Pomatoschistus minutus</i>
Black crappie	<i>Pomoxis nigromaculatus</i>
Narrowstripe cardinalfish	<i>Pristiapogon exostigma</i>
Silver trevally	<i>Pseudocaranx dentex</i>
Iberian nase	<i>Pseudochondrostoma polylepis</i>
Winter flounder	<i>Pseudopleuronectes americanus</i>
Banggai cardinalfish	<i>Pterapogon kauderni</i>
Angelfish	<i>Pterophyllum scalare</i>

Common name	Scientific name
Rosy barb	<i>Puntius conchonius</i>
Cobia	<i>Rachycentron canadum</i>
Greenland halibut	<i>Reinhardtius hippoglossoides</i>
Pile perch	<i>Rhacochilus vacca</i>
Greenback flounder	<i>Rhombosolea tapirina</i>
Pike perch	<i>Sander lucioperca</i>
Pacific sardine	<i>Sardinops sagax</i>
Mango tilapia	<i>Sarotherodon galilaeus</i>
Rudd	<i>Scardinius erythrophthalmus</i>
Scat	<i>Scatophagus argus</i>
Red drum	<i>Sciaenops ocellatus</i>
Saratoga	<i>Scleropages jardini</i>
Chub mackerel	<i>Scomber japonicus</i>
Japanese spanish mackerel	<i>Scomberomorus niphonius</i>
Turbot	<i>Scophthalmus maximus</i>
Barcoo grunter	<i>Scortum barcoo</i>
Black rockfish	<i>Sebastes schlegelii</i>
Rockfish	<i>Sebastes spp.</i>
Amberjack	<i>Seriola dumerili</i>
Samson fish	<i>Seriola hippos</i>
Yellowtail kingfish	<i>Seriola lalandi</i>
Japanese yellowtail	<i>Seriola quinqueradiata</i>
Whiting	<i>Sillago ciliata</i>
Winter whiting	<i>Sillago maculata</i>
Chinese catfish	<i>Silurus asotus</i>
Wels catfish or sheatfish	<i>Silurus glanis</i>
Chinese perch or mandarin fish	<i>Siniperca chuatsi</i>
Senegalese sole	<i>Solea senegalensis</i>
Common sole	<i>Solea solea</i>
Gilt-head sea bream	<i>Sparus aurata</i>
European sprat	<i>Sprattus sprattus</i>
Thread-sail filefish	<i>Stephanolepis cirrhifer</i>
Long tom	<i>Strongylura krefftii</i>
Tiger puffer	<i>Takifugu rubripes</i>
Wet tropics tandan	<i>Tandanus tropicanus</i>
Eulachon	<i>Thaleichthys pacificus</i>
Northern bluefin tuna	<i>Thunnus thynnus</i>
Redbelly tilapia	<i>Tilapia zilli</i>

Common name	Scientific name
Tench	<i>Tinca tinca</i>
Archerfish	<i>Toxotes chatareus</i>
Banded archerfish	<i>Toxotes jaculatrix</i>
Primitive archer fish	<i>Toxotes lorentzi</i>
Snubnose dart	<i>Trachinotus blochii</i>
Permit	<i>Trachinotus falcatus</i>
Japanese horse mackerel	<i>Trachurus japonicus</i>
Hairtail	<i>Trichiurus lepturus</i>
Dwarf gourami	<i>Trichogaster lalius</i>
Pearl gourami	<i>Trichogaster leerii</i>
Silver gourami	<i>Trichogaster microlepis</i>
Three-spot gourami	<i>Trichogaster trichopterus</i>
Norway pout	<i>Trisopterus esmarkii</i>
Poor cod	<i>Trisopterus minutus</i>
Tvarnun simon	<i>Tristramella simonis</i>
Shi drum	<i>Umbrina cirrosa</i>
Barfin flounder	<i>Verasper moseri</i>
Spotted halibut	<i>Verasper variegatus</i>
Swordtail or green swordtail	<i>Xiphophorus helleri</i>
Southern platyfish or red wagtail platy	<i>Xiphophorus maculatus</i>
Viviparous blenny	<i>Zoarces viviparus</i>

Table A2 Common and scientific names of salmonid finfish

Common name	Scientific name
Cisco	<i>Coregonus artedi</i>
Lake whitefish	<i>Coregonus clupeaformis</i>
Whitefish (Muksun)	<i>Coregonus muksun</i>
Whitefish (Peled)	<i>Coregonus peled</i>
Whitefish	<i>Coregonus spp.</i>
Danube salmon	<i>Hucho hucho</i>
Golden trout	<i>Oncorhynchus aguabonita</i>
Cutthroat trout	<i>Oncorhynchus clarkii</i>
Gila trout	<i>Oncorhynchus gilae</i>
Pink salmon	<i>Oncorhynchus gorbuscha</i>
Chum salmon	<i>Oncorhynchus keta</i>
Coho salmon	<i>Oncorhynchus kisutch</i>
Masu salmon	<i>Oncorhynchus masou</i>
Rainbow trout	<i>Oncorhynchus mykiss</i>
Hybrid (rainbow trout × coho salmon)	<i>Oncorhynchus mykiss</i> × <i>O. kisutch</i>

Common name	Scientific name
Sockeye salmon	<i>Oncorhynchus nerka</i>
Amago salmon	<i>Oncorhynchus rhodurus</i>
Pacific salmon	<i>Oncorhynchus</i> spp.
Chinook salmon	<i>Oncorhynchus tshawytscha</i>
Coral trout	<i>Plectropomus leopardus</i>
Mountain whitefish	<i>Prosopium williamsoni</i>
Black sea salmon	<i>Salmo labrax</i>
Atlantic salmon	<i>Salmo salar</i>
Brown trout	<i>Salmo trutta</i>
Arctic char	<i>Salvelinus alpinus</i>
Bull trout	<i>Salvelinus confluentus</i>
Brook trout	<i>Salvelinus fontinalis</i>
Brook trout	<i>Salvelinus fontinalis</i>
Whitespotted char	<i>Salvelinus leucomaenis</i>
Lake trout	<i>Salvelinus namaycush</i>
Splake (lake trout × brook trout)	<i>Salvelinus namaycush</i> × <i>S. fontinalis</i>
Grayling	<i>Thymallus thymallus</i>

Molluscs

Table A3 Common and scientific names of molluscs

Common name	Scientific name
Sydney cockle or mud arc	<i>Anadara trapezia</i>
Calico scallop	<i>Argopecten gibbus</i>
New Zealand cockle	<i>Austrovenus stutchburyi</i>
Barnacles	<i>Balanus</i> spp.
New Zealand ark shell	<i>Barbatia novaezealandiae</i>
Common cockle	<i>Cerastoderma edule</i>
Striped venus clam	<i>Chamelea gallina</i>
Portuguese oyster	<i>Crassostrea angulata</i>
Suminoe oyster	<i>Crassostrea ariakensis</i>
Cortez oyster	<i>Crassostrea corteziensis</i>
Pacific oyster	<i>Crassostrea gigas</i>
Iwagaki oyster	<i>Crassostrea nippona</i>
Mangrove oyster	<i>Crassostrea rhizophorae</i>
Kumamoto oyster	<i>Crassostrea sikamea</i>
American eastern oyster	<i>Crassostrea virginica</i>
Hawaiian oyster	<i>Dendostrea sandvicensis</i>
Brownlip abalone	<i>Haliotis conicopora</i>
Pink abalone	<i>Haliotis corrugata</i>

Common name	Scientific name
Black abalone	<i>Haliotis cracherodii</i>
Whirling abalone	<i>Haliotis cyclobates</i>
Disc or Japanese abalone	<i>Haliotis discus hannai</i>
Diversicolor or jiukong abalone	<i>Haliotis diversicolor</i>
Small abalone	<i>Haliotis diversicolor supertexta</i>
Green abalone	<i>Haliotis fulgens</i>
New Zealand paua	<i>Haliotis iris</i>
Greenlip abalone	<i>Haliotis laevigata</i>
Blacklip abalone	<i>Haliotis rubra</i>
Tiger abalone	<i>Haliotis rubra</i> × <i>laevigata</i>
Red abalone	<i>Haliotis rufescens</i>
Staircase abalone	<i>Haliotis scalaris</i>
White abalone	<i>Haliotis sorenseni</i>
European abalone	<i>Haliotis tuberculata</i>
Flat abalone	<i>Haliotis wallalensis</i>
Sand cockle	<i>Katelysia rhytiphora</i>
Baltic macoma	<i>Macoma balthica</i>
Wedge shell	<i>Macomona liliana</i>
Soft shelled clam	<i>Mya arenaria</i>
Blue mussel	<i>Mytilus edulis</i>
Mediterranean mussel	<i>Mytilus galloprovincialis</i>
Southern mud oyster or Australian flat oyster	<i>Ostrea angasi</i>
New Zealand dredge oyster	<i>Ostrea chilensis</i>
Olympia oyster	<i>Ostrea conchaphila</i>
Asiatic oyster	<i>Ostrea denselammellosa</i>
European flat oyster	<i>Ostrea edulis</i>
Crested oyster	<i>Ostrea equestris</i>
Olympia oyster	<i>Ostrea lurida</i>
Argentinian flat oyster	<i>Ostrea puelchana</i>
Dwarf oyster	<i>Ostrea stentina</i>
New Zealand pipi	<i>Paphies australis</i>
Japanese scallop	<i>Patinopecten yessoensis</i>
Common European scallop	<i>Pecten maximus</i>
New Zealand scallop	<i>Pecten novaezelandiae</i>
Green-lipped mussel	<i>Perna canaliculus</i>
Japanese pearl oyster	<i>Pinctada fucata</i>
Blacklip pearl oyster	<i>Pinctada margaritifera</i>
Akoya pearl oyster	<i>Pinctada martensii</i>

Common name	Scientific name
Silverlip pearl oyster	<i>Pinctada maxima</i>
Pearl oyster	<i>Pinctada sugillata</i>
Venerid commercial clam	<i>Pitar prostrata</i>
Venus clam	<i>Protothaca jedoensis</i>
Mud whelk	<i>Batillaria</i> spp.
Mud whelk	<i>Pyrazus</i> spp.
Manila clam	<i>Ruditapes (Venerupis) philippinarum</i>
Grooved carpet shell or venerid clam	<i>Ruditapes decussatus</i>
Rock oyster	<i>Saccostrea cucullata</i>
Sydney rock oyster	<i>Saccostrea glomerata</i>
European razor clam	<i>Solen marginatus</i>
Hairy mussels	<i>Trichomya hirsuta</i>
Crocus clam	<i>Tridacna crocea</i>
Giant clam	<i>Tridacna gigas</i>
Elongated giant clam or rugose giant clam	<i>Tridacna maxima</i>
European aurora venus clam	<i>Venerupis aurea</i>
Pullet carpet shell	<i>Venerupis corrugata</i>
Asian littleneck clam	<i>Venerupis philippinarum</i>
Small brown mussel	<i>Xenostrobus securis</i>

Crustaceans

Table A4 Common and scientific names of crustaceans

Common name	Scientific name
Jelly prawns	<i>Acetes</i> spp.
Argentine stiletto shrimp	<i>Artemesia longinaris</i>
Brine shrimp	<i>Artemia salina</i>
Giant Tasmanian crayfish	<i>Astacopsis gouldi</i>
Giant crayfish	<i>Astacopsis</i> spp.
Noble crayfish	<i>Astacus astacus</i>
Turkish crayfish	<i>Astacus leptodactylus</i>
Crayfish	<i>Astacus</i> spp.
White-clawed crayfish	<i>Austropotamobius pallipes</i>
Stone crayfish	<i>Austropotamobius torrentium</i>
Cuata swimcrab	<i>Callinectes arcuatus</i>
Japanese crayfish	<i>Cambaroides japonicus</i>
European shore crab	<i>Carcinus maenas</i>
Acorn barnacle	<i>Chelonibia</i> spp.
Gooseneck barnacle	<i>Octolasmis</i> spp.
Yabbies (freshwater)	<i>Cherax destructor</i>

Common name	Scientific name
Redclaw crayfish	<i>Cherax quadricarinatus</i>
Freshwater crayfish	<i>Cherax</i> spp.
Parasitic copepods	<i>Ergasilus manicatus</i>
Chinese mitten crab	<i>Eriocheir sinensis</i>
Gippsland spiny crayfish	<i>Euastacus kershawi</i>
Spiny crayfish	<i>Euastacus</i> spp.
Oriental prawn	<i>Exopalaemon carinicauda</i>
Smooth crayfish	<i>Geocherax</i> spp.
Brush clawed shore crab	<i>Hemigrapsus penicillatus</i>
American lobster	<i>Homarus americanus</i>
Asian freshwater shrimp	<i>Macrobrachium dayanum</i>
Freshwater prawn	<i>Macrobrachium lanchesteri</i>
Oriental freshwater shrimp	<i>Macrobrachium nipponense</i>
Giant freshwater prawn	<i>Macrobrachium rosenbergii</i>
Sunda river prawn	<i>Macrobrachium sintangene</i>
Superb freshwater shrimp	<i>Macrobrachium superbum</i>
Greentail prawn	<i>Metapenaeus bennettiae</i>
Red endeavour (greasyback) prawn	<i>Metapenaeus ensis</i>
Crayfish	<i>Orconectes</i> spp.
Signal crayfish	<i>Pacifastacus leniusculus</i>
Mississippi grass shrimp	<i>Palaemon kadiakensis</i>
Daggerblade grass shrimp	<i>Palaemon pugio</i>
Barred estuarine shrimp	<i>Palaemon serrifer</i>
Mysid shrimp	<i>Palaemon styliferus</i>
Mississippi grass shrimp	<i>Palaemonetes kadiakensis</i>
Daggerblade grass shrimp	<i>Palaemon pugio</i>
Tropical spiny lobster	<i>Panulirus</i> spp.
Planktonic copepods	<i>Paracartia grani</i>
Northern brown shrimp	<i>Penaeus (Farfantepenaeus) aztecus</i>
Yellow-leg shrimp	<i>Penaeus (Farfantepenaeus) californiensis</i>
Northern pink shrimp	<i>Penaeus (Farfantepenaeus) duorarum</i>
Southern brown shrimp	<i>Penaeus (Farfantepenaeus) subtilis</i>
Chinese white shrimp	<i>Penaeus (Fenneropenaeus) chinensis</i>
Indian banana prawn	<i>Penaeus (Fenneropenaeus) indicus</i>
Gulf banana prawn	<i>Penaeus (Fenneropenaeus) merguensis</i>
Western white shrimp	<i>Penaeus (Litopenaeus) occidentalis</i>
Northern white shrimp	<i>Penaeus (Litopenaeus) setiferus</i>
Pacific blue shrimp	<i>Penaeus (Litopenaeus) stylirostris</i>

Common name	Scientific name
Pacific white shrimp	<i>Penaeus (Litopenaeus) vannamei</i>
Kuruma prawn	<i>Penaeus (Marsupenaeus) japonicus</i>
Brown tiger prawn	<i>Penaeus esculentus</i>
Aloha prawn	<i>Penaeus marginatus</i>
Black tiger prawn	<i>Penaeus monodon</i>
Green tiger prawn or grooved tiger prawn	<i>Penaeus semisulcatus</i>
Sand crab	<i>Portunus pelagicus</i>
Three spot swimming crab	<i>Portunus sanguinolentus</i>
European river crab	<i>Potamon potamios</i>
Louisiana swamp crayfish	<i>Procambarus clarkii</i>
Marbled crayfish	<i>Procambarus fallax. f. virginalis</i>
Mud crab	<i>Scylla serrata</i>
Red crab	<i>Sesarma mederi</i>
Mangrove swimming crab	<i>Thalamita crenata</i>
Fiddler crab	<i>Uca vocans</i>

Amphibians

Table A5 Common and scientific names of amphibians

Common name	Scientific name
Cane toad	<i>Bufo marinus</i>
Ornate nursery frog	<i>Cophixalus ornatus</i>
Striped burrowing frog	<i>Cyclorana alboguttata</i>
Short-footed frog	<i>Cyclorana brevipes</i>
Blue tailed fire belly newt	<i>Cynops cyanurus</i>
Sword tailed newt	<i>Cynops ensicauda</i>
Chinese firebelly newt	<i>Cynops orientalis</i>
Japanese fire belly newt	<i>Cynops pyrrhogaster</i>
Sardinian brook salamander	<i>Euproctus platycephalus</i>
French cave salamander	<i>Hydromantes strinatii</i>
Clouded salamander	<i>Hynobius nebulosus</i>
Alpine newt	<i>Ichthyosaura alpestris</i>
Ornate burrowing frog	<i>Limnodynastes ornatus</i>
Italian newt	<i>Lissotriton italicus</i>
Smooth newt	<i>Lissotriton vulgaris</i>
Green tree frog	<i>Litoria caerulea</i>
Bumpy rocket frog	<i>Litoria inermis</i>
Red tree frog	<i>Litoria rubella</i>
Magnificent tree frog	<i>Litoria splendida</i>
Great barred frog	<i>Mixophyes fasciolatus</i>

Common name	Scientific name
Yellow spotted newt	<i>Neurergus crocatus</i>
Eastern newt	<i>Notophthalmus viridescens</i>
Japanese clawed salamander	<i>Onychodactylus japonicas</i>
Vietnamese salamander	<i>Paramesotriton deloustali</i>
Ornate burrowing frog	<i>Platyplectrum ornatus</i>
Spanish ribbed newt	<i>Pleurodeles waltl</i>
Red-backed toadlet	<i>Pseudophryne coriacea</i>
Cane toad	<i>Rhinella marina</i>
North African fire salamander	<i>Salamandra algira</i>
Fire salamander	<i>Salamandra salamandra</i>
Siberian salamander	<i>Salamandrella keyserlingii</i>
Northern spectacled salamander	<i>Salamandrina perspicillata</i>
Lesser siren	<i>Siren intermedia</i>
European cave salamanders	<i>Speleomantes</i> spp.
Rough skinned newt	<i>Taricha granulosa</i>
Sharp-snouted day frog	<i>Taudactylus acutirostris</i>
Northern crested newt	<i>Triturus cristatus</i>
Chiang Mai crocodile newt	<i>Tylototriton uyenoii</i>
Vietnamese crocodile newt	<i>Tylototriton vietnamensis</i>
Wenxian knobby newt	<i>Tylototriton wenxianensis</i>
Zeigler's crocodile newt	<i>Tylototriton zieglerei</i>

Other

Table A6 Common and scientific names of other species in this field guide

Common name	Scientific name
Grey heron	<i>Ardea cinerea</i>
Fish louse	<i>Argulus foliaceus</i>
Salmon louse	<i>Caligus coryphaenae</i>
Salmon louse	<i>Caligus elongatus</i>
Mayfly	<i>Callibaetis</i> spp.
Salmon louse	<i>Lepeophtheirus salmonis</i>
Polychaete	<i>Nephtys australiensis</i>
Polychaetes	<i>Nereis</i> spp.
Leeches	<i>Piscicola</i> spp.
Common roach	<i>Rutilus rutilus</i>
Gill lice	<i>Salmincola</i> spp.
Tubifex worms	<i>Tubifex tubifex</i>

Appendix B: Reporting suspected disease

If you see any unusual symptoms in wild or farmed aquatic animals, play it safe and **report it immediately**. Don't worry about how insignificant it may be—small signs may be an early indication of a serious disease problem.

**National 24 hour emergency animal disease watch hotline:
1800 675 888 (freecall)**

Each state or territory can also be contacted if you suspect a disease. Table 78 shows the state and territory government agencies responsible for aquatic health, and provides points of contact.

Table 78 State and territory government contact details for reporting aquatic animal disease

State or territory	Government agency	Internet site	State telephone
Australian Capital Territory	Environment Planning and Sustainable Development Directorate	www.environment.act.gov.au	132 281
New South Wales	Department of Primary Industries	www.dpi.nsw.gov.au	1800 043 536 (fishwatch)
Northern Territory	Department of Environment and Natural Resources	nt.gov.au	1800 891 136 (fishwatch) 0413 381 094
Queensland	Department of Agriculture and Fisheries	www.daf.qld.gov.au	13 25 23 or 07 3404 6999
South Australia	Department of Primary Industries and Regions SA	www.pir.sa.gov.au	1800 065 522 (fishwatch 24 hours)
Tasmania	Department of Primary Industries, Parks, Water and Environment	www.dpipwe.tas.gov.au	1300 368 550
Victoria	Department of Jobs, Precincts and Regions	agriculture.vic.gov.au	136 186
Western Australia	Department of Primary Industries and Regional Development	www.fish.wa.gov.au	1800 815 507 (fishwatch)

Appendix C: Further reading

These hyperlinks were correct at the time of publication.

General

CABI [Invasive Species Compendium](#) (search by disease)

CEFAS [International Database on Aquatic Animal Diseases](#)

Department of Agriculture [AQUAVETPLAN disease strategy manuals](#)

World Organisation for Animal Health [Manual of diagnostic tests for aquatic animals](#)

Finfish

Biosecurity Australia 2014, *Importation of freshwater ornamental fish: review of biosecurity risks associated with gourami iridovirus and related viruses—provisional final import risk analysis report*

Camus, AC 2004, *Channel catfish virus disease*, Southern Regional Aquaculture Centre

Elwell LC, Stromberg KE, Ryce EK, Bartholomew JL 2009, 'Whirling disease in the United States: a summary of progress and research and management 2009', *Trout Unlimited*

Fu X, Li N, Liu L, Lin Q, Wang F, Lai Y, Jiang H, Pan H, Shi C, Wu S 2011, 'Genotype and host range analysis of infectious spleen and kidney necrosis virus (ISKNV)', *Virus Gene*

Glenn RA, Taylor PW, Pelton EH, Gutenberger SK, Ahrens MA, Marchant LM, Hanson KC 2015, [Genetic evidence of vertical transmission and cycling of 'Yersinia ruckeri' in hatchery-origin fall chinook salmon 'Oncorhynchus tshawytscha'](#), *Journal of Fish and Wildlife Management*.

Hazeri M, Hassan MD, Abba Y, Omar AR, Allaudin ZN, Soltani M, Hamdan RH, Mohamad NF 2017, [Molecular characterisation of grouper iridovirus isolates from Peninsular Malaysia](#), *Journal Veterinar Malaysia*

Jansen MD and Mohan CV 2017, *Tilapia lake virus (TiLV): Literature review*, Penang, Malaysia: CGIAR Research Program on Fish Agri-Food Systems

Kumar G, Menanteau-Ledouble S, Saleh M, El-Matbouli M 2015, ['Yersinia ruckeri', the causative agent of enteric red mouth disease in fish](#), *Veterinary Research*.

Ma H, Peng C, Su Y, Feng J, Guo Z 2016, 'Isolation of a Ranavirus-type grouper iridovirus in mainland China and comparison of its pathogenicity with that of a Megalocytivirus-type grouper iridovirus', *Aquaculture*

Menanteau-Ledouble S, Kumar G, Saleh M, El-Matbouli M 2016, ['Aeromonas salmonicida': updates on an old acquaintance](#), *Diseases of Aquatic Organisms*

Network of Aquaculture Centres in Asia–Pacific [Epizootic ulcerative syndrome: disease card](#)

Network of Aquaculture Centres in Asia–Pacific [Grouper iridoviral disease: disease card](#)

Network of Aquaculture Centres in Asia-Pacific [Tilapia Lake Virus \(TiLV\)—A novel orthomyxo-like virus: disease card](#)

Whittington RJ, Djordjevic SP, Carson J, Callinan RB 1995, [Restriction endonuclease analysis of atypical 'Aeromonas salmonicida' isolates from goldfish 'Carassius auratus', silver perch 'Bidyanus](#)

[bidyanus', and greenback flounder 'Rhombosolea tapirina' in Australia](#), *Diseases of Aquatic Organisms*

Molluscs

Australia and New Zealand standard diagnostic procedure [Bonamiosis in Australian 'Ostrea angasi'](#)

European Union Reference Laboratory for Molluscs Diseases ['Martellioides chungmuensis'](#)

European Union Reference Laboratory for Molluscs Diseases ['Mikrocytos mackini'](#)

Fisheries and Oceans Canada ['Martellioides chungmuensis' of oysters](#)

Fisheries and Oceans Canada [Gill disease of Portuguese oyster](#)

Fisheries and Oceans Canada [Oyster velar virus disease](#)

Crustaceans

Network of Aquaculture Centres in Asia-Pacific ['Monodon' slow growth syndrome and Laem-Singh virus retinopathy: disease card](#)

Network of Aquaculture Centres in Asia-Pacific [Acute hepatopancreatic necrosis: disease card](#)

Network of Aquaculture Centres in Asia-Pacific [Hepatopancreatic microsporidiosis caused by infection with 'Enterocytooon hepatopenaei': disease card](#)

Poornima, M, Seetang-Nun, Y, Alavandi, SV & Dayal, J 2012, [Laem-Singh virus: A probable etiological agent associated with Monodon slow growth syndrome in farmed black tiger shrimp \('Penaeus monodon'\)](#), *Indian Journal of Virology*, vol. 23.

Amphibians

Department of the Environment and Energy [Infection of amphibians with chytrid fungus resulting in chytridiomycosis \(2016\)](#)

European Food Safety Authority [Scientific and technical assistance concerning the survival, establishment and spread of 'Batrachochytrium salamandrivorans' \(Bsal\) in the EU](#)

Imperial College London [Global Bd mapping project](#)

Wildlife Health Australia [Ranaviral disease in wild Australian amphibians](#)

World Organisation for Animal Health, ['Batrachochytrium salamandrivorans' disease card](#)