

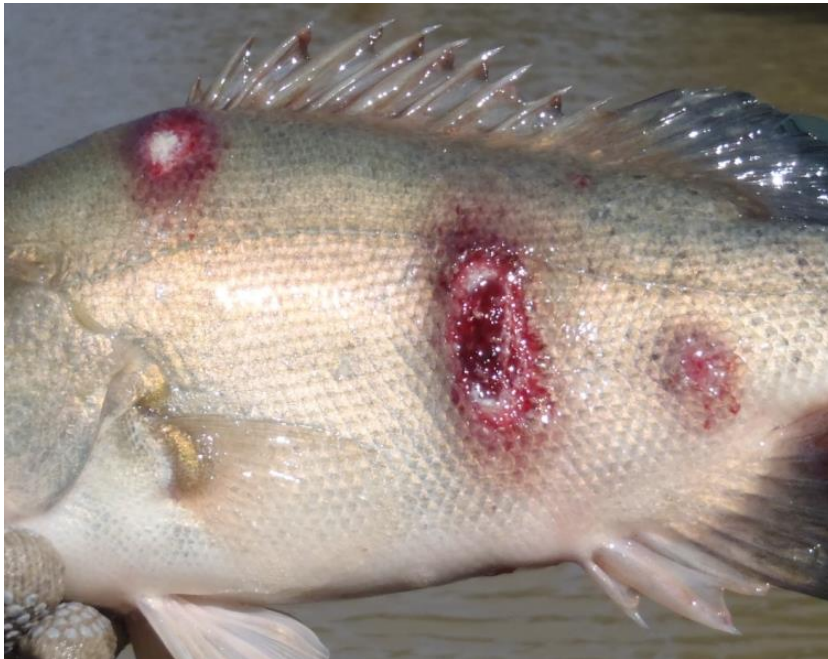

Infection with *Aphanomyces invadans*

Also known as epizootic ulcerative syndrome (EUS), red spot disease (RSD),
ulcerative mycosis (UM) and mycotic granulomatosis


From *Aquatic animal diseases significant to Australia: identification field guide*, 5th edition

Figure 1 EUS in golden perch (*Macquaria ambigua*)



Note: Multiple ulcerative lesions on flanks caused by infection with *Aphanomyces invadans*.
Source: C Boys

Figure 2 EUS in spangled perch (*Leiopotherapon unicolour*)



Note Focal haemorrhagic ulcerative lesions (a) will progress to a deep ulcer (b).
Source: C Boys

Figure 3 EUS in sand whiting (*Sillago ciliata*)



Note: Progression of red lesion (top) to deep ulcer (bottom) of classical red sores on the body.
Source: NSW Department of Primary Industries

Signs of disease

Important: Animals with this disease may show one or more of these signs, but the pathogen may still be present in the absence of any signs.

Disease signs at the farm, tank or pond level are:

- loss of appetite
- dark body colour
- mass mortality
- erratic swimming
- rubbing on the surfaces of tanks
- increased respiratory rate and effort.

Gross pathological signs are:

- lesions on the body showing as red spots, black burn-like marks or deeper ulcers with red centres and white rims
- progressive lesions
 - lesions start as reddening under a single scale but quickly spread to involve adjacent scales
 - lesions continue to widen and deepen, forming ulcers that erode underlying tissues to expose (depending on infection location) skeletal musculature, vertebrae, brain or viscera.
- unilateral or bilateral clouding of the eye (particularly in barramundi).

Microscopic pathological signs are:

- erythematous dermatitis
- hyphae (fungal threads) associated with granulomatous tissue, sometimes extending into visceral organs
- liquefactive necrosis of muscle tissue.

Disease agent

Infection with the oomycete fungus *Aphanomyces invadans* causes a disease called epizootic ulcerative syndrome (EUS); also known as red spot disease (RSD), ulcerative mycosis (UM) or mycotic granulomatosis. Although previously regarded as a fungus, the genus *Aphanomyces* is now classified with diatoms and brown algae in a group called Stramenopiles or Chromista.

Host range

More than 100 estuarine and freshwater species of fish are known to be susceptible to infection with *A. invadans*.

Table 1 Species in Australia known to be susceptible to *Aphanomyces invadans*

Common name	Scientific name
Australian bass ^a	<i>Macquaria novemaculeata</i>
Archerfish ^a	<i>Toxotes chatareus</i>
Banded archerfish ^a	<i>Toxotes jaculatrix</i>
Barcoo grunter ^a	<i>Scortum barcoo</i>
Barramundi ^a	<i>Lates calcarifer</i>
Bony bream ^a	<i>Nematalosa erebi</i>
Chanda perch ^a	<i>Ambassis agassizii</i>
Cichlids ^a	<i>Cichlidae</i>
Climbing perch ^a	<i>Anabas testudineus</i>
Cyprinids ^a	<i>Cyprinidae</i>
Dusky flathead ^a	<i>Platycephalus fuscus</i>
Eastern freshwater cod	<i>Maccullochella ikei</i>
Eels	<i>Anguillidae</i> all species
Estuarine rockcod ^a	<i>Epinephelus tauvina</i>
Flathead goby ^a	<i>Glossogobius giuris</i>
Fork-tailed catfish	<i>Arius</i> spp.
Froggatt's catfish	<i>Cinetodus froggatti</i>
Giant glassfish ^a	<i>Parambassis gulliveri</i>
Giant grouper	<i>Epinephelus lanceolatus</i>
Giant gudgeon ^a	<i>Oxyeotris selheimi</i>
Goldfish	<i>Carassius auratus auratus</i>
Golden perch	<i>Macquaria ambigua</i>
Grouper and estuary cod ^a	<i>Epinephelus</i> spp.

Infection with *Aphanomyces invadans*

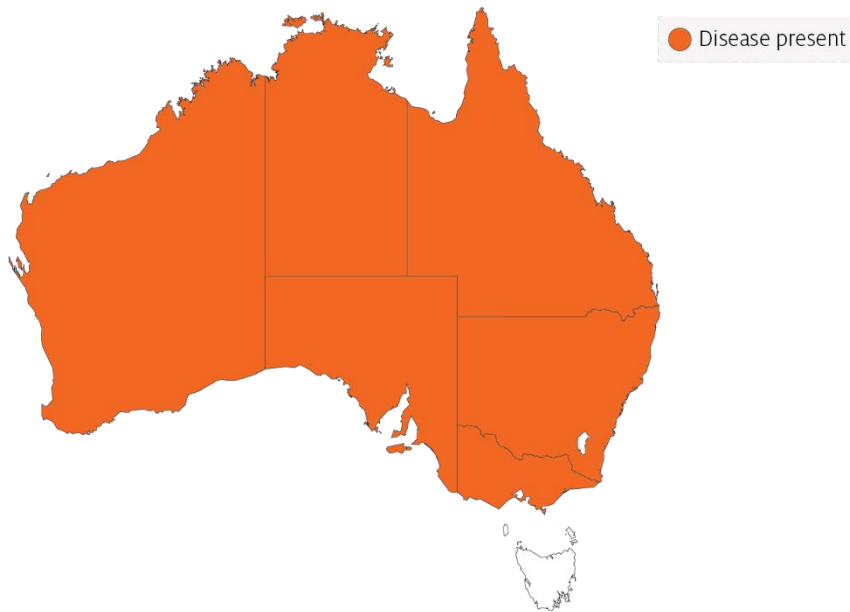Common name	Scientific name
Long tom ^a	<i>Strongylura krefftii</i>
Mangrove jack ^a	<i>Lutjanus argentimaculatus</i>
Mouth almighty ^a	<i>Glossamia aprion</i>
Sea mullet ^a	<i>Mugil cephalus</i>
Mulletts ^a	<i>Mugilidae</i>
Murray cod	<i>Maccullochella peelii</i>
Nurseryfish	<i>Kurtus gulliveri</i>
Primitive archer fish ^a	<i>Toxotes lorentzi</i>
Rainbow fish ^a	<i>Melanotaenia splendida</i>
Rainbow trout	<i>Oncorhynchus mykiss</i>
Saratoga ^a	<i>Scleropages jardini</i>
Scat ^a	<i>Scatophagus argus</i>
Shortfin eel ^a	<i>Anguilla australis</i>
Silver perch ^a	<i>Bidyanus bidyanus</i>
Silver trevally ^a	<i>Pseudocaranx dentex</i>
Sleepy cod ^a	<i>Oxyeleotris lineolatus</i>
Striped grunter ^a	<i>Amniataba percoides</i>
Spangled perch ^a	<i>Leiopotherapon unicolor</i>
Triangular shield catfish ^a	<i>Neoarius leptaspis</i>
Tropical two-winged flying fish ^a	<i>Exocoetus volitans</i>
Whiting ^a	<i>Sillago ciliata</i>
Yellowfin bream ^a	<i>Acanthopagrus australis</i>

a Naturally susceptible. Note: Other species have been shown to be experimentally susceptible. A current list of known susceptible species found both within and outside of Australia is included in the World Organisation for Animal Health [Manual of Diagnostic Tests for Aquatic Animals](#).

Presence in Australia

EUS is endemic in many freshwater catchments and estuaries in Australia. The disease has been officially reported from New South Wales, the Northern Territory, Queensland, Victoria, South Australia and Western Australia.

Map 1 Presence of *Aphanomyces invadans*, by jurisdiction



Epidemiology

- The disease is seen in more than 100 freshwater and estuarine species of fish and infection has spread rapidly throughout Asia, associated with the movement of ornamental fish.
- Predisposing factors leading to skin damage (such as parasites, bacterial or viral infection, physical trauma or acidic water) are normally required to allow the *Aphanomyces* oomycete to initiate clinical signs of EUS. Secondary opportunistic infections are also a common finding.
- Disease is often associated with acid water run-off and can appear after heavy rains (particularly after a long dry period) with water temperatures of 18°C to 22°C favouring sporulation.
- Disease transmission is through zoospore transfer in freshwater, direct contact between fish and skin contamination (penetration assisted by damage to skin).
- Zoospores can encyst if they do not find a host, and can survive for at least 19 days.
- Water salinity above 2 ppt can stop the spread of this obligate freshwater disease agent.

Differential diagnosis

The list of [similar diseases](#) in the next section refers only to the diseases covered by this field guide. Gross pathological signs may also be representative of diseases not included in this guide. Do not rely on gross signs to provide a definitive diagnosis. Use them as a tool to help identify the listed diseases that most closely account for the observed signs.

Similar diseases

Enteric septicaemia of catfish, grouper iridoviral disease, infection with *Aeromonas salmonicida*—atypical strains, koi herpesvirus disease (KHV), viral haemorrhagic septicaemia (VHS) and tilapia lake virus (TiLV) disease.

Sample collection

Only trained personnel should collect samples. Using only gross pathological signs to differentiate between diseases is not reliable, and some aquatic animal disease agents pose a risk to humans. If you are not appropriately trained, phone your state or territory hotline number and report your observations. If you have to collect samples, the agency taking your call will advise you on the appropriate course of action. Local or district fisheries or veterinary authorities may also advise on sampling.

Emergency disease hotline

See something you think is this disease? Report it. Even if you're not sure.

Call the Emergency Animal Disease Watch Hotline on **1800 675 888**. They will refer you to the right state or territory agency.

Further reading

CABI Invasive species compendium [Epizootic ulcerative syndrome](#)

Network of Aquaculture Centres in Asia–Pacific [Epizootic ulcerative syndrome: disease card](#)

World Organisation for Animal Health [Manual of diagnostic tests for aquatic animals](#)

These hyperlinks were correct at the time of publication.

Contact details

Emergency Animal Disease Watch Hotline 1800 675 888

Email AAH@agriculture.gov.au

Website agriculture.gov.au/pests-diseases-weeds/aquatic

© Commonwealth of Australia 2020

This work is copyright. It may be reproduced in whole or in part subject to the inclusion of an acknowledgement of the source and no commercial usage or sale.